



Shiraz University



**IJVR**

ISSN: 1728-1997 (Print)  
ISSN: 2252-0589 (Online)

**Vol. 24**

**No. 4**

**Ser. No. 85**

**2023**

# **IRANIAN JOURNAL OF VETERINARY RESEARCH**



## Short Paper

# Isolation and molecular characterization of infectious bursal disease virus circulating in western and central India

Agnihotri, A. A.<sup>1</sup>; Awandkar, S. P.<sup>2\*</sup>; Kulkarni, R. C.<sup>3</sup>; Chavhan, S. G.<sup>4</sup>; Suryawanshi, R. D.<sup>5</sup>; Mohan, A.<sup>6</sup>; Kulkarni, M. B.<sup>2</sup> and Chavan, V. G.<sup>1</sup>

<sup>1</sup>Post-graduate Student in Veterinary Microbiology, Department of Veterinary Microbiology, College of Veterinary & Animal Sciences, Maharashtra Animal & Fishery Sciences University, Udgir 423517, India; <sup>2</sup>Department of Veterinary Microbiology, College of Veterinary & Animal Sciences, Maharashtra Animal & Fishery Sciences University, Udgir 423517, India; <sup>3</sup>Department of Poultry Science, College of Veterinary & Animal Sciences, Maharashtra Animal & Fishery Sciences University, Udgir 423517, India; <sup>4</sup>Department of Veterinary Pathology, College of Veterinary & Animal Sciences, Maharashtra Animal & Fishery Sciences University, Udgir 423517, India; <sup>5</sup>Department of Veterinary Public Health, College of Veterinary & Animal Sciences, Maharashtra Animal & Fishery Sciences University, Udgir 423517, India; <sup>6</sup>Department of Veterinary Medicine, College of Veterinary & Animal Sciences, Maharashtra Animal & Fishery Sciences University, Udgir 423517, India

\*Correspondence: S. P. Awandkar, Department of Veterinary Microbiology, College of Veterinary & Animal Sciences, Maharashtra Animal & Fishery Sciences University, Udgir 423517, India. E-mail: drspawandkar@gmail.com



10.22099/IJVR.2023.47037.6774

(Received 25 Mar 2023; revised version 4 Oct 2023; accepted 18 Oct 2023)

This is an open access article under the CC BY-NC-ND license (<http://creativecommons.org/licenses/by-nc-nd/4.0/>)

## Abstract

**Background:** Infectious bursal disease (IBD) caused substantial economic loss in central and western India during 2020 and 2021. **Aims:** The study was conducted to characterize IBD virus (IBDV) from field outbreaks. **Methods:** The study was conducted on 360 samples from 42 poultry flocks. The samples were subjected to histopathology and molecular detection, followed by phylogenetic typing of the partial VP2 gene. **Results:** The mortality ranged from 15.25 to 60.18%. The necropsy showed hemorrhages on thigh muscles, mottled spleen, swelling of kidneys and bursae with hemorrhages, and cheesy exudate. Histopathology revealed extensive necrosis and depletion of follicular lymphoid cells within the cortex and medulla, along with widespread hemorrhages, edema, and cystic cavities in the bursa. The field isolates showed cytopathic effects in the seventh passage. The cytopathic effects included swelling, rounding, granulation of cytoplasm around the nucleus, fragmentation of the infected cells, and detachment. The reverse transcription-polymerase chain reaction amplified 664 bp partial VP2 gene. The phylogenetic analysis identified 19 field isolates as very virulent IBDVs (vvIBDVs) and three as classical strains. **Conclusion:** The results indicated that different vvIBDV strains are involved in disease outbreaks in central and western India.

**Key words:** IBDV, India, Isolation, Phylogeny

## Introduction

Poultry rearing supports the livelihood of small and marginal farmers in rural India. The farmers and landless laborers keep native poultry in their backyard and utilize it either as a source of protein-rich food or to generate immediate income as and when required. Poultry production in India has advanced in the last forty years, evolving from an intuitive farming system to a commercial production system with recent technological interventions (Economic Survey, GOI, 2021). In 2022, India ranked 3rd in egg production and 6th in poultry meat production (APEDA, 2022). However, along with increased production, infectious diseases threaten the poultry industry and lead to reduced weight gain, reduced egg production, mortality, and heavy economic losses. Infectious bursal disease (IBD) is a crucial immunosuppressive (Camilotti *et al.*, 2016) and

economically significant disease for poultry farmers due to increased susceptibility to other diseases and hostile intrusion with vaccination (Yamaguchi, 1997).

In recent years, very virulent strains of infectious bursal disease virus (vvIBDV) emerged and have been endemic in many poultry flocks worldwide (Pitesky *et al.*, 2013; Dey *et al.*, 2019). The outbreaks of IBDV have occurred in Europe, Africa, Japan, China, and Southeast Asia (Dey *et al.*, 2019). The disease was controlled effectively until recently by vaccination of the young birds. However, vvIBDVs were able to break through the maternal and active immunity induced mainly by classical or mild IBDV vaccine strains (van den Berg *et al.*, 2000). The outbreaks of IBD are observed regularly in the vaccinated poultry flocks of the subcontinent (Mor *et al.*, 2010; Raja *et al.*, 2016; Awandkar *et al.*, 2018; Shinde *et al.*, 2021). The new IBDV strains emerged by mutation(s) in the major and minor hypervariable region

of the VP2 protein or reassortment and recombination with field circulating viruses (Raja *et al.*, 2016).

Small and marginal farmers in India contribute a considerable share of poultry production. The emergence of newer strains of vvIBDV poses a serious threat to poultry production. The present study was conducted to characterize IBDV circulating in the vaccinated and unvaccinated poultry flocks of central and western India during recent outbreaks.

## Materials and Methods

### Necropsy and sample collection

A total of 42 poultry flocks in central and western India were visited, and the flocks experiencing IBD outbreaks were recruited in the study during 2020-2021. The mortality was subjected to necropsy examination. The symptoms and gross lesions were recorded. The samples (n=360, bursa of Fabricius, skeletal muscles, kidneys, and spleen) were collected in 10% formal saline for histopathology using the standard technique. Similarly, the bursa of Fabricius was collected aseptically in a virus transport medium. The samples were transported to the laboratory on ice and stored at -20°C until further use.

### Sample processing

The bursal samples were homogenized into 10% suspension using phosphate buffer saline (pH 7.2), freeze-thawed thrice, and ultrasonicated. These suspensions were clarified at 2000 g for 15 min in a refrigerated centrifuge (Thermo, USA), followed by filtration through 0.22 µm membrane filters and stored at -80°C for virus isolation and identification.

Formal saline fixed tissue samples were processed for sectioning and stained using the Haematoxylin and Eosin staining method as per the standard protocol described by Spencer and Bancroft (2013).

### Virus isolation

The samples were subjected to virus isolation using primary chicken embryo fibroblast (CEF) cells. CEF cells were prepared following a standard procedure (Freshney, 2016).

Confluent monolayers (80-85%) were infected with 10% bursal suspension for 1 h at 37°C. The cultures were incubated in a CO<sub>2</sub> incubator (Thermo, USA) at 37°C at a 5% CO<sub>2</sub> concentration and checked twice daily for cytopathic effects (CPE). Positive (vaccine virus) and negative controls were also considered.

### Virus identification by RT-PCR, and sequencing

The total RNA extracted from the bursal homogenates and cell culture supernatants were denatured in 0.5 µL DTT (0.1 M) at 90°C followed by a snap chill in ice, and was subjected to one-step RT-PCR using SuperScript™ III One-Step RT-PCR kit (Invitrogen, USA) as per the manufacturer's instructions. The primers F-5'ACT GTC CTC AGC TTA CCC ACA T3' and R-5'TCT GTG ACC AGG TTC TTT GCT A3'

were used to amplify the partial VP2 gene (Awanekar *et al.*, 2018). The RT-PCR was carried out in a thermocycler (Eppendorf, Germany) at the annealing temperature of 49°C for 1 min.

The PCR amplicons were electrophoresed in 1% agarose gel and visualized in gel documentation (Biorad, USA). The specific amplicons were sequenced following sequencing in a 3730xl DNA Analyzer (Barcode Biosciences, India).

### Sequence and phylogenetic analysis

The trimmed nucleotide sequences were subjected to BLAST analysis (<http://blast.ncbi.nlm.nih.gov>). The sequences were matched with the homologous IBDV sequences found on BLASTn and were deposited in GenBank with accession No. OK491838 to OK491859. The sequences were aligned with the representative homologous nucleotide sequences retrieved from GenBank (Table 1) in Clustal W. The phylogenetic

**Table 1:** Details of the IBDV isolates and global strains used for phylogenetic analysis

SN	Accession No.	Strain	Origin	Year
1	OK491838	IBDV/MH-LN-Broiler1	India	2020
2	OK491839	IBDV/MH-LN-Broiler2	India	2020
3	OK491840	IBDV/MH-ML-Broiler1	India	2021
4	OK491841	IBDV/MH-ML-Broiler2	India	2021
5	OK491842	IBDV/MP-BL-Broiler1	India	2021
6	OK491843	IBDV/MP-BL-Broiler2	India	2021
7	OK491844	IBDV/MH-KH-SPuda1	India	2020
8	OK491845	IBDV/MH-KH-SPuda2	India	2020
9	OK491846	IBDV/MH-PS-Broiler1	India	2020
10	OK491847	IBDV/MH-PS-Broiler2	India	2020
11	OK491848	IBDV/MH-NR-Broiler1	India	2020
12	OK491849	IBDV/MH-NR-Broiler2	India	2020
13	OK491850	IBDV/MH-TM-KNath1	India	2020
14	OK491851	IBDV/MH-TM-KNath2	India	2020
15	OK491852	IBDV/MH-MK-Kaveri1	India	2020
16	OK491853	IBDV/MH-MK-Kaveri2	India	2020
17	OK491854	IBDV/MH-DN-Desi1	India	2020
18	OK491855	IBDV/MH-DN-Desi2	India	2020
19	OK491856	IBDV/MH-NL-IMST1	India	2021
20	OK491857	IBDV/MH-HL-IVST1	India	2021
21	OK491858	IBDV/MH-OM-IMS1	India	2021
22	OK491859	IBDV/MH-AM-IMP1	India	2021
23	MK501731	PS-Ngp	India	2014
24	MK172062	PS-Ngp	India	2013
25	KX223749	PY12	India	2012
26	KJ547672	EZ	India	2013
27	KJ621065	FS16	India	2013
28	KJ547673	WZ	India	2013
29	KJ547674	NZ	India	2014
30	AY704912	--	Iran	2004
31	AY870343	--	Iran	2004
32	DQ785173	JRMP30IR	Iran	2005
33	DQ785172	JRMP25IR	Iran	2005
34	DQ899754	JRMP42IR	Iran	2006
35	EU082025	IR299	Iran	2007
36	EU082024	IR199	Iran	2007
37	LN849069	D2249/1/1/14	Iran	2013
38	LN849070	D2249/2/1/1	Iran	2015
39	KX017537	IR/H1548.2/16	Iran	2015
40	OP727262	N6-VP2F-F_C07_03	Iran	2022
41	LM651365	SH99	China	2014
42	MZ066613	QZ191002	China	2019
43	MZ066614	YL160304	China	2016
44	MW452665	PAK-SFW-2020	Pakistan	2020
45	OL690421	PAK-SFW2-2020	Pakistan	2020
46	OQ534291	PAK-3-2023	Pakistan	2023
47	MH644846	DD1	Russia	2016
48	MT505343	UPM1432	Malaysia	2019
49	AF247006	UPM97/61	Malaysia	2020
50	KJ198844	KK54	Thailand	2011
51	KJ198843	SK53	Thailand	2010
52	D00867	Cu1	Germany	1990
53	JX424076	Georgia	Nigeria	2011
54	AF499929	D78	West Africa	2002
55	AF133904	Variant E	USA	1999
56	AF362773	Serotype 2	UK	1960
57	U30818	Serotype 2	USA	

analysis was performed following the Neighbor-Joining approach with the Kimura 2 parameter model and 1000 bootstrap repetitions based on the Poisson correction model in MEGA XI.

## Results

### Necropsy findings

The birds that died due to IBD showed the presence of mild to moderate dehydration and soiled vent feathers. On incision, the thigh and abdominal skeletal muscles revealed widespread petechial to ecchymotic hemorrhages (Fig. 1a). The cloacal bursa appeared swollen, oedematous, yellowish, and occasionally hemorrhagic (Fig. 1b). On incision, the lumen and mucosal surface of the bursa revealed presence of caseous or cheesy exudate, multifocal petechial to ecchymotic hemorrhages, and diffuse ecchymotic hemorrhages (Fig. 1c). The kidneys and spleen appeared swollen and mottled, respectively.

### Histopathological findings

The bursal plicae revealed the presence of extensive necrosis or depletion of follicular lymphoid cells within the cortex and medulla, along with widespread hemorrhages and edema. Few bursal follicles showed extensive depletion of lymphoid cells, forming cystic cavities containing proteinaceous fluid, nuclear debris, and inflammatory cells.

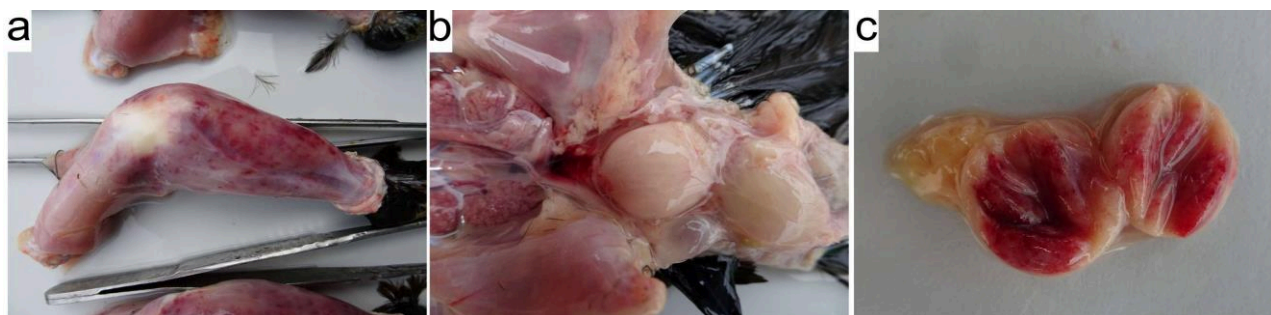
presence of inflammatory cells, and expansion of interfollicular spaces by edema (Figs. 2a and b). The thigh skeletal muscle showed heavy hemorrhages between muscle fibers, causing marked separation. The myofibers also appeared hypereosinophilic, dissociated, or fragmented and showed loss of striations (Fig. 2c). Mild to moderate lymphoid depletion and the formation of vacuoles within lymphoid follicles were evident in the spleen. The liver showed mild hepatocellular vacuolar degeneration and sinusoidal congestion.

### Virus isolation

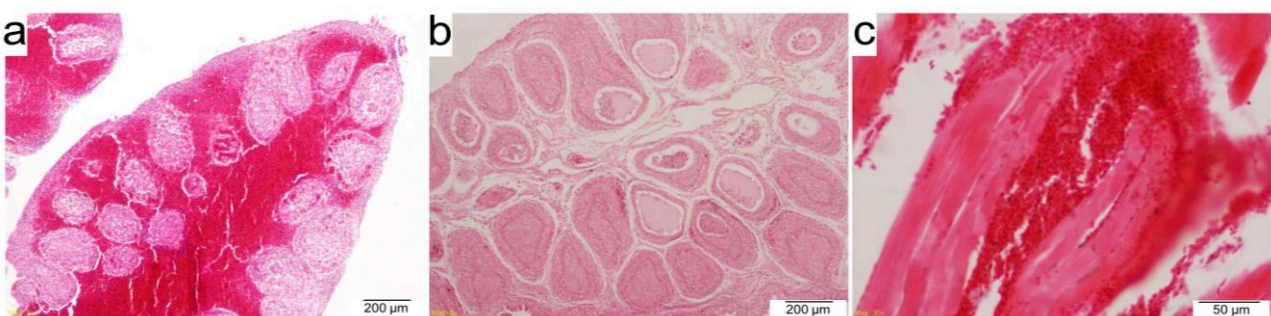
The IBDV field isolates (n=22) showed cytopathic effects (CPE) in the seventh passage after 72 h post-infection. The positive control (vaccine virus) showed CPE in the third passage. The CPE was characterized by swelling, rounding, and granulation of cytoplasm around the nucleus, followed by fragmentation and detachment of the infected cells. In the subsequent passage, a significant increase in detachment of cells was recorded (Fig. 3a). No CPE was recorded in the negative control (Fig. 3b). The IBDV replication in CEF was confirmed by one-step RT-PCR.

### Virus identification by RT-PCR

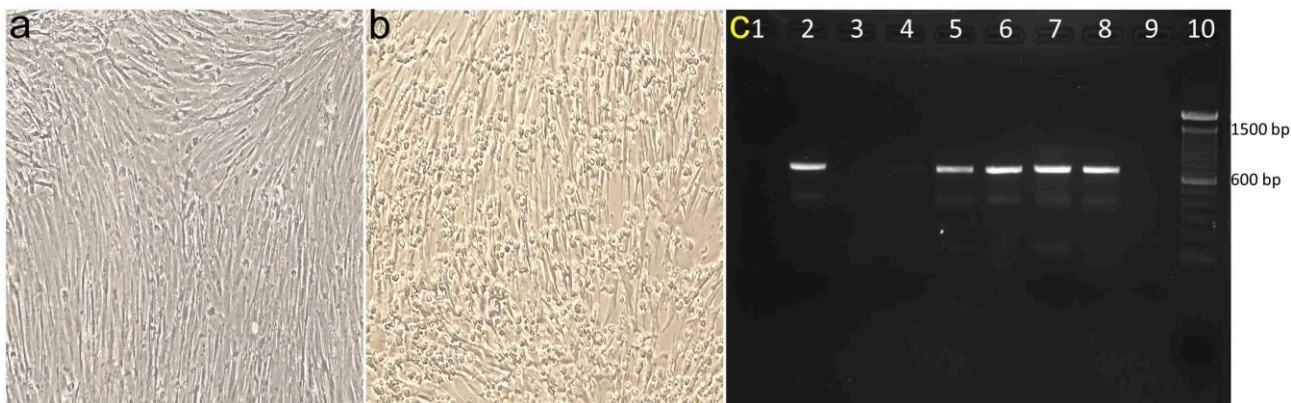
The PCR amplified 664 bp hypervariable region of the VP2 gene (Fig. 3c). The amplification was specific to the primer positions in the genomic RNA of IBDV. A



**Fig. 1:** Necropsy findings of skeletal muscles and cloacal bursa. (a) Widespread petechial to ecchymotic hemorrhages on the thigh skeletal muscles, (b) Swollen, oedematous and yellowish cloacal bursa, and (c) Multifocal petechial to ecchymotic mucosal hemorrhages in the cloacal bursa



**Fig. 2:** Histopathological findings of cloacal bursa. (a) Extensive necrosis or depletion of follicular lymphoid cells within cortex and medulla along with widespread hemorrhages and edema in cloacal bursa (H&E stain, scale bar: 200 µm), (b) Extensive necrosis or depletion of follicular lymphoid cells within cortex and medulla forming cystic cavities containing proteinaceous fluid, nuclear debris and presence of inflammatory cells (H&E stain, scale bar: 200 µm), and (c) Heavy hemorrhages between muscle fibers causing marked separation on the high skeletal muscles. Also note the hypereosinophilic, dissociated or fragmented myofibers with loss of striations (H&E stain, scale bar: 100 µm)

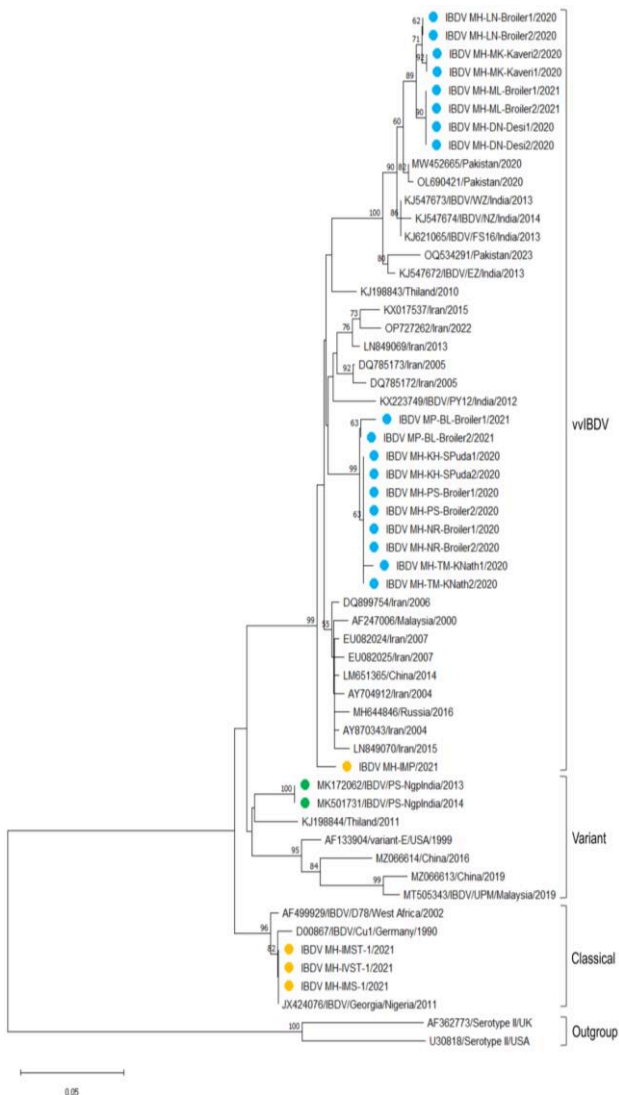


**Fig. 3:** Cytopathic effects of IBD virus on primary chicken embryo fibroblast (CEF) cells and PCR. (a) Swelling, rounding and detachment of chicken embryo fibroblast cells 72 h post inoculation, (b) Negative control showing no CPE, and (c) RT-PCR amplicons of partial VP2 gene of IBDV from field samples. Lane 1: Negative control, Lanes 3 and 9: Negative, Lanes 2 and 4-8: 664 bp amplicons, and Lane 10: 100 bp DNA marker

total of 86.87% samples revealed specific amplification of VP2 gene. The cell culture supernatant from the infected chicken embryo fibroblast cells revealed specific amplification. The negative control did not show amplification.

**Phylogenetic analysis**

The result of the phylogenetic analysis is indicated in Fig. 4. In phylogenetic analysis, revealed the placement of three IBDVs (MH-IMST-1, MH-IVST-1, and MH-IMS-1) with classical IBDVs and other 19 IBDVs (MH-PS-Broiler1, MH-PS-Broiler2, MH-NR-Broiler1, MH-NR-Broiler2, MH-KH-SPuda1, MH-KH-SPuda2, MH-TM-KNath1, MH-TM-KNath2, MP-BL-Broiler1, MP-BL-Broiler2, MH-LN-Broiler1, MH-LN-Broiler2, MH-MK-Kaveri1, MH-MK-Kaveri2, MH-ML-Broiler1, MH-ML-Broiler2, MH-DN-Desi1, MH-DN-Desi2, and MH-IMP) with vvIBDVs. The central Indian IBDVs were placed close to south Indian and Iranian vvIBDVs while western Indian vvIBDVs were placed close to Indian and Pakistani vvIBDVs. A vvIBDV (MH-IMP) was placed distinctly from all other vvIBDVs.



**Fig. 4:** Phylogenetic analysis of the infectious bursal disease virus isolates with the reference GenBank sequences of VP2 gene. A total of 57 strains of IBDV covering three IBDV pathotypes were included for the analysis. Phylogenetic tree was constructed by the Neighbor-Joining method and bootstrapped for 1000 replications. All bootstrapped values are labelled at major nodes

**Discussion**

The necropsy and histopathological findings were typical to the IBD and, according to previous reports (Mor *et al.*, 2010; Singh *et al.*, 2015; Morla *et al.*, 2016; Shinde *et al.*, 2021). The present study reported 5% mortality in indigenous birds, 12.4% in improved native poultry varieties, and 15.25 to 60.18% in broiler flocks. The variation in mortality rate might be attributed to the breed, virulence of the virus, and varying immunological state of the chicken flocks (Blakey, 2023). Classical strains can cause 10-50% mortality, while virulent strains are capable of 50-100% mortality (Dey *et al.*, 2019).

In the present study, the field IBDVs took seven passages for cell culture adaptation and production of virus-specific CPE, while the vaccine virus showed CPE in the third passage. This may be because of the previous adaptation of the vaccine virus to the chicken embryos. The CPE found in the present study was in accordance

with previous studies (Singh *et al.*, 2014; Awandkar *et al.*, 2018). Kumar and Umaphathi (2011) adapted three field IBDVs from Uttarakhand, taking nine blind passages. These isolates showed CPE in the tenth passage after 42-72 h post-infection. Singh *et al.* (2014) reported rounding, detachment, and vacuolation of cells after 48 h post-infection in the fourth passage, which is too early compared to the field isolates of the present study. Rekha *et al.* (2014) reported granulation of cell cytoplasm around the nucleus, similar to the present study.

The PCR yielded a 664 bp amplicon of the *VP2* gene at 49°C, specific to primer positions in the genomic RNA covering both hydrophilic major and minor peaks (Kumar and Umaphathi, 2011; Escaffre *et al.*, 2013; Awandkar *et al.*, 2018). The *VP2* hypervariable nucleotide sequences of the IBDV have been utilized for phylogenetic analysis. In phylogenetic analysis, the IBDVs were placed serotype 1 IBDVs in a distinct cluster, and serotype 2 IBDVs were placed as an outgroup. The cluster formed by serotype 1 IBDVs showed the placement of IBDV isolates in two major clades based on virulence and pathotypes. The classical and variant IBDVs were placed in two separate clads in the first major clad. IBDV (MH-IMST-1, MH-IVST-1, and MH-IMS-1) isolates were placed in the clad formed by classical IBDVs. Two Indian classical IBDVs (MK172062 and MK151731) were distinctly placed in the clad formed by classical IBDVs. The vvIBDV major clad showed the placement of the vvIBDVs in three different clads. IBDV MH-IMP was placed distinctly from other vvIBDVs while 10 IBDVs (MH-PS-Broiler1, MH-PS-Broiler2, MH-NR-Broiler1, MH-NR-Broiler2, MH-KH-SPuda1, MH-KH-SPuda2, MH-TM-KNath1, MH-TM-KNath2, MP-BL-Broiler1, and MP-BL-Broiler2) were placed in another cluster close to the isolates from Pondicherry and Iran and 8 IBDVs (MH-LN-Broiler1, MH-LN-Broiler2, MH-MK-Kaveri1, MH-MK-Kaveri2, MH-ML-Broiler1, MH-ML-Broiler2, MH-DN-Desi1, and MH-DN-Desi2) in third clad with Pakistani IBDVs. The phylogenetic analysis identified three IBDVs as classical strains and the remaining 18 isolates as vvIBDVs. The vvIBDVs circulating in the poultry flocks of central India were closely placed with south Indian vvIBDV while western Indian vvIBDVs were closely placed with a Pakistani vvIBDV. Other Indian vvIBDVs were clustered distinctly with western Indian isolates. The IBDVs are classified into classical, variant, and very virulent strains depending on their virulence (Van den Berg *et al.*, 2000). The phylogenetic analysis of the present investigation also classified the IBDVs based on their virulence. Similar placements of Indian and global IBDVs were reported in the literature (Tammiranta *et al.*, 2018; Michel *et al.*, 2019; Mató *et al.*, 2020; Jiang *et al.*, 2021). The partial *VP2* gene sequence grouped the IBDVs into different genotypes depending on virulence. However, due to the reassortment and recombination with field circulating viruses (Raja *et al.*, 2016), segment B may also be deciphered to determine the molecular identity of IBDV.

## Acknowledgements

This work did not receive any grant from funding agencies in the public, commercial, or not-for-profit sectors. Authors acknowledge M/s Ventri Biologicals, VHPL, Pune, and M/s. Saumya Hatcheries, Jakekur MIDC, and Omarga for supplying embryonated chicken eggs, and the poultry farmers gave consents to include the samples in the study.

## Conflict of interest

The authors declare that there are no conflicts of interest.

## References

- Awandkar, SP; Tembhurne, PA; Kesharkar, JA; Kurkure, NV; Chaudhari, SP; Bonde, SW and Ingle, VC (2018). Identification and characterization of a novel infectious bursal disease virus from outbreaks in Maharashtra Province of India. *Vet. World*. 11: 1516-1525.
- Blakey, J (2023). Infectious bursal disease in poultry. In: Abuelo, A; Brutlag, A; Carnevale, J; Dart, A; Davidson, G; Davis, JL; Eide, M; Ramirez, A and Swayne, DE (Eds.), *MSD veterinary manual*. (11th Edn.), USA. Available through <https://www.msdvetmanual.com/poultry/Infectious-bursal-disease/Infectious-bursal-disease-in-poultry> (viewed on 02 October 2023).
- Camilotti, E; Moraes, LBD; Furian, TQ; Borges, KA; Moraes, HLD and Salle, CTP (2016). Infectious bursal disease: pathogenicity and immunogenicity of vaccines. *Braz. J. Poultry Sci.*, 18: 303-308.
- Dey, S; Pathak, DC; Ramamurthy, N; Maity, HK and Chellappa, MM (2019). Infectious bursal disease virus in chickens: prevalence, impact, and management strategies. *Vet. Med. Res.*, 10: 85-97.
- Economic Survey, GOI (2021). Allied sectors: Animal husbandry, dairying and fisheries. *Economic survey 2020-21*. (1st Edn.), Ministry of Finance, Government of India. P: 614. Available through [https://www.indiabudget.gov.in/economicssurvey/ebook\\_es2021/index.html#p=614](https://www.indiabudget.gov.in/economicssurvey/ebook_es2021/index.html#p=614) (viewed 17 October 2023).
- Escaffre, O; Le Nouën, C; Amelot, M; Ambroggio, X; Ogden, KM; Guionie, O; Toquin, D; Müller, H; Islam, MR and Eterradossi, N (2013). Both genome segments contribute to the pathogenicity of very virulent infectious bursal disease virus. *J. Virol.*, 87: 2767-2780.
- Freshney, RI (2016). Primary culture. In: Freshney, RI (Eds.), *Culture of animal cells: a manual of basic technique and specialized applications*. (7th Edn.), Hoboken, New Jersey, John Wiley and Sons, Inc., PP: 395-427.
- Jiang, N; Wang, Y; Zhang, W; Niu, X; Gao, Y; Gao, L; Li, K; Cui, H; Liu, A; Pan, Q and Liu, C (2021). Naturally occurring mutated infectious bursal disease virus of genotype A8B1 associated with bursa damage in China. *Virus Res.*, 302: 198498. doi: 10.1016/j.virusres.2021.198498.
- Kumar, A and Umaphathi, V (2011). Sequence analysis of a part of hypervariable region of *VP2* gene of chicken embryo fibroblast adapted Infectious Bursal Disease virus isolates of Uttarakhand. *J. Biotechnol., Bioinfo. and Bioeng.*, 1: 109-118.
- Mató, T; Tatár-Kis, T; Felföldi, B; Jansson, DS;

- Homonnay, Z; Bányai, K and Palya, V** (2020). Occurrence and spread of a reassortant very virulent genotype of infectious bursal disease virus with altered VP2 amino acid profile and pathogenicity in some European countries. *Vet. Microbiol.*, 245: 108663. doi: 10.1016/j.vetmic.2020.108663.
- Michel, LO; Kimber, ML and Jackwood, DJ** (2019). New introduction of a very virulent infectious bursal disease virus in New York, USA. *Avian Pathol.*, 48: 486-491.
- Mor, SK; Narang, G; Jindal, N; Mahajan, NK; Sharma, PC and Rakha, NK** (2010). Epidemiological studies on infectious bursal disease in broiler chickens in Haryana, India. *Int. J. Poult. Sci.*, 9: 395-400.
- Morla, S; Deka, P and Kumar, S** (2016). Isolation of novel variants of infectious bursal disease virus from different outbreaks in Northeast India. *Microb. Pathog.*, 93: 131-136.
- Pitesky, M; Cataline, K; Crossley, B; Poulos, M; Ramos, G; Willoughby, D; Woolcock, P; Cutler, G; Bland, M; Tran, J and Jackwood, D** (2013). Historical, spatial, temporal, and time-space epidemiology of very virulent infectious bursal disease in California: A retrospective study 2008-2011. *Avian Dis.*, 57: 76-82.
- Raja, P; Senthilkumar, TMA; Parthiban, M; Thangavelu, A; Gowri, AM; Palanisammi, A and Kumanan, K** (2016). Complete genome sequence analysis of a naturally reassorted infectious bursal disease virus from India. *Genome Announc.*, 4: e00709-16.
- Rekha, K; Sivasubramanian, C; Chung, CM and Thiruvengadam, M** (2014). Growth and replication of infectious bursal disease virus in the DF-1 cell line and chicken embryo fibroblasts. *Biomed Res. Int.*, 2014: 494835.
- Shinde, RS; Chauhan, HC; Patel, AC; Sharma, KK; Patel, SS; Mohapatra, SK; Shrimali, MD and Chandel, BS** (2021). VP2 gene sequencing-based Geno-grouping of infectious bursal disease viruses isolated from Gujarat and Maharashtra state (India). *Virus Dis.*, 18: 1-7.
- Singh, J; Banga, HS; Brar, RS; Singh, ND; Sodhi, S and Leishangthem, GD** (2015). Histopathological and immunohistochemical diagnosis of infectious bursal disease in poultry birds. *Vet. World*. 8: 1331-1339.
- Singh, Y; Yadav, K; Singh, VK and Kumar, R** (2014). Molecular diagnosis and adaptation of highly virulent infectious bursal disease virus on chicken embryo fibroblast cell. *Vet. World*. 7: 351-355.
- Spencer, LT and Bancroft, JD** (2013). Tissue processing. In: Suvarna, SK; Layton, C and Bancroft, JD (Eds.), *Theory and practice of histological techniques*. (7th Edn.), Edinburgh, Churchill Livingstone Publisher. PP: 105-123.
- Tammiranta, N; Ek-Kommonen, C; Rossow, L and Huovilainen, A** (2018). Circulation of very virulent avian infectious bursal disease virus in Finland. *Avian Pathol.*, 47: 520-525.
- Van den Berg, TP; Eterradossi, N; Toquin, D and Meulemans, G** (2000). Infectious bursal disease (Gumboro disease). *Rev. Sci. Tech. Off. Int. Epiz.*, 19: 509-543.
- Yamaguchi, T; Ogawa, M; Miyoshi, M; Inoshima, Y; Fukushi, H and Hirai, K** (1997). Sequence and phylogenetic analyses of highly virulent infectious bursal disease virus. *Arch. Virol.*, 142: 1441-1458.