

Induction of general anaesthesia with intraosseous injection of thiopental in rabbits

Sarrafzadeh-Rezaei, F.^{1*}; Dalir-Naghadeh, B.¹
and Hassanpour, H.²

¹Department of Clinical Sciences, Faculty of Veterinary Medicine, Urmia University, Urmia, Iran;

²Department of Basic Sciences; Faculty of Veterinary Medicine, Shahrekord University, Shahrekord, Iran

***Correspondence:** F. Sarrafzadeh-Rezaei, Department of Clinical Sciences, Faculty of Veterinary Medicine, Urmia University, Urmia, Iran. E-mail: f.sarrafzadeh@mail.urmia.ac.ir

(Received 30 Jun 2007; revised version 16 Dec 2007; accepted 24 Dec 2007)

Summary

The technique of intraosseous (IO) infusion has been reemerged as an alternative route of intravascular access for the delivery of fluids and some medications. Complications of IO infusion occur rarely and include fractures and osteomyelitis after long-term use of IO access. The purpose of this study was to compare the efficiency of induction of anaesthesia by a standard intravenous route and an intraosseous route. Ten healthy rabbits were assigned to one of two treatments: thiopental 20 mg/kg administered intravenously via marginal vein of ear and thiopental 20 mg/kg administered intraosseously into the bone marrow of proximal tibia. In each rabbit, the heart and respiratory rates and palpebral, corneal, pinch and withdrawal reflexes were recorded before and every 2 min, for 34 min after induction of anaesthesia. Neither the clinical parameters nor the reflexes showed any significant difference ($P>0.05$) between the treatment groups. In addition, no adverse reaction was seen in rabbits anaesthetized by intraosseous access. The results of this study showed that the intraosseous injection of thiopental is a rapid, simple, safe and effective alternative option for induction of general anaesthesia in rabbits.

Key words: Intraosseous, Intravenous, Anaesthesia, Thiopental, Rabbit

Introduction

Rabbits are widely used as laboratory animals in experimental surgeries and recently as pet. A safe anaesthetic method is therefore required both for surgeons undertaking research and for practicing veterinarians. Intubation of the rabbit and use of a volatile anaesthetic agent may be too complicated and time-consuming. Among the described methods of anaesthesia in rabbits, injection of anaesthetics seems to be the most popular method (Kilic, 2004; Orr *et al.*, 2005). Furthermore, intravenous anaesthetics may be used for short diagnostic or surgical procedures in rabbits (Borkowski and Karas, 1999; Orr *et al.*, 2005). However, due to difficulty of intravenous injection of anaesthetics in rabbits, introducing new routes of injection may be valuable.

Infusion of blood and fluids into the

circulation via bone marrow was first described in the 1940s as an alternative to intravenous infusion in critically ill children in whom intravenous access has proved unsuccessful (Engle, 2006). The intraosseous (IO) infusion technique utilizes the rich vascular network of the medullary cavity of long bone for transporting fluid or drugs from the medullary space of the bone to the systemic circulation (Rosetti *et al.*, 1985; Schoffstall *et al.*, 1989; Seigler *et al.*, 1989; Bilello *et al.*, 1991). The IO route provides a rapid and reliable access to the systemic venous circulation in human and animal population. This technique is safe, complications are infrequent and the benefits clearly outweigh the risks. The IO technique has almost completely replaced veins cutdown procedures in children and animals (Haas, 2004). It has been suggested that a variety of fluids (e.g. crystalloids, colloids, blood products), resuscitation agents, some

drugs and parenteral nutritional fluids can be safely given via the intraosseous route (Walsh-Kelly *et al.*, 1986; Brickman *et al.*, 1987; Neish *et al.*, 1988; Lathers *et al.*, 1989; Schoffstall *et al.*, 1989; Bilello *et al.*, 1991; Okrasinski *et al.*, 1992; Valverde *et al.*, 1993; Herman *et al.*, 1999; Kentner *et al.*, 1999; Stoll *et al.*, 2002; Haas, 2004; Engle, 2006).

Due to fine structure of peripheral veins, intravenous injection of medications in rabbits may be difficult and time-consuming. However, the use of IO injection may provide prompt access to systemic circulation. In particular, this technique may have some advantages in induction of general anaesthesia with specific intravenous anaesthetics. Numerous animal studies have confirmed the effectiveness of intraosseous infusion compared with other methods of vascular access (Brickman *et al.*, 1987; Lathers *et al.*, 1989; Schoffstall *et al.*, 1989; Okrasinski *et al.*, 1992; Valverde *et al.*, 1993; Brickman *et al.*, 1996; Gunal *et al.*, 1996; Kentner *et al.*, 1999; Butt *et al.*, 2001). To the knowledge of the authors, usefulness of intraosseous access as an alternative route of intravenous induction of general anaesthesia has not been evaluated in rabbits. Therefore, the purpose of this study was to determine whether the intraosseous delivery of thiopental sodium is as effective as its intravenous administration.

Materials and Methods

The experimental procedures and animal care were reviewed and approved by the department of clinical sciences review board at Veterinary College of Urmia University with reference number 331.

Ten adult healthy White New Zealand rabbits of both sexes, weighing 1900 to 2500 g (2135 ± 197) were provided by Razi Institute (Karaj, Iran). The rabbits were kept in a controlled environment (room temperature, 18-21°C; humidity, 55-65%), fed a commercial pellet diet (Niro Sahand Co., Tabriz, Iran) and allowed *ad libitum* access to tap water. The rabbits were randomly assigned to two groups: (I) thiopental sodium 2.5% (Specia Rhone-Poulenc Rorer, Paris, France), 20 mg/kg

intravenously and (II) thiopental sodium 2.5%, 20 mg/kg intraosseously. The dose of thiopental sodium was according to Sedgwick (1986). Core body temperature of the rabbits was monitored with a rectal probe and maintained at $37 \pm 0.5^\circ\text{C}$ during the entire experiment.

For intravenous injection, the marginal vein of either ear was accessed. Injection was made by the use of 25 gauge scalp vein set (Shandong Zibo Shanchuan Medical Instrument Co. Ltd., Shandong, China). For intraosseous injection, the medial surface of proximal extremity of right tibia was shaved and aseptically prepared. Once a sterile site has been achieved, a 1% lidocaine hydrochloride (Kela Laboratoria, Hoogstraten, Belgium) was utilized to desensitize the skin and periosteum over the above mentioned area. During this process, local anaesthetic was first infiltrated into the skin and subcutaneous tissue to anaesthetize an area approximately 5 mm in diameter. After the skin numbness, 1 ml of 1% lidocaine was infiltrated directly over the periosteum to numb an area approximately 5-10 mm in diameter.

The medullary cavity of tibia was accessed via a 22 gauge, 3 cm length bone marrow aspiration needle. Entrance into the marrow space was sensed when a "give" (loss of resistance) occurred, and the needle stood on its own (Gunal *et al.*, 1996).

Variables including heart and respiratory rates as well as duration of absence of palpebral, corneal, pinch and withdrawal reflexes were recorded before and within 34 min (at 2-min intervals) after injection of thiopental sodium. Moreover, mean arousal time was recorded after administration of the anaesthetic. The mean arousal time is defined as the time from injection until the rabbits raised the head and sat unaided on the sternum.

In addition, the time required for accessing the vein or medullary cavity was recorded. The animals were examined for probable complications of general anaesthesia and local reactions at injection sites (IO injection group) for 5 days after experiment.

Statistical analysis

Data were checked for outliers and

normality using Kolmogorov-Smirnov test. Independent Student's t-test was used to compare the arousal time and duration of absence of reflexes in rabbits anaesthetized with intravenous and intraosseous infusion of thiopental sodium. The trends of heart and respiratory rates during anaesthesia in each group (within subjects) and between two groups (between subjects) were compared with repeated measures ANOVA followed by Bonferroni test for pairwise comparisons. Statistical analysis was performed on the data driven up to 22 min after anaesthesia, as afterward the numbers of rabbits remained anaesthetized were not sufficient for analysis. Differences were considered statistically significant when $p < 0.05$. Data were analysed using statistical software (SPSS Inc, Version 12, IL, USA).

Results

Induction and recovery of anaesthesia were performed successfully in both treatment groups without any problem or mortality. The time (mean \pm standard deviation) required for accessing the marginal vein of ear and medullary cavity of proximal tibia were, 3.2 ± 1.6 and 1.1 ± 0.1 min (including the time required for preparing and anaesthetizing the skin and subcutaneous tissue of injection site), respectively. The statistical analysis showed significant difference between accessing time of the marginal vein of ear and medullary cavity of proximal tibia ($P < 0.05$).

There was no significant difference ($P > 0.05$) between mean arousal time and duration of absence of reflexes in rabbits anaesthetized with intravenous and intraosseous infusion of thiopental sodium (Table 1). The trends of changes in heart and respiratory rates during anaesthesia are presented in Figs. 1 and 2, respectively. Repeated measures ANOVA showed no significant differences ($P > 0.05$) in heart rate during anaesthesia in each group and between two groups in each occasion, too. Although, a markable reduction of mean heart rate was noted immediately after induction of anaesthesia in rabbits anaesthetized by intraosseous route (Fig. 1), but this reduction was not significant

compared to that of rabbits anaesthetized with intravenous route ($P = 0.572$). The trend of respiratory rates showed a significant decrease ($P < 0.01$) after induction of anaesthesia in both groups (Fig. 2), but in contrast to rabbits anaesthetized by intravenous route in which the decreased rate lasted up to 22 min after induction, in rabbits anaesthetized by intraosseous route this change was significant only by 10 min after induction of anaesthesia. In addition, no significant changes were noted between two groups at each occasion ($P > 0.05$).

Discussion

The results of this study revealed that the

Table 1: Comparison of mean arousal time (minutes) and duration of absence of reflexes (minutes) in rabbits anaesthetized with intravenous (5 rabbits) and intraosseous (5 rabbits) infusion of thiopental sodium

| Parameters | Mean \pm SE | | P-value |
|-------------------|----------------|----------------|---------|
| | Intravenous | Intraosseous | |
| Mean arousal time | 25.2 \pm 2.2 | 26.4 \pm 2.7 | 0.737 |
| Withdrawal reflex | 2.4 \pm 1.0 | 3.6 \pm 1.8 | 0.584 |
| Pinch reflex | 8.1 \pm 2.1 | 8.8 \pm 2.7 | 0.822 |
| Palpebral reflex | 9.2 \pm 2.1 | 8.4 \pm 2.7 | 0.820 |
| Corneal reflex | 5.2 \pm 1.5 | 6.8 \pm 2.6 | 0.606 |

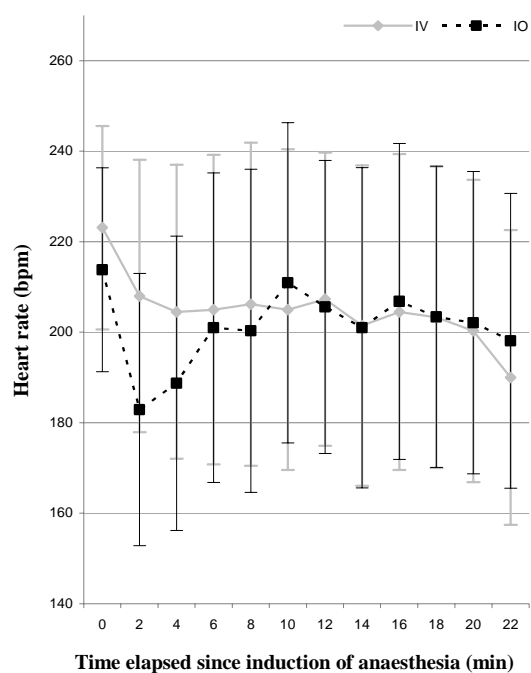


Fig. 1: Comparison of heart rate (Mean \pm SE) in rabbits anaesthetized with intravenous (IV) and intraosseous (IO) infusion of thiopental sodium

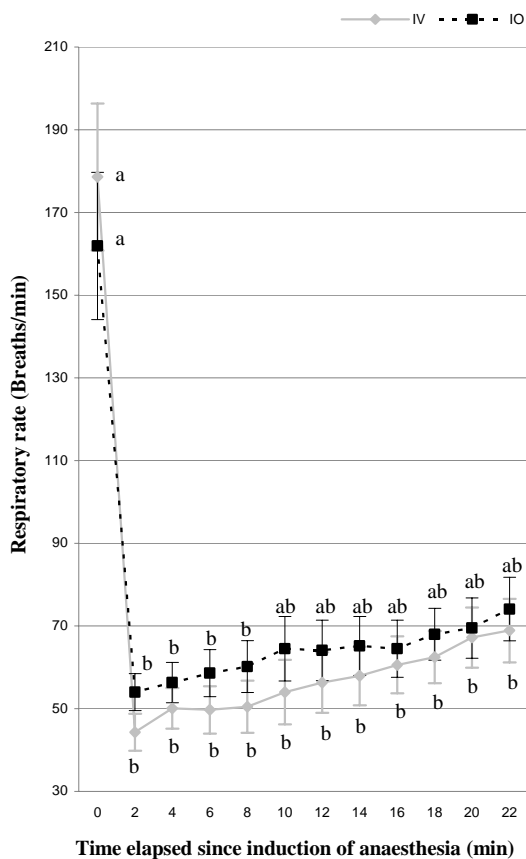


Fig. 2: Comparison of respiratory rate (Mean \pm SE) in rabbits anaesthetized with intravenous (IV) and intraosseous (IO) infusion of thiopental sodium (in each group different letters show significant difference at $P < 0.01$)

intraosseous injection of thiopental through tibia is as effective as its intravenous administration for induction of general anaesthesia in rabbits. Intraosseous infusion was widely used in the 1940s, but it was superseded by the modern peripheral over-needle venous cannula (Hurren, 2000). However, in situations with repeated failure in establishing a peripheral venous line, intraosseous injection may provide a rapid, reliable and safe alternative.

Intravenous injection of drugs in rabbits due to fragile veins is difficult and time consuming, whereas intraosseous injection is very simple and fast. However, the site of cannulation needs to be anaesthetized. Due to the absence of massive soft tissue in the medial surface of the proximal extremity of tibia, 1 to 2 ml of 1% lidocaine without epinephrine was sufficient to anaesthetize the cannulation site. Engle (2006) reported

that local anaesthesia is appropriate in a conscious patient before placement of an intraosseous needle. The needle should be inserted nearly perpendicular into the bone using a back-and-forth twisting motion. In this study, the absence of signs of discomfort (increased heart and/or respiratory rate, withdrawal of foot) in animal model, during cannulation and injection indicated that anaesthetizing the skin and subcutaneous tissues is a reasonable method in relieving of pain in animals. The significant difference ($P = 0.019$) between vein and intraosseous accessing time is of high clinical importance in induction of anaesthesia in laboratory animals, especially in cases in which accessing to vein may be time consuming, difficult or impossible.

In the present study, we used proximal tibia for needle insertion which is the most commonly recommended site for intraosseous access in human and animals (Smith *et al.*, 2005; Engle, 2006). Theoretically, any safe superficial bone such as calcaneus (Clem and Tierney, 2004) and radial styloid (McCarthy *et al.*, 2003) can be used for intraosseous infusion (McCarthy *et al.*, 2003; Smith *et al.*, 2005). Calcaneus is composed of cancellous bone that has an open trabecular structure similar to the medullary cavity of long bones, which may explain why fluids can be administered via this site (McCarthy *et al.*, 2003). Therefore, infusion of drugs to calcaneus bone can be regarded as an alternative site to proximal tibia for induction of anaesthesia in rabbits.

For IO infusion, several intraosseous needles are commercially available. These needles are rigid and contain a stylet to prevent plugging with bone spicules. A large-gauge needle with a stylet, such as a lumbar puncture needle or hypodermic needle can also be used. A large bore butterfly needle may be used, but plugging may complicate the success of the procedure (Jun *et al.*, 2000; Engle, 2006).

No systemic reaction was observed in rabbits infused with intraosseous route. Except in one case which had a mild skin reaction to injection of lidocaine hydrochloride, no other local reactions such as haematoma formation, signs of infection or tissue necrosis were noted at the site of

cannulation. Although several reports have documented complications of intraosseous infusion, limited prospective research have been done to assess long-term complications associated with this method. The reported technical failures and complications of intraosseous infusion include: obstruction secondary to bony spicules, abutting the needle tip against the bony wall, clot formation, infections, infiltration of adjacent tissues with fluids or drugs following needle displacement, air or fat emboli, fracture at intraosseous entry site, injury to local soft tissues or physis, skin necrosis and compartment syndrome (Brickman *et al.*, 1996; Gunal *et al.*, 1996; Herman *et al.*, 1999; Haas, 2004; Smith *et al.*, 2005; Engle, 2006). However, the success rates with intraosseous infusions were reported up to 98.2%, and approximately in 8% of cases the infusion was interrupted to change the intraosseous site, resolve a haematoma, or replace a bent needle (Engle, 2006). Reportedly, osteomyelitis has been one of the most serious complications of intraosseous infusion (Brickman *et al.*, 1996; Smith *et al.*, 2005; Engle, 2006).

Most of the reported complications can be related to poor insertion technique, poor asepsis or long-term access to the marrow cavity (Brickman *et al.*, 1996; Gunal *et al.*, 1996; Herman *et al.*, 1999; Haas, 2004; Smith *et al.*, 2005; Engle, 2006).

In the present study there were no significant differences between vital signs (heart and respiratory rates) and reflex responses (palpebral, corneal, pinch and withdrawal reflexes) during induction and recovery of anaesthesia and also arousal time in both routes in an animal model. Injection of thiopental other than IV route is prohibited due to its high pH. Therefore, introducing of a new and valid route of administration of thiopental other than IV method could be of high importance especially in laboratory animals. It was also found that intraosseous injection of thiopental was as effective as intravenous injection to induce general anaesthesia. Moreover, the IO injection can be easily applied in rabbits with various sizes and in different physiological conditions.

In conclusion, it could be recommended that intraosseous injection of thiopental can

be used as a simple, rapid, safe and useful option for induction of anaesthesia in rabbits. Intraosseous injection of other medications in emergency situations can also be taken into consideration, when an immediate intravascular access is essential.

References

- Bilello, JF; O'Hair, KC; Kirby, WC and Moore, JW (1991). Intraosseous infusion of dobutamine and isoproterenol. *Am. J. Dis. Child.*, 145: 165-167.
- Borkowski, R and Karas, AZ (1999). Sedation and anesthesia of pet rabbits. *Clin. Tech. Small Anim. Pract.*, 14: 44-49.
- Brickman, KR; Rega, P and Guinness, M (1987). Comparative study of intraosseous versus peripheral intravenous infusion of diazepam and phenobarbital in dogs. *Ann. Emerg. Med.*, 16: 1141-1144.
- Brickman, KR; Rega, P; Schoolfield, L; Harkins, K; Weisbrode, SE and Reynolds, G (1996). Investigation of bone developmental and histopathologic changes from intraosseous infusion. *Ann. Emerg. Med.*, 28: 430-435.
- Butt, TD; Bailey, JV; Dowling, PM and Fretz, PB (2001). Comparison of 2 techniques for regional antibiotic delivery to the equine forelimb: intraosseous perfusion vs. intravenous perfusion. *Can. Vet. J.*, 42: 617-622.
- Clem, M and Tierney, P (2004). Intraosseous infusions via the calcaneus. *Resuscitation*. 62: 107-112.
- Engle, WA (2006). Intraosseous access for administration of medications in neonates. *Clin. Perinatol.*, 33: 161-168.
- Gunal, I; Kose, N and Gurer, D (1996). Compartment syndrome after intraosseous infusion: an experimental study in dogs. *J. Pediatr. Surg.*, 31: 1491-1493.
- Haas, NA (2004). Clinical review: vascular access for fluid infusion in children. *Crit. Care*. 8: 478-484.
- Herman, MI; Chyka, PA; Butler, AY and Rieger, SE (1999). Methylene blue by intraosseous infusion for methemoglobinemia. *Ann. Emerg. Med.*, 33: 111-113.
- Hurren, JS (2000). Can blood taken from intraosseous cannulations be used for blood analysis? *Burns*. 26: 727-730.
- Jun, H; Haruyama, AZ; Chang, KS and Yamamoto, LG (2000). Comparison of a new screw-tipped intraosseous needle versus a standard bone marrow aspiration needle for infusion. *Am. J. Emerg. Med.*, 18: 135-139.
- Kentner, R; Haas, T; Gervais, H; Hiller, B and

- Dick, W (1999). Pharmacokinetics and pharmacodynamics of hydroxyethyl starch in hypovolemic pigs: a comparison of peripheral and intraosseous infusion. *Resuscitation*. 40: 37-44.
- Kilic, N (2004). A comparison between medetomidine-ketamine and xylazine-ketamine anaesthesia in rabbits. *Turk. J. Vet. Anim. Sci.*, 28: 921-926.
- Lathers, CM; Jim, KF; High, WB; Spivey, WH; Matthews, WD and Ho, T (1989). An investigation of the pathological and physiological effects of intraosseous sodium bicarbonate in pigs. *J. Clin. Pharmacol.*, 29: 354-359.
- McCarthy, G; O'Donnell, C and O'Brien, M (2003). Successful intraosseous infusion in the critically ill patient does not require a medullary cavity. *Resuscitation*. 56: 183-186.
- Neish, MD; Macon, MG; Moore, JW and Graeber, GM (1988). Intraosseous infusion of hypertonic glucose and dopamine. *Am. J. Dis. Child.*, 142: 878-880.
- Okrasinski, EB; Krahwinkel, DJ and Sanders, WL (1992). Treatment of dogs in hemorrhagic shock by intraosseous infusion of hypertonic saline and dextran. *Vet. Surg.*, 21: 20-24.
- Orr, HE; Roughan, JV and Flecknell, PA (2005). Assessment of ketamine and medetomidine anaesthesia in the domestic rabbit. *Vet. Anaesth. Analg.*, 32: 271-279.
- Rosetti, VA; Thompson, BM; Miller, J; Mateer, JR and Aprahamian, C (1985). Intraosseous infusion: an alternative route of pediatric intravascular access. *Ann. Emerg. Med.*, 14: 885-888.
- Schoffstall, JM; Spivey, WH; Davidheiser, S and Lathers, CM (1989). Intraosseous crystalloid and blood infusion in a swine model. *J. Trauma*. 29: 384-387.
- Sedgwick, CJ (1986). Anesthesia for rabbits. *Vet. Clin. North Am. Food Anim. Pract.*, 2: 731-736.
- Seigler, RS; Tecklenburg, FW and Shealy, R (1989). Prehospital intraosseous infusion by emergency medical services personnel: a prospective study. *Pediatrics*. 84: 173-177.
- Smith, R; Davis, N; Bouamra, O and Lecky, F (2005). The utilisation of intraosseous infusion in the resuscitation of paediatric major trauma patients. *Injury*. 36: 1034-1038.
- Stoll, E; Golej, J; Burda, G; Hermon, M; Boigner, H and Trittenwein, G (2002). Osteomyelitis at the injection site of adrenalin through an intraosseous needle in a 3-month-old infant. *Resuscitation*. 53: 315-318.
- Valverde, A; Bienzle, D; Smith, DA; Dyson, DH and Valliant, AE (1993). Intraosseous cannulation and drug administration for induction of anesthesia in chickens. *Vet. Surg.*, 22: 240-244.
- Walsh-Kelly, CM; Berens, RJ; Glaeser, PW and Losek, JD (1986). Intraosseous infusion of phenytoin. *Am. J. Emerg. Med.*, 4: 523-524.