



IJVR

ISSN: 1728-1997 (Print)
ISSN: 2252-0589 (Online)

Vol. 20

No. 4

Ser. No. 69

2019

**IRANIAN
JOURNAL
OF
VETERINARY
RESEARCH**



Scientific Report

Successful treatment of cardiac dysrhythmia associated with foot and mouth disease in a calf

Priyanka, M.^{1*}; Mahendran, K.²; Umapathi, V.³; Dechamma, H. J.³; Patel, B. H. M.¹; Reddy, G. R.³ and Sanyal, A.³

¹Animal Experimentation Station, Indian Veterinary Research Institute, Regional Campus, Hebbal, Bengaluru-560024, India; ²Division of Medicine, Indian Veterinary Research Institute, Bareilly-243122, Uttar Pradesh, India; ³FMD Research Laboratory, Indian Veterinary Research Institute, Regional Campus, Hebbal, Bengaluru-560024, India

*Correspondence: M. Priyanka, Animal Experimentation Station, Indian Veterinary Research Institute, Regional Campus, Hebbal, Bengaluru-560024, India. E-mail: bidarvet@gmail.com

(Received 22 Jan 2019; revised version 4 May 2019; accepted 22 Jun 2019)

Abstract

Background: Foot and mouth disease (FMD), which causes myocarditis, results in 50% sudden death in the suckling calves. Occurrence of arrhythmias associated with FMD induced myocarditis in calves is not reported *hitherto*. The present work documents the arrhythmias associated with FMD in calf and their treatment using appropriate antiarrhythmic drugs. **Case description:** A three-month-old male Holstein Friesian crossbred calf naturally suffering from FMD was selected for the present study. **Findings/treatment and outcome:** Cardiac auscultation revealed grade 4 systolic murmurs and electrocardiography (ECG) showed sustained polymorphic ventricular premature complexes (PVPCs) with tachycardia on bipolar base apex lead. Apart from standard treatment, lidocaine 2% was administered at dose of 0.6 mg/kg intravenously over 15 min once a day and sinus rhythm was restored by 76 h post-treatment. Review of ECG and haematobiochemical examination revealed normal findings on 7th day of treatment. **Conclusion:** The study demonstrates the presence of sustained PVPCs with tachycardia due to FMD induced myocarditis and the successful use of lidocaine in restoring the sinus rhythm and recovery of the calf.

Key words: Arrhythmia, Flunixin Meglumine, FMD, Lidocaine, Myocarditis

Introduction

Foot and mouth disease (FMD) is a highly contagious viral disease affecting all cloven-footed domestic and wild animals worldwide (Brown *et al.*, 1992; Kaya *et al.*, 2013). It is known to cause fatal myocarditis in young suckling calves resulting in high mortality up to 50% (Barker *et al.*, 1993). Foot and mouth disease virus (FMDV) induced myocarditis is a cause of concern, as the affected calves die suddenly without showing any clinical signs (Alexandersen *et al.*, 2003; Aktas *et al.*, 2015). Diagnosis of FMDV induced myocarditis is very challenging in field conditions. Presently it is diagnosed based on the history of FMD outbreak in that area, incidence of sudden death of calves, physical examination, cardiac auscultation, and estimation of biomarkers like cardiac troponin (Aktas *et al.*, 2015).

Inflammatory and remodeling processes associated with myocarditis will elicit the occurrence of arrhythmias by affecting the conduction and repolarization in myocardium, altering membrane potential, development of ectopic pacemaker, late potentials and reentry mechanisms (Klein *et al.*, 2000; Ukena *et al.*, 2011). Electrocardiography (ECG) is a widely used screening tool in the diagnosis of viral myocarditis in human

medicine and can indicate the site and extent of myocardial injury (Ukena *et al.*, 2011; Deluigi *et al.*, 2013). This intum might help veterinarians to choose the appropriate therapy and thereby reduce the associated mortality. Although FMDV induced myocarditis is a well-known pathology in suckling calves, there are no reports describing the associated arrhythmias and their treatment. Present paper describes the occurrence of polymorphic ventricular premature complexes (PVPCs) associated with FMD in calf and its successful treatment.

Case description

A three-month-old male Holstein Friesian crossbred calf weighing around 31 kg reared under intensive system of farming at Bangalore rural farm, Karnataka, India was suffering from salivation and severe weakness since two days. On physical examination, calf was weak in body condition [body condition score (BCS) was 4 on 9 point scale; Radostits *et al.*, 2007] with dull mentation. Rectal temperature was 103.2°F and conjunctival mucous membrane was severely congested. Auscultation of the heart revealed arrhythmias with systolic murmur of grade 4 (out of 6). Pulse rate was increased (86/min). Capillary refill time was in normal reference limits (<2

s). Examination of oral cavity revealed the presence of erosive lesions on dorsal aspect of tongue and dental pad. No lesions were observed in interdigital space. There was history of occurrence of FMD outbreak in the herd. Tongue epithelium and blood sample were collected for further laboratory examination.

Electrocardiography was recorded in bipolar base apex lead using limb lead I. Electrocardiography was recorded in standing position by placing the rubber mat underneath the animal without any tranquilizer or sedative. Alligator type electrodes were attached to skin after cleaning it with ethanol and applying electrocardiographic jelly. The positive electrode of the lead I was attached to the skin of the 5th intercostal space just caudal to olecranon and negative electrode on jugular furrow about the lower 1/3 of the left side of the neck. Electrocardiography was obtained in single channel with the paper speed of 25 mm/s and calibration of 10 mm equal to 1 mV.

Results

Haemato-biochemical findings

Complete blood count (CBC) and serum biochemical analysis revealed mild leukocytosis, elevated levels of serum creatine kinase myocardial band (CK-MB) (226 U/L; reference range: 17-23 U/L), lactate dehydrogenase (LDH) (1934 U/L; reference range: 1313-1616 U/L), aspartate aminotransferase (AST) (312 U/L; reference range: 118-142 U/L) and cardiac troponin I (cTnI) (41.8 pg/ml; reference range: 0-26 pg/ml). Enzyme linked immunosorbent assay (ELISA) kit from Directorate of

FMD, India detected the presence of FMDV serotype O antigen in tongue epithelium sample.

Electrocardiography interpretation

Base apex lead of the ECG revealed sustained PVCs with tachycardia [heart rate (HR) =88/min] (Fig. 1). Ventricular premature complexes (VPCs) of two different kinds of morphology characterized by absence of "P" waves, bizarre "QRS" complex and abnormal "T" waves were observed.

Treatment and outcome

Supportive treatment consisting of Ampicillin-Cloxacillin combination antibiotic at dose of 10 mg/kg, intramuscular, twice a day and Flunixin Meglumine at dose of 2.2 mg/kg, slow intravenous, once a day was given for three days. The affected calf was isolated and managed by hand feeding with milk and gruel/porridge during acute phase of FMD. Mouth lesions are washed with 1% potassium permanganate solution and boroglycerine paste was applied. A significant clinical improvement was noticed by third day of post-treatment when rectal temperature returned to normal physiological range. Healing of oral lesions was noticed after 5 days of post-treatment.

Polymorphic ventricular premature complexes were treated by administering 2% lidocaine at dose of 0.6 mg/kg intravenously over 15 min once a day till the disappearance of arrhythmias. By 42 h of antiarrhythmic treatment, rhythm changed to intermittent unifocal VPCs occurring at the rate of 9-12 VPCs per min (Fig. 2). Sinus arrhythmia was observed after 76 h of

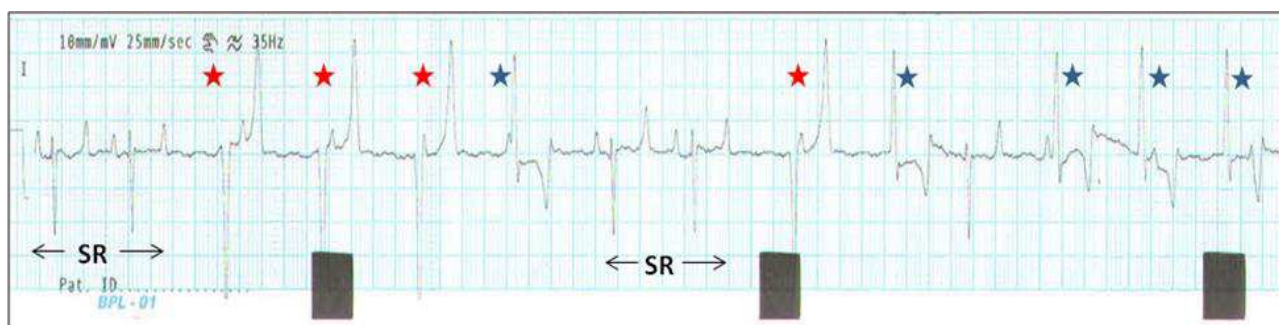


Fig. 1: Electrocardiogram showing multifocal ventricular premature complexes (VPCs of different morphology are indicated by asterisk marks of different color). SR: Sinus rhythm, lead: Base apex, paper speed: 25 mm/s, and sensitivity: 1 mV = 1 cm

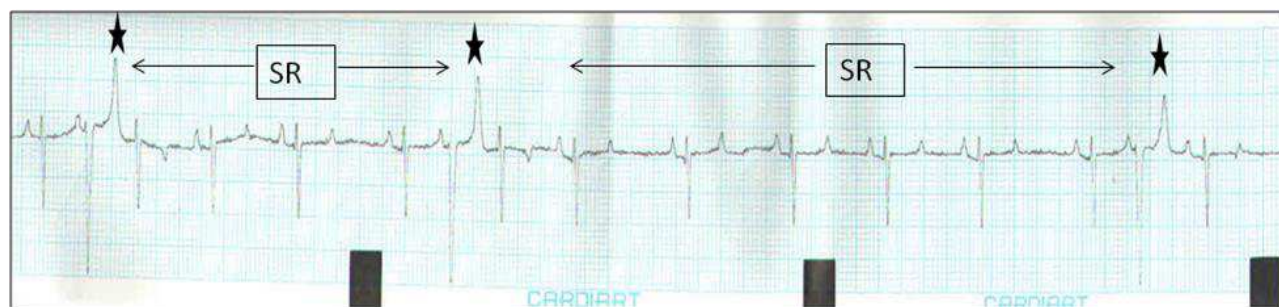


Fig. 2: Electrocardiogram after 42 h of treatment showing unifocal ventricular premature complexes (asterisk mark indicates VPCs). SR: Sinus rhythm, lead: Base apex, paper speed: 25 mm/s, and sensitivity: 1 mV = 1 cm

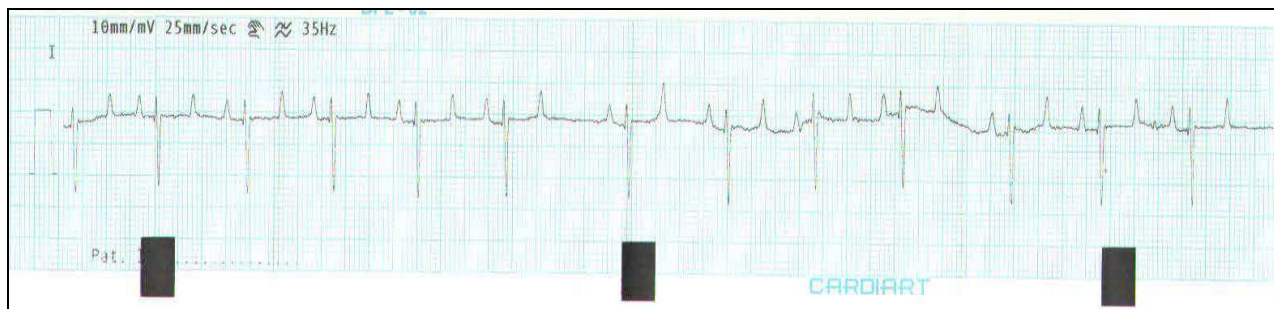


Fig. 3: Electrocardiogram after 76 h of treatment showing sinus arrhythmia. Lead: Base apex, paper speed: 25 mm/s, and sensitivity: 1 mV = 1 cm

antiarrhythmic treatment (Fig. 3). Tachycardia observed on day "0" of treatment (86/min) significantly reduced to normal reference range (62/min) by 42 h of treatment with lidocaine. Antiarrhythmic treatment was stopped by day 3 of treatment. Review ECG done on 7 and 14 days of treatment showed normal sinus rhythm.

Review of haematobiochemical examination was done on day 7 and day 10 of post-treatment. Levels of total leukocyte count (TLC), LDH, and AST have normalized by day 7 post-treatment. Concentrations of CK-MB and cTnI have been reduced to 39.08 U/L and 28.4 pg/ml, respectively by day 7 post-treatment. Normal reference values of CK-MB (21.04 U/L) and cTnI (19.3 pg/ml) in present case was observed by day 10 post-treatment.

Discussion

Foot and mouth disease virus is known to cause fatal myocarditis in young calves (Barker *et al.*, 1993). Affinity of FMDV to actively growing myocardial cells of suckling calves makes them susceptible for the development of myocarditis. Most of the time affected calves die suddenly without showing any clinical signs (Aktas *et al.*, 2015). Calves developing myocarditis will not usually show the typical clinical signs of FMD like oral or foot lesions (Aktas *et al.*, 2015; Sobhy *et al.*, 2018). Presence of both FMD specific oral lesions and cardiopulmonary signs in present case explains the expanded multi-tropism of FMD virus (Sobhy *et al.*, 2018). This is in agreement with Aktas *et al.* (2015) where they too observed the typical oral lesions of FMD in one calf developing myocarditis.

Occurrence of PVPCs in present case can be attributed to the underlying pathology of FMDV induced myocarditis. Ventricular arrhythmias like ventricular fibrillation and PVPCs are commonly associated with myocarditis (Radostits *et al.*, 2007; Aslani *et al.*, 2013). The development of focal areas of inflammation/fibrosis/hypertrophy consequent to viral myocarditis may slow down the action potential, ultimately leading to the formation of reentry circuits and ventricular arrhythmias (Baski *et al.*, 2015). Cytokines released in myocardium during inflammation are proarrhythmic and may invoke the occurrence of ventricular arrhythmias (Baski *et al.*, 2015). Presence of different shapes of VPCs in present case reflects the different foci of myocardial pathology

like inflammation/fibrosis etc. inducing contractions. Aslani *et al.* (2013) also noted the occurrence of PVPCs in lambs suffering from FMD-associated myocarditis. Elevated levels of CK-MB and cTnI before treatment in present case indicated the presence of myocardial injury. Creatine kinase myocardial band and cTnI are released into circulation as a response to myocardial damage and among these cTnI is a sensitive marker of myocardial damage as compared to CK-MB (Aktas *et al.*, 2015; El Beskawy *et al.*, 2016; Sobhy *et al.*, 2018).

Lidocaine is an antiarrhythmic agent of class 1b of Vaughan-William's classification (Radostits *et al.*, 2007). It exerts its mechanism of action by reducing the automaticity of heart by blocking sodium channels in the conduction system, as well as the Purkinje fibers of the heart (Sheu and Lederer, 1985). It also raises the depolarization threshold, making the heart less likely to initiate or conduct early action potentials that may cause an arrhythmia (Sheu and Lederer, 1985). Beneficial effects of lidocaine were observed in present case. After the initiation of antiarrhythmic treatment, PVPCs were converted to unifocal VPCs by 42 h of treatment and normal sinus rhythm was observed after 76 h of treatment. Outcome of the present case justifies the significance of using lidocaine as drug of choice in treating ventricular arrhythmias (Radostits *et al.*, 2007). Marked reduction in the levels of CK-MB and cTnI after 7 days of treatment correlates well with the ECG finding of normal sinus rhythm on 7th day of treatment. Flunixin Meglumine might have also contributed in the faster recovery of FMD induced myocarditis by reducing the production of inflammatory cytokines from the myocardium.

This case report describes the PVPCs associated with FMD and its successful treatment in calf. It is very common to find the sudden death of young calves without any premonitory signs during FMD outbreak in field conditions. Detailed cardiac investigation like cardiac auscultation, ECG recording and biomarker assay in young calves during FMD outbreak will depict the actual status of cardiac function in FMD affected calves. This in turn will help to initiate appropriate remedial measures and prevent the associated mortality.

Acknowledgements

Authors are thankful to In charge PME Cell, ICAR-

IVRI Bengaluru and Director, ICAR-IVRI for their support.

Conflict of interest

Authors do not have any conflict of interest.

References

- Aktas, MS; Ozkanlar, Y; Oruc, E; Sozdutmaz, I and Kirbas, A** (2015). Myocarditis associated with foot-and-mouth disease in suckling calves. *Vet. Arhiv.*, 85: 273-282.
- Alexandersen, S; Zhang, Z; Donaldson, AI and Garland, AJM** (2003). The pathogenesis and diagnosis of foot-and-mouth disease. *J. Comp. Pathol.*, 129: 1-36.
- Aslani, MR; Mohri, M and Movassaghi, AR** (2013). Serum troponin I as an indicator of myocarditis in lambs affected with foot and mouth disease. *Vet. Res. Forum.* 4: 59-62.
- Barker, IK; Van Dreumel, AA and Palmer, N** (1993). The alimentary system. In: Jubb, KVF; Kennedy, PC and Palmer, N (Eds.), *Pathology of domestic animals*. (4th Edn.), San Diego, CA, Academic Press. PP: 141-144.
- Baski, AJ; Kanaganayagam, GS and Prasad, SK** (2015). Arrhythmias in viral myocarditis and pericarditis. *Card. Electrophysiol. Clin.*, 7: 269-281.
- Brown, CC; Meyer, RF; Olander, HJ; House, C and Mebus, CA** (1992). A pathogenesis study of foot-and-mouth disease in cattle, using *in-situ* hybridization. *Can. J. Vet. Res.*, 56: 189-193.
- Deluigi, CC; Ong, P; Hill, S; Wagner, A; Kispert, E; Klingel, K; Kandolf, R; Sechtem, U and Mahrholdt, H** (2013). ECG findings in comparison to cardiovascular MR imaging in viral myocarditis. *Int. J. Cardiol.*, 165: 100-106.
- El Beskawy, MA; Farag, VM and Saad, MA** (2016). Epidemiological and clinicopathological studies of sheep naturally infected with foot and mouth disease virus (SAT2) in Egypt. *Alex. J. Vet. Sci.*, 49: 129-137.
- Kaya, A; Kozat, S; Ozkan, C; Yildirim, S; Akgul, Y and Akgul, O** (2013). Serum homocysteine levels in calves with foot and mouth disease. *J. Anim. Vet. Adv.*, 12: 1357-1361.
- Klein, RM; Vester, EG; Brehm, MU; Dees, H; Picard, F; Niederacher, D; Beckmann, MW and Strauer, BE** (2000). Inflammation of the myocardium as an arrhythmia trigger. *Z. Kardiol.*, 3: 24-35.
- Radostits, OM; Gay, CC; Hinchcliff, KW and Constable, PD** (2007). *Veterinary medicine. A textbook of the diseases of cattle, horses, sheep, pigs and goats*. 10th Edn., London, UK, W. B. Saunders. PP: 1223-1230.
- Sheu, SS and Lederer, WJ** (1985). Lidocaine's negative inotropic and antiarrhythmic actions. Dependence on shortening of action potential duration and reduction of intracellular sodium activity. *Circ. Res.*, 57: 578-590.
- Sobhy, NM; Yasmin, HB; Sunil, KM; El-Zahara, HI and Goyal, SM** (2018). Outbreaks of foot and mouth disease in Egypt: molecular epidemiology, evolution and cardiac biomarkers prognostic significance. *Int. J. Vet. Sci. Med.*, 6: 22-30.
- Ukena, C; Mahfoud, F; Kindermann, I; Kandolf, R; Kindermann, M and Bohm, M** (2011). Prognostic electrocardiographic parameters in patients with suspected myocarditis. *Eur. J. Hrt. Fail.*, 13: 398-405.