



**IJVR**

ISSN: 1728-1997 (Print)  
ISSN: 2252-0589 (Online)

**Vol. 20**

**No. 3**

**Ser. No. 68**

**2019**

# **IRANIAN JOURNAL OF VETERINARY RESEARCH**



## Scientific Report

# Esophagotomy in a domestic fowl: a rare case report

Ninu, A. R.<sup>1\*</sup>; Uma Rani, R.<sup>2</sup> and Vishnugurubaran, D.<sup>1</sup>

<sup>1</sup>Department of Veterinary Surgery and Radiology, Veterinary College and Research Institute, Tirunelveli, 627 358, Tamil Nadu Veterinary and Animal Sciences University (TANUVAS), Tamil Nadu, India; <sup>2</sup>Veterinary University Training and Diagnostic Centre, Madurai-625005, Tamil Nadu Veterinary and Animal Sciences University (TANUVAS), Tamil Nadu, India

\*Correspondence: A. R. Ninu, Department of Veterinary Surgery and Radiology, Veterinary College and Research Institute, Tirunelveli, 627 358, Tamil Nadu Veterinary and Animal Sciences University (TANUVAS), Tamil Nadu, India. E-mail: ar.ninu@gmail.com

(Received 9 Jun 2018; revised version 19 Dec 2018; accepted 16 Mar 2019)

## Abstract

**Background:** Foreign body in esophagus in birds is rarely reported in literature. Most common site of foreign body in birds is proventriculus and ventriculus. The purpose of this study is to discuss the diagnosis of a large sharp foreign body in the distal third of the neck by plain radiography and its retrieval through esophagotomy and subsequent survival of the fowl. **Case description:** An Aseel breed of domestic fowl (*Gallus domesticus*) was referred to the surgery department with a history of swelling in the neck and subsequent anorexia since 24 h, but normal water intake. Radiological examination revealed a large fish bone in esophagus. Because of the sharp edges of the foreign body esophagotomy was performed rather than per os (po) retrieval or milking of the foreign body into the crop and performing an ingluviotomy. **Findings/treatment and outcome:** Esophagotomy was performed under local infiltration using a diluted solution of lignocaine. Fish bone pieces were retrieved from the esophagus of the fowl. The esophagotomy incision was closed in two layers using polyglactin 910 no: 3-0. Postoperatively, the owner was advised to administer Enrofloxacin po at 10 mg/kg body weight (BW)/day for seven days and Tramadol (10 mg/kg BW, BID) for three days in water. This case was followed up for 8 months. There were no complications noticed by the owner. **Conclusion:** It could be concluded that prompt intervention and surgical management may be necessary for retrieval of sharp esophageal foreign bodies lodged in the distal cervical esophagus of domestic fowl.

**Key words:** Aseel, Domestic fowl, Esophagotomy, Foreign body

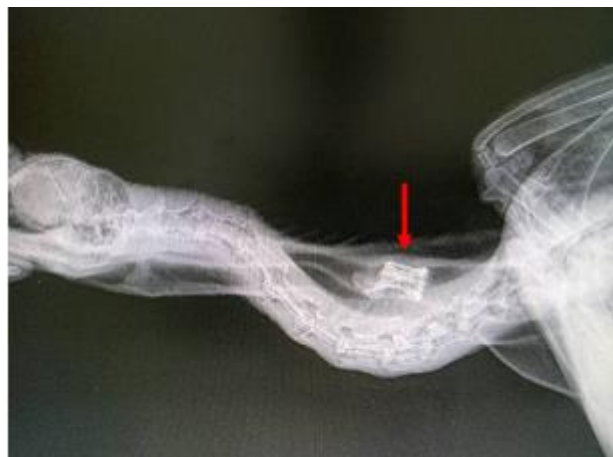## Introduction

Aseel is a breed of domestic fowl (*Gallus domesticus*) popular as a game bird and is of a high pet value among the local folks. The bird is used for cock fighting. In birds, the esophagus lies to the right of trachea and just below the skin. Avian esophagus is highly distensible due to the longitudinal folds that enable them to ingest large sized food materials (McLelland, 1975; Dyce *et al.*, 2002). This peculiarity may be the reason for the paucity of literature on esophageal foreign bodies in birds according to the author's opinion. Avian esophagus is divided into a cervical and a thoracic part. Crop is the expanded ventral diverticulum of the cervical esophagus in chicken. The wall of esophagus in birds has four layers, namely mucosa, submucosa, muscular tunic and serosa (Whittow, 1999). Esophageal foreign bodies are rarely reported in birds. Also, there is paucity of literature related to esophagotomy in birds. This case report discusses an unusually large sized sharp foreign body removed by esophagotomy from the distal part of cervical esophagus in a domestic fowl.

## Case description

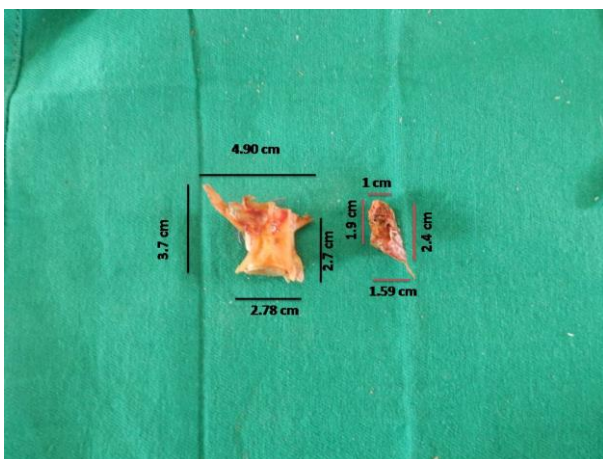
An Aseel breed of domestic fowl was referred to the

surgery department with a history of swelling in the neck and subsequent anorexia for 24 h but normal water intake. Clinical examination revealed the presence of an unusual swelling at the base of the neck. The swelling was hard and with sharp edges. Radiological examination revealed the presence of a large fish bone with sharp projections in the distal third of the neck (Fig. 1).



**Fig. 1:** Radio-opaque foreign body with sharp projections resembling fish bone (arrow) in the distal part of cervical esophagus

It was decided to perform esophagotomy under local infiltration analgesia using diluted 2% solution of lignocaine (Lox – 2%, Neon Laboratories Limited, Andheri East, Mumbai, India). Total dose should not exceed 4 mg/kg in birds (Hawkins, 2006). 1:3 dilution was prepared with normal saline and 1 ml was infiltrated along the proposed line of incision. The base of the neck was prepared aseptically for surgery. Using the index and thumb finger, the foreign body was held, and skin was incised. The esophagus over the foreign body obstruction was healthy. To prevent the spillage of the secretions, stay sutures were placed cranial and caudal to the incision site. Esophagotomy was performed just above the foreign body to remove one large fish bone and another small piece (Fig. 2). After removal of the bone pieces, the esophagus was empty except for viscous clear secretions. The site was lavaged with lukewarm sterile normal saline and suction of the fluid was done. The esophagotomy site was closed in two layers. First an interrupted pattern alone was performed but there was leakage and so a continuous pattern using polyglactin 910 no: 3-0 (Truglyde, Healthium Medtech Private Limited, Bangalore, India) was also done to prevent any leakage. Leakage was checked by giving water orally after the closure. The skin was closed in simple interrupted pattern using 3-0 polyamide (Trulon, Healthium Medtech Private Limited, Bangalore, India). Post-operative care advice included giving liquid diet alone for one week, antibiotics [Enrofloxacin (Meriquin, Vetoquinol India Animal Health Pvt Ltd., Maharashtra, India) at 10 mg/kg/day for 7 days] and analgesics [Tramadol (Anatrum, Hiral Labs Limited, Uttarakhand, India) at 10 mg/kg BID for 3 days] in water. In contrast to one week, the owner gave liquid diet alone for one month and normal feeding was resumed by second month. There were no complications during the follow up period of 8 months and the fowl was healthy.



**Fig. 2:** Fish bone pieces removed from esophagus of the fowl

## Discussion

Esophagotomy is rarely reported in birds as the foreign body mostly lodges in ventriculus or

proventriculus (Lloyd, 2009; Lupu and Robins, 2009; Hoefler and Levitan, 2013; Applegate *et al.*, 2017). A successful report of esophagotomy for esophageal impaction in goose suggested that per os (po) retrieval is the first consideration for an avian esophageal foreign body due to the distensible nature of esophagus. Second consideration for an esophageal foreign body is to lubricate the foreign body and to milk it into the crop and perform an ingluviotomy (Muscatella, 1998). In the present case, radiological examination revealed the presence of a radiopaque foreign body with sharp projections. Hence it was decided to perform an esophagotomy rather than squeezing the foreign body into the crop. The bird recovered uneventfully. This case was managed as per the opinion of Castaño-Jiménez *et al.* (2016). According to them, the management of foreign body in birds could be done variably on the basis of the clinical signs, the nature and location of the foreign body, available tools for manipulation of the foreign body, and the preference and experience of the surgeon. In this particular case, though the most indicated and preferred method was ingluviotomy after nudging the foreign body to the crop, the nature of the foreign body forced us to go for esophagotomy. Esophagus was sutured using appositional pattern. Simon and Pazhanivel (2017) used a single layer of interrupted sutures for suturing the esophageal wound. In the present case, in addition to the first layer of interrupted sutures, a second layer of continuous sutures was needed to prevent leakage. Kumar *et al.* (2016) reported esophageal anastomosis in a cock using simple continuous suture pattern. Carneiro *et al.* (2014) also reported esophageal defect closure after foreign body removal in penguins using simple continuous pattern. In this case, local analgesia was preferred over general anaesthesia by the anaesthesiologist after assessing the pain response and restraint characteristics of the fowl. Local infiltration analgesia alone was found to be adequate for performing amputation of extralimb in a 7 month old layer chicken by Abu-Seida (2014). Administration of local anaesthesia enabled assessing any leakage following the suturing of esophagus by oral administration of water. Diluted lignocaine was used in the study to prevent toxicity as the recommended dose of lignocaine in birds is below 4 mg/kg. But, this may vary with species. In chickens, there are reports on use of higher doses of lignocaine for the blockade of brachial plexus without any adverse reactions (Hawkins, 2006; Figueiredo *et al.*, 2008; Imani *et al.*, 2013). Esophagostomy tube placement is a recommended supportive care for sick birds which are unable to take feed and water orally or in cases where the food must bypass the mouth, esophagus or the crop (Huynh *et al.*, 2014). In the present case, the fowl was not reluctant to take water after removal of the foreign body. But, esophagostomy tube placement would have helped to bypass the esophageal lesion. However, the absence of any complications without the use of an esophagostomy tube may be due to liquid diet given to the bird, suture pattern used for the closure of the esophageal incision and an early intervention when the

esophageal mucosa was healthy.

## References

- Abu-Seida, AM** (2014). Amputation of polymelia in a layer chicken. *Avian Dis.*, 58: 330-332.
- Applegate, JR; Wettore, AV; Christiansen, EF and Degernes, LA** (2017). Management and case outcome of gastric impaction in raptors: a case series. *J. Avian Med. Surg.*, 31: 62-69.
- Carneiro, RL; Bonfada, AT; Carvalho, RDB and Nunes, N** (2014). Posterior esophagectomy removal of foreign body in 4 *Magellanic penguins* (*Spheniscus magellanicus*) found off the coast of the state of Bahia, Brazil. *JLAVECC.*, 6: 18-25.
- Castañó-Jiménez, PA; Trent, AM and Bueno, I** (2016). Surgical removal of a ventricular foreign body in a captive African black-footed Penguin (*Spheniscus demersus*). *J. Avian Med. Surg.*, 30: 46-52.
- Dyce, KM; Sack, WO and Wensing, CJG** (2002). *Textbook of veterinary anatomy*. 3rd Edn., Philadelphia, Pennsylvania, Saunders. PP: 799-824.
- Figueiredo, JP; Cruz, M; Mendes, GM; Marucio, RL; Ricco, CH and Campagnol, D** (2008). Assessment of brachial plexus blockade in chickens by an axillary approach. *Vet. Anaesth. Analg.*, 35: 511-518.
- Hawkins, M** (2006). The use of analgesics in birds, reptiles and small exotic mammals. *J. Exot. Pet. Med.*, 15: 177-192.
- Hofer, H and Levitan, D** (2013). Perforating foreign body in the ventriculus of an umbrella cockatoo (*Cacatua alba*). *J. Avian Med. Surg.*, 27: 128-135.
- Huynh, M; Sabater, M; Brandão, J and Forbes, NA** (2014). Use of an esophagostomy tube as a method of nutritional management in raptors: a case series. *J. Avian Med. Surg.*, 28: 24-30.
- Imani, H; Vesal, N and Mohammadi-Samani, S** (2013). Evaluation of intravenous lidocaine overdose in chickens (*Gallus domesticus*). *IJVS.*, 8: 9-16.
- Kumar, PR; Prasad, VD; Sailaja, B and Raju, DB** (2016). Surgical repair of oesophageal rupture in a cock (*Gallus domesticus*). *J. Livest. Sci.*, 7: 238-240.
- Lloyd, C** (2009). Staged endoscopic ventricular foreign body removal in a Gyr Falcon (*Falco rusticolus*). *J. Avian Med. Surg.*, 23: 314-319.
- Lupu, C and Robins, S** (2009). Comparison of treatment protocols for removing metallic foreign objects from the ventriculus of Budgerigars (*Melopsittacus undulatus*). *J. Avian Med. Surg.*, 23: 186-193.
- McLelland, J** (1975). Aves. Digestive system. In: Sisson, S; Grossman, JD and Getty, R (Eds.), *Sisson and Grossman's the anatomy of the domestic animals*. (5th Edn.), New Delhi, India, Rekha Printers Pvt. Ltd., PP: 1857-1882.
- Muscattella, G** (1998). Esophageal impaction in a Canada goose. *Aust. Vet. J.*, 76: 537-560.
- Simon, SM and Pazhanivel, N** (2017). Oesophageal foreign body (*Bambusa vulgaris*) in an emu. *Indian Vet. J.*, 94: 80-81.
- Whittow, GC** (1999). *Sturkie's avian physiology*. 5th Edn., San Diego, USA, Elsevier. PP: 299-326.