

Clinical studies on progressive retinal atrophy in 31 dogs

Kelawala, D. N.¹; Patil, D. B.^{2*}; Parikh, P. V.²; Sheth, M. J.³;
Joshi, C. G.⁴ and Reddy, B.⁴

¹Ph.D. Scholar in Veterinary Surgery and Radiology, Department of Veterinary Surgery and Radiology, College of Veterinary Science and Animal Husbandry, Anand Agricultural University, Anand, Gujarat-388001, India; ²Department of Veterinary Surgery and Radiology, College of Veterinary Science and Animal Husbandry, Anand Agricultural University, Anand, Gujarat-388001, India; ³Consultant Vitreoretinal Surgeon, Govind Eye Clinic, Vadodara, India; ⁴Department of Animal Biotechnology, College of Veterinary Science and Animal Husbandry, Anand Agricultural University, Anand, Gujarat-388001, India

*Correspondence: D. B. Patil, Directorate of Research, Kamdhenu University, Karmayogi Bhavan, Block-1, Wing B-1, 3rd Floor, Sector 10-A, Gandhinagar, Gujarat-382010, India. E-mail: db1608@gmail.com

(Received 8 Jun 2016; revised version 22 Nov 2016; accepted 10 Dec 2016)

Summary

During a 2-year period, 31 cases of a hereditary retinal degeneration in dogs bred in India were found mainly suspected for progressive retinal atrophy (PRA) with typical history of initial nyctalopia followed by hemeralopia. Out of 31 PRA suspected dogs, 8 dogs (26%) were from the age group of 1-5 years, 15 (48%) 6-10 years and the rest (26%) 11-15 years. The most predominant breed was Spitz (18 dogs, 58%). Detailed ophthalmologic examinations included Schirmer's tear test, fluorescein stain, applanation tonometry, slit lamp biomicroscopy and ocular ultrasound in appropriate cases. Ophthalmoscopic and fundoscopic changes included hyperreflectivity and discoloration of the tapetal area, marked attenuation of retinal vessels, depigmentation in non-tapetal area and optic disc atrophy with scalloped borders. Electroretinograms (ERG) recorded in 13 PRA-affected cases revealed non-recordable extinguished (flatline) ERG responses. A reduction mainly of a- and b-wave amplitudes in the ERG indicated a generalized photoreceptor disease.

Key words: Dog, Electroretinography, Funduscopy, Progressive retinal atrophy

Introduction

Progressive retinal atrophy (PRA) is the umbrella term used to describe a number of inherited neuroretinal degenerations and shows genetic heterogeneity (Bedford, 2006), caused by several mutations and affects more than 100 dog breeds (Haim *et al.*, 1992; Petersen-Jones, 1998).

Progressive retinal atrophy is a comprehensive term for several different types of hereditary defects primarily affecting the photoreceptors. In the majority of forms the rod photoreceptors are initially affected, leading to loss of night-vision. As the disease progresses cone vision deteriorates as well, resulting in impairment of vision in daylight and eventually complete blindness (Narfstrom and Petersen-Jones, 2013). The disease causes great deal of discomfort in the breeding industry as well as to the owners as the disease is incurable (Millichamp, 1990).

In some instances, more than one form of PRA may be segregating within the same breed (Downs *et al.*, 2011). Many of the canine PRAs are autosomal recessively inherited, but X-linked forms and one autosomal dominant form have also been reported. At least 24 mutations in 18 genes have been associated with canine retinal disease (Miyadera *et al.*, 2012a). Typically, the association between the gene mutation and the development of PRA is straightforward, with most being fully penetrant, although occasionally the situation may appear to be more complex (Miyadera *et al.*, 2012b).

The diagnosis is based on clinical history, ophthalmologic and complementary examination such as funduscopy, electroretinography (ERGy) and genetic testing (Gomes *et al.*, 2013). The clinical characterization of specific forms of PRA is important to obtain reliable models for translational research. This report describes the features of retinal atrophy in 31 dogs bred in India.

Materials and Methods

The study was performed with the approval of Institutional Animal Ethics Committee (permission letter: AAU/GVC/CPCSEA-IAEC/108/2013). In a span of 2 years, 340 clinical cases of dogs underwent detailed ophthalmic examination for various ocular abnormalities which included complete history pertaining to visual abnormality and clinical assessment of visual functions by menace response and reflexes like, pupillary light, 4th purkinje and tapetal, different tests like fluorescein staining, Schirmer's tear test, tonometry, complete ophthalmic examination with hand-held slit-lamp biomicroscope and binocular indirect ophthalmoscope and B-mode ultrasonographic examination in appropriate cases to rule out posterior segment abnormality.

Additionally, visual performance was assessed by distribution of a short questionnaire among owners of PRA-affected dogs regarding owner's perception of the onset and severity of visual deficits observed in the dogs,

such as the ability to see stationary or moving objects under different light conditions and negotiating staircase in dark conditions.

All ocular abnormalities were documented and in many cases retinal photographs were taken with a hand-held fundus camera (Smartscope VET2: Optomed, Finland). Prior to funduscopy recording, the dog's pupils were dilated with a short-acting mydriatic 1% tropicamide, 30 min prior to examination and after proper focusing of the camera, image of the posterior segment was taken using ophthalmoscopic fundus imaging camera in a dark room. For each dog, tapetal and non-tapetal colour, tapetal reflectivity, shape of tapetal and non-tapetal area, homogeneity of tapetum and non-tapetal, the junction of the tapetal and non-tapetal border and location, colour, shape, border and degree of myelination of optic disc were evaluated.

Electroretinograms (ERG) were recorded in 13 PRA-affected cases under general anaesthesia by conventional table top ERG unit (RETIport ERG and VEP: S&V Technologies AG, Acrivet Veterinary Division, Germany) with an automated protocol. Before performing ERG dogs were fasted for at least 12 h. The pupils were dilated using 1% tropicamide. The electrodiagnosis of retina for confirmation of PRA was performed under general anaesthesia using a mixture of Ketamine HCl (50 mg/ml) and Midazolam (10 mg/ml) in the ratio 2:1 IV for induction along with Atropine Sulphate® 0.03 mg/kg SC as premedicant. Positioning of patient and electrodes for ERG readings was adopted from Narfström *et al.* (2002) (Figs. 1a, b). Phot.Scot. LED programme was selected in the RETIport ERG system for a quick ERG recording and the photopic and scotopic retinal function was tested with a standard flash (3 cds/m²). ERG were recorded automatically and the a- and b- wave amplitudes (μ V), and implicit times (ms) were auto generated using the dog diagnostic protocol pre-programmed for the equipment which came from the manufacturer that way.

After the preliminary preparations, all the dogs were subjected to dark adaption for a minimum of 20 min. Later the rod function was tested (scotopic ERG) initially for the right eye followed by left eye. Following scotopic ERG of both eyes the dogs were subjected to light adaptation for a minimum of 10 min. Cone function was tested (photopic ERG) in similar pattern. The a-wave amplitude was measured from the baseline to the a-wave trough, and the b-wave amplitude was measured from the a-wave trough to the b-wave peak. Then b/a ratios of amplitude were calculated. The a- and b- wave implicit times were measured from the stimulus onset to the a-wave trough and b-wave peak, respectively.

Results

During the study period, out of 31 cases of PRA in dogs bred in India, 18 dogs (58%) were male and 13 (42%) female, with age varying from 2 to 13 years, of which eight (26%) were from the age group 1-5 years, 15 (48%) between 6-10 years and the rest (26%) 11-15

years. The most predominant breed was Spitz (18, 58%) followed by Labrador Retriever (8, 26%), Cocker Spaniel (2, 7%), Canadian Pointer, Lhasa Apscho and German Shepherd (1 each, 3%).

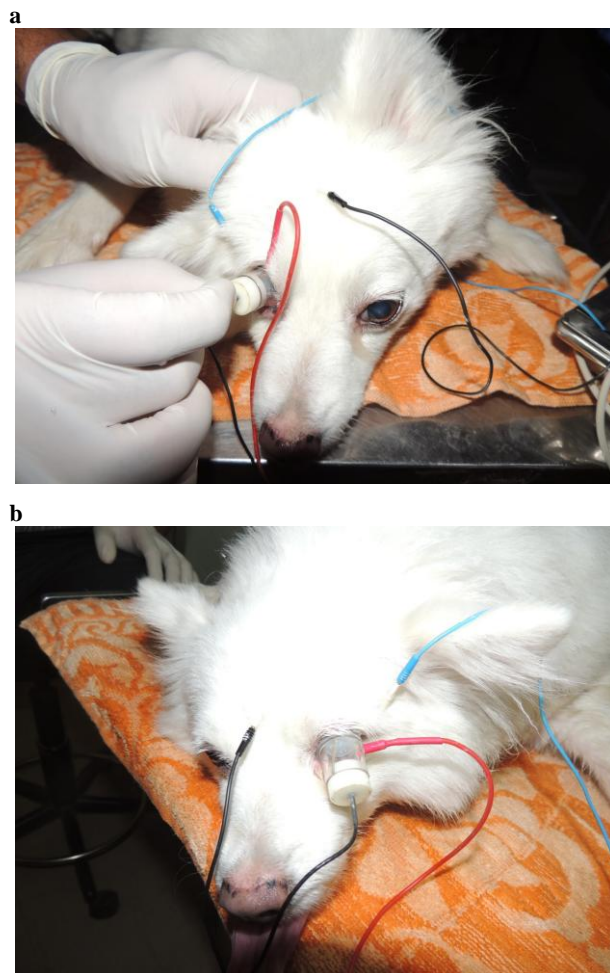


Fig. 1: Placement of electrode in dogs for ERG (a and b)

Most of the dogs were presented with initial signs of nyctalopia, followed by a progressive hemeralopia until the affected animal is totally blind. The age at onset of nyctalopia and the rate of progression of vision loss varied widely. When examined almost all the dog (n=27, 87%) had difficulty in avoiding objects in dim light, dilated pupils with slow pupillary light responses and characteristic shine from the eye (tapetal hyper reflectivity).

In normal dogs, the ophthalmoscopic and fundoscopic examinations showed normal reflectivity of the tapetal region, normal vascular size and normal coloration of the tapetal fundus (Figs. 2a, b). Ophthalmoscopy in dogs with PRA showed bilateral and generalized changes. Only subtle color changes were noted in the central parts of the ocular fundi, but in the peripheral parts there were signs of choroidal spoking and slight hyper-reflectivity. Lesions of the fundus were variable and at early stages (n=13), focal or multifocal hyperreflective lesions of the tapetum associated with thinning of the retina, with an inconsistent symmetry

were frequently observed but the hyperreflective band surrounding the tapetal–non-tapetal junction was rare and blood vessels were not completely attenuated (Figs. 3a, b) but narrowed away from the disc; while at advanced stages (n=15), generalized hyperreflexion coexisted either with hyperreflective coalescent foci in the tapetum, and only ghost vessels are visible with pallor of disc and hypopigmentation of nontapetum area (Figs. 4a, b). Fundoscopy revealed shrinking of the blood vessels, decreased pigmentation of the non-tapetal fundus, increased reflection from the tapetum and atrophied optic disc with scalloped borders. There was a generalized but mild vascular attenuation with decrease in number and size of retinal vessels and pigmentary changes along with circular and atrophied optic disc with scalloped or indistinct borders and early loss of myelin over the optic nerve head. Fundus changes were not detected in any of the examined dogs below 4 years of age (n=3) though the owners had complaints regarding their dog showing signs of fear in dark.

Electroretinography was carried out as a complementary examination in 13 dogs. Initial light-adapted ERG resulted in a photopic b-wave with somewhat reduced amplitude compared to ERGs during dark adaptation which did not show any recordable responses.

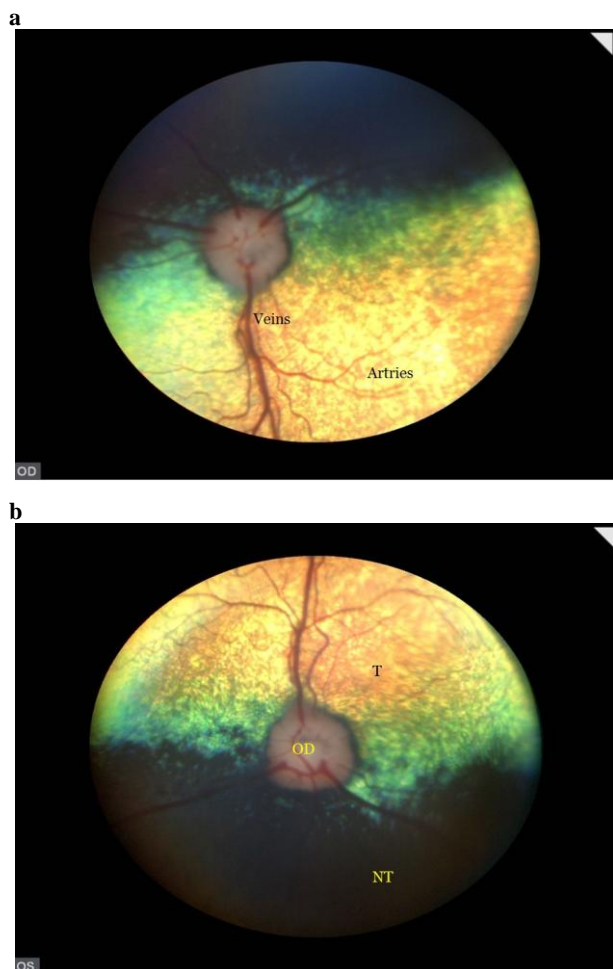

Fig. 2: Normal fundus images for a Spitz dog, 6 years (a and b). OD: Optic disc, T: Tapetum, and NT: Non tapetum

However, the amplitude of the b-wave was significantly decreased at all light intensities in the PRA cases. The a-wave amplitude was also significantly lower at all light intensities for PRA-affected dogs. At the advanced stage of disease, there were non-recordable extinguished (flatline) ERG responses for the scotopic and photopic ERGs (Fig. 5). Dogs showing apparent fear in dark (n=4) had reduced ERG amplitudes but a normal fundus appearance. The ERG recorded from the PRA-affected dogs was characterized by a- and b-waves of very low amplitudes. The mean±SE of b/a ratio for PRA dogs was 3.92 ± 0.77 .

Exon capture and sequence analysis of PRA-affected and normal dogs revealed 25657 single nucleotide polymorphisms (SNPs) in total. The case control analysis revealed mutations associated with PRA-affected and normal dogs. Five mutations [chr 7: 19509452 (T/A), chr 7: 19509598 (A/G), chr 7: 19510446 (C/T), chr 7: 19510503 (G/A), and chr 7: 19509281 (G/T)] in Phosducin (PDC) showed significant association with PRA in Spitz breed. Pathogenetically relevant mutations were not found in Rhodopsin (RHO) for PRA in canine breeds studied. Mutations in PRCD, XLPR1 and 2, CNBG and GALK1 were not linked to PRA-affected Spitzs. Mutation in PRCD was linked to PRA-affected Labrador Retriever (n=8) and Cocker Spaniel (n=2).

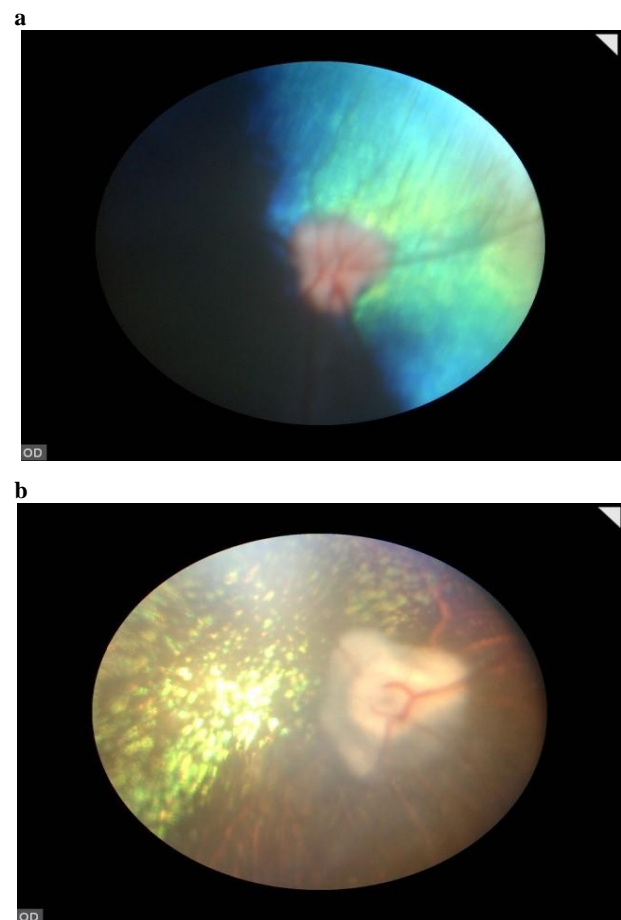


Fig. 3: Early progressive retinal atrophy (a and b). Here blood vessels were not completely attenuated, but narrowed away from the disc. Hyperreflectivity of tapetum

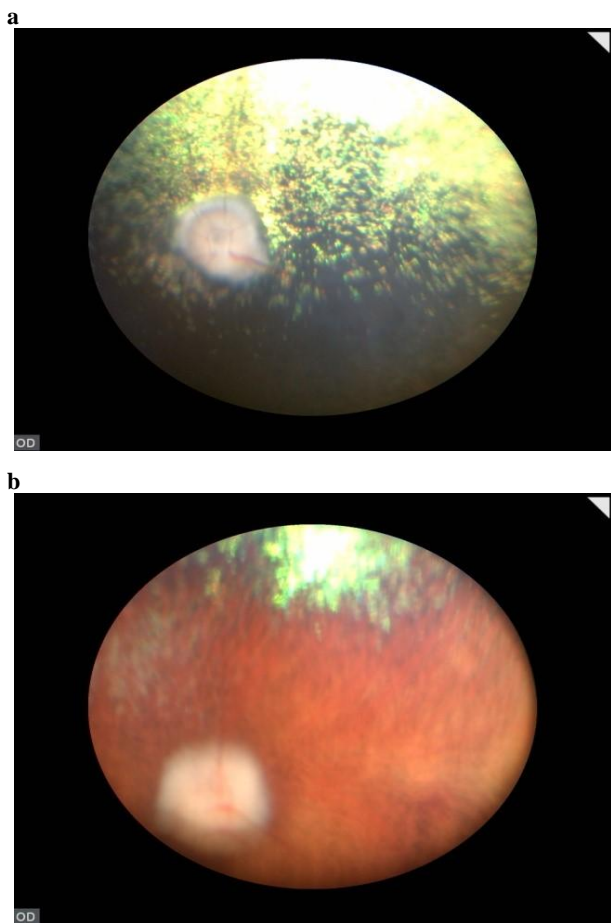


Fig. 4: An advanced case of retinal degeneration (a and b). The tapetal fundus is hyperreflective, and only ghost vessels are visible

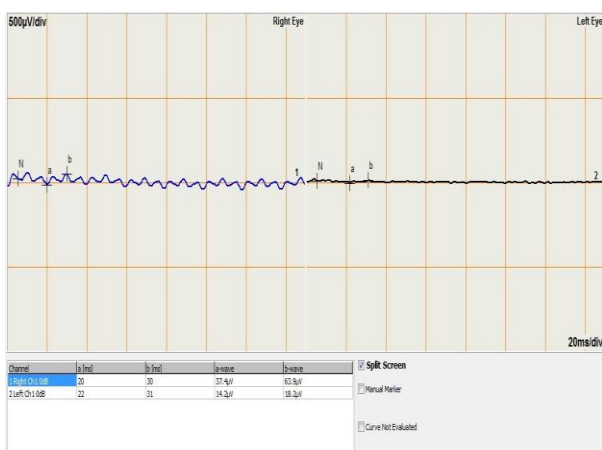


Fig. 5: Flatline electroretinogram of a PRA dog. The amplitude of the b-wave was significantly decreased at all light intensities in the PRA cases. The a-wave amplitude was also significantly lower at all light intensities for PRA-affected dogs. Non-recordable extinguished (flatline) ERG responses for the scotopic and photopic ERGs

Discussion

Inherited retinal diseases are among the leading causes for incurable vision loss in the human and canine

populations. In dogs, most of these conditions are classified as PRA, and, similar to many forms of retinitis pigmentosa (RP) in human patients, primarily affect rod photoreceptors leading to initial night-vision loss followed by loss of cone photoreceptors and subsequent day-blindness, culminating in complete blindness (Clements *et al.*, 1996; Miyadera *et al.*, 2012a). All the 31 affected dogs described in the present report showed no obvious visual impairment except nyctalopia at initial stage which gradually progresses to day-blindness in a few months to years resulting in complete blindness and there were only minor ophthalmoscopic signs of generalized retinal disease. Dogs of both genders, 18 males and 13 females were affected by PRA, which makes it unlikely that the condition is sex-linked.

The ophthalmoscopic signs are similar for each type of PRA, but the aetiologies vary considerably (Bedford, 2006). Although ophthalmoscopic findings at various stages of PRA were rather similar, the variation in age of onset of disease in a few dogs was remarkable. Through the genealogy of the affected dogs, it was found that certain families were affected early with a more rapid progression of disease, compared to other dogs that developed PRA at a later time. Progressive retinal atrophy in Spitz is late onset form and is diagnosed in middle-aged dogs. A possible explanation of this deviation may be a genetic variation due to inbreeding. Furthermore, age of disease onset and rate of disease progression can vary considerably, even in closely related animals and the novelty of this disease is not only based on the retinal disease phenotype, but also the variation in age of onset and rate of disease progression (Cooper *et al.*, 2014).

The disease is characterized by progressive attenuation and thinning of retinal blood vessels. As the disease progresses the arteries decrease in number and the large veins become noticeably thinner. The optic disc becomes pale to gray brown owing to loss of capillaries on its surface and demyelination and atrophy of the nerve fibers caused by extensive degeneration of the retina (Maggs, 2013). The most obvious and consistent finding in affected dogs is a greyish discoloration of the peripheral tapetal fundus that slowly spreads toward the central part of the tapetal area. Funduscopy revealed typical signs of PRA. It included change in tapetal reflectivity, i.e. tapetum showed focal or multifocal areas of hyper reflectivity in early stages and progressed to diffused hyperreflectivity in advanced stage.

The established b/a ratio at intensity of 3 cds.s/m² in healthy Spitz dog is 2.33 ± 0.73 (Kelawala, 2014). Electroretinograms indicated severe functional deficits in all the 13 dogs. Electroretinograms responses in the PRA-affected dogs tested were non-recordable extinguished (flatline) for all levels of light stimuli used in the dark and light adapted states. The flatline responses documented in dogs with PRA confirmed a loss of retinal function of the eyes, while an increased b/a ratio (3.92 ± 0.77) could point towards an affection of the outer retinal layers. Mean peak to peak amplitudes seemed to be smaller for each dog. The severely reduced

single flash and flicker responses of the PRA-affected English springer spaniel dog indicate a photoreceptor disorder with severe effects on cones and inner retina (Narfstrom *et al.*, 2006). Electroretinograms recordings of PRA-affected Miniature Schnauzer tested, all ERG responses were non-recordable in all of the PRA-affected dogs for all light intensities used (Jeong *et al.*, 2013). The ERG examination revealed reduced rod responses during dark adaptation, and the scotopic mixed rod-cone responses and cone only responses were slightly reduced. Reduced rod function, detected by ERG, is present before fundus changes develop (Svensson *et al.*, 2015). In the present study dogs below 4 years of age (n=3) had reduced ERG amplitudes but a normal fundus appearance. Consistent reduction of rod function is the first detected ERG abnormality. This suggests that visual testing procedures routinely used in dogs are crude and not always reliable, and indicates the necessity of more objective testing methods, such as ERG.

Molecular, biological and genetic data which allow the gene responsible to be identified greatly facilitate early detection of affected and carrier dogs. In the present study, five mutations involving PDC responsible for PRA in Spitz is reported (Reddy *et al.*, 2015). Thus, PRA represents an expanding clinical spectrum and it is important to recognise and describe new forms since much may be learned regarding retinal biology from the study of its disease.

Acknowledgements

We are grateful to the owners of the dogs for their willingness and permission for conducting funduscopy and electroretinography and even for the blood samples. This work was supported by grants from the Department of Biotechnology (DBT), Govt. of India.

Conflict of interest

The authors declare that they have no conflicts of interest.

References

- Bedford, P** (2006). Hereditary retinal diseases. World Congress WSAVA/FECAVA/CSAVA. PP: 609-610.
- Clements, PJM; Sargan, DR; Gould, DJ and Petersen-Jones, SM** (1996). Recent advances in understanding the spectrum of canine generalised progressive retinal atrophy. *J. Small Ani. Prac.*, 37: 155-162.
- Cooper, AE; Ahonen, S; Rowlan, JS; Duncan, A; Seppala, EH; Vanhapelto, P; Lohi, H and Komaromy, AM** (2014). A novel form of progressive retinal atrophy in Swedish Vallhund dogs. *PLoS One*. 9: 1-10.
- Downs, LM; Wallin-Hakansson, B; Boursnell, M; Marklund, S; Hedhammar, Å; Truvé, K; Hübinette, L; Lindblad-Toh, K; Bergström, T and Mellersh, CS** (2011). A frameshift mutation in golden retriever dogs with progressive retinal atrophy endorses SLC4A3 as a candidate gene for human retinal degenerations. *PLoS One*. 6: e21452.
- Gomes, D; Otsuki, DA; Lisaki, R; Angélica De Mendonça and Safatle, V** (2013). Generalized progressive retinal atrophy in Cocker Spaniel dogs. *Cienc. Rural*. 43: 1405-1414.
- Haim, M; Holm, NV and Rosenberg, T** (1992). Prevalence of retinitis pigmentosa and allied disorders in Denmark. I Main results. *Acta Ophthalmol.*, 70: 178-186.
- Jeong, MB; Shin, AP; Kim, SE; Park, YW; Narfström, K and Seo, K** (2013). Clinical and electroretinographic findings of progressive retinal atrophy in miniature Schnauzer dogs of South Korea. *J. Vet. Med. Sci.*, 75: 1303-1308.
- Kelawala, DN** (2014). Studies on electroretinography using RETIport ERG system in canines. M.V.Sc. thesis submitted to Anand Agricultural University, Anand, Gujarat-388110, India. P: 68.
- Maggs, DJ** (2013). Basic diagnostic techniques. In: Maggs, DJ; Miller, P and Ofri, R (Eds.), *Slatter's fundamentals of veterinary ophthalmology*. (5th Edn.), Philadelphia, Saunders. PP: 1-12.
- Millichamp, J** (1990). Retinal degeneration in the dog and cat. *Vet. Clinics North America: Small Ani. Prac.*, 20: 799-835.
- Miyadera, K; Acland, GM and Aguirre, GD** (2012a). Genetic and phenotypic variations of inherited retinal diseases in dogs: the power of within- and across-breed studies. *Mamm. Genome*. 23: 40-61.
- Miyadera, K; Kato, K; Boursnell, M; Mellersh, CS and Sargan, DR** (2012b). Genome-wide association study in RPGRIP-/- dogs identifies a modifier locus that determines the onset of retinal degeneration. *Mamm. Genome*. 23: 212-223.
- Narfström, K; Ekesten, B; Rosolen, SG; Spiess, BM; Percicot, CL and Ofri, R** (2002). Guidelines for clinical electroretinography in the dog. *Doc. Ophthalmol.*, 105: 83-92.
- Narfstrom, K; Galle, L; Dubielzig, R and Katz, M** (2006). Screening for late on-set progressive retinal atrophy in the English springer spaniel dog using a portable ERG unit and an automated protocol. International Society for Clinical Electrophysiology of Vision (ISCEV), 44th Annual Symposium, Fontevraud Abbey, France, Abstract S2-20, June, 2006.
- Narfstrom, K and Petersen-Jones, S** (2013). Diseases of the canine ocular fundus. In: Gelatt, KN; Gilger, BC and Kern, TJ (Eds.), *Veterinary ophthalmology*. (5th Edn.), Ames, Wiley-Blackwell. PP: 1303-1392.
- Petersen-Jones, SM** (1998). A review of research to elucidate the causes of the generalised progressive retinal atrophies. *Vet. J.*, 155: 5-18.
- Reddy, B; Kelawala, DN; Shah, T; Patel, AB; Patil, DB; Parikh, PV; Patel, N; Parmar, N; Mohapatra, AB; Singh, KM; Menon, R; Pandya, D; Jakhesara, SJ; Koringa, PG; Rao, MV and JOSHI, CG** (2015). Identification of putative SNPs in progressive retinal atrophy affected *Canis lupus familiaris* using exome sequencing. *Mamm. Genome*. 26: 638-649.
- Svensson, M; Olsen, L; Winkler, PA; Petersen-Jones, SM; Bergstrom, T; Garncarz, Y and Narfstrom, K** (2015). Progressive retinal atrophy in the Polski Owczarek Nizinny dog: a clinical and genetic study. *Vet. Ophthalmol.*, 19: 195-205.