



IJVR

ISSN: 1728-1997 (Print)
ISSN: 2252-0589 (Online)

Vol. 24

No. 4

Ser. No. 85

2023

**IRANIAN
JOURNAL
OF
VETERINARY
RESEARCH**



Original Article

Sarcocystosis among buffaloes from slaughterhouses in Nile Delta, Egypt: morphologic assessment and molecular confirmation

El-Sayad, M.¹; El-Taweel, H.¹; Ahmed, A.² and Abd El-Latif, N.^{1*}

¹Department of Parasitology, Medical Research Institute, University of Alexandria, Alexandria, Egypt; ²Department of Biomedical Informatics & Medical Statistics, Medical Research Institute, University of Alexandria, Alexandria, Egypt

*Correspondence: N. Abd El-Latif, Department of Parasitology, Medical Research Institute, University of Alexandria, Alexandria, Egypt. E-mail: dr_naglaafathi@alexu.edu.eg

 10.22099/IJVR.2023.48129.7006

(Received 19 Aug 2023; revised version 15 Dec 2023; accepted 31 Dec 2023)

This is an open access article under the CC BY-NC-ND license (<http://creativecommons.org/licenses/by-nc-nd/4.0/>)

Abstract

Background: *Sarcocystis* species are coccidian protozoan zoonotic parasites of the phylum Apicomplexa. There is a large diversity of *Sarcocystis* species. Some of them are pathogenic and dangerous to humans, domestic, and wild animals. Cattle are common intermediate hosts. The infection of meat with different species of *Sarcocystis* can be serious for public health. **Aims:** The current study aimed to determine the prevalence of sarcocystosis in slaughtered buffaloes in Tanta city abattoirs, Nile Delta, Egypt. **Methods:** Morphological and histological examinations and a molecular study were undertaken. A total of 517 locally bred buffaloes were slaughtered in Tanta city, Egypt. Each buffalo carcass was visually inspected for the presence of *Sarcocystis* macrocysts. Fifty tissue samples containing suspected cysts were examined by using different techniques including histology, transmission electron microscope (TEM), and PCR. **Results:** By visual inspection, the overall prevalence of suspected sarcocystosis was 26.5%. The highest infection rate was detected visually from the esophagus followed by skeletal muscles and diaphragm whereas the least was recorded in the tongue. Histological and TEM examination showed that the cysts were packed with bradyzoites separated by multiple septa. 100% of the sarcocysts diagnosed visually in the esophagus and muscles were confirmed by PCR, compared to only 25% of those detected in the tongue. **Conclusion:** These results highlight the high prevalence of sarcocystosis among buffaloes in Egypt, possibly due to widespread environmental contamination by *Sarcocystis* oocysts. The use of molecular methods should be encouraged to confirm the identity of the suspected cysts.

Key words: Buffaloes, Egypt, Molecular, *Sarcocystis* spp., Ultrastructure

Introduction

Sarcocystis spp. is an intracellular zoonotic protozoan parasite belonging to the phylum Apicomplexa. There is a great *Sarcocystis* spp. diversity and over 220 species are widely distributed in man and many species of animals (Dubey *et al.*, 2015a).

Sarcocystis spp. are cyst-forming sporozoan parasites with a complex obligatory heteroxenous cycle, involving a carnivore as a definitive host and a herbivore or an omnivore as an intermediate host. Cyst formation takes place in the intermediate hosts whereas sexual development gametogony and sporogony with oocyst formation take place in the definitive host (Dubey *et al.*, 2015a). *Sarcocystis* spp. oocysts are passed and remain infective in the feces of the definitive host for two years. Intermediate hosts are mainly infected through ingestion of sporocysts (Savini *et al.*, 1992). Vertical transmission

was reported experimentally (Marques *et al.*, 2018) and sporadically though rarely in natural infections (Moré *et al.*, 2011).

Some species of *Sarcocystis* spp. sporocysts are pathogenic and dangerous to humans and domestic and wild animals. Pathogenicity depends on the species, intensity of infection, and localization in the body (Fayer, 2004). Pathogenic *Sarcocystis* spp. cause disease mainly in their intermediate, not in their definitive hosts (Tenter, 1995). *Sarcocystis hominis*, *Sarcocystis cruzi*, and *Sarcocystis hirsuta* are the main species infecting cattle whereas water buffaloes are intermediate hosts for *Sarcocystis fusiformis*, *Sarcocystis levinei*, *Sarcocystis dubeyi*, *Sarcocystis sinensis*, and *Sarcocystis buffalonis* (Lindsay and Dubey, 2020). Classification of *Sarcocystis* species is based on the shape and thickness of the cyst wall (Choi *et al.*, 2018). *Sarcocystis* spp. infect skeletal cardiac, and smooth muscles of cattle (Koudela and

Modrý, 2000; Fayer *et al.*, 2004; Hu *et al.*, 2011). The prevalence of sarcocystosis in adult bovine muscles may reach 70-100%, in many regions of the world (Choi *et al.*, 2018; Ayazian *et al.*, 2020). They may cause abortion in the acute form of sarcocystosis, while in chronic infection they may cause a decrease in weight gain, the reduction of wool quality, the low production of milk, and ultimately the death of animals. The losses caused by discarding the infected carcasses represent a serious economic problem (Tenter, 1995; Dubey *et al.*, 2015a). Sarcocysts may also infect humans who become final hosts after eating infected raw or undercooked beef and pork (Fayer, 2004; Slesak *et al.*, 2015; Dubey, 2015). *Sarcocystis hominis*, *Sarcocystis heydorni*, and *Sarcocystis sui hominis* whose intermediate hosts are cattle, pigs, or wild boars, may elicit gastroenteritis in humans (Prakas and Butkauskas, 2012; Lindsay and Dubey, 2020). The cases of muscular sarcocystosis in which humans act as accidental intermediate hosts are rarely recorded (Fayer, 2004).

As the infection of meat with different species of *Sarcocystis* can be serious for public health, the identification and differentiation of *Sarcocystis* spp. are very important (Hoeve-Bakker *et al.*, 2019; Ayazian *et al.*, 2020). The current study aimed to detect and determine the prevalence of *Sarcocystis* spp. in slaughtered buffaloes in the Tanta city abattoir, Egypt. Morphological, histological as well as molecular studies were undertaken.

Materials and Methods

Ethics statement

The study was approved by the Research Ethics Committee of the Medical Research Institute (MRI), Alexandria University (AU 01219091512). All samples used in the study were collected postmortem. No animal was killed for the purpose of the study.

The study included 517 locally bred buffaloes slaughtered in Tanta city, Egypt during the period between May 2018 and April 2019. The age and sex of animals were recorded.

Macroscopic examination

Parts of the buffalo carcass, especially tongues, diaphragms, esophagus, and skeletal muscles were visually examined for *Sarcocystis* spp. macrocysts. The organs were cut into small pieces and examined, using a hand lens, for the presence of whitish macrocysts of different sizes as described by Lam *et al.* (1999). Fifty tissue samples containing visually suspected macrocysts were collected from tongues, diaphragms, esophagus, and skeletal muscles and divided into four parts to be studied by different methods.

Microscopic examination

Pieces of the organs of animals with macrocysts were sampled into separate bags to study the presence of microcysts. Small parts of the organs/tissues were

compressed between two glass slides, stained with 1% Giemsa and examined microscopically (Latif *et al.*, 1999).

Histological examination

Parts of the collected tissue samples were fixed in 10% neutral buffered formalin and then dehydrated by different concentrations of ethanol. They were then embedded in paraffin. Sections, about 5 µm thickness, were prepared, stained with hematoxylin and eosin (H&E), and examined under a light microscope (×40) (Bancroft, 1990).

Transmission electron microscope (TEM) examination

Suspected macrocysts that were examined by light microscope were fixed in 2.5% glutaraldehyde solution in 0.1 M phosphate buffer (pH 7.4) for 4 h. After buffer wash, specimens were post-fixed with 1% osmium tetroxide at 4°C for 4 h. Afterward, the specimens were dehydrated in a graded ethyl alcohol series, passed in two changes of propylene oxide and embedded in an epon mixture. Ultra-thin sections were prepared and stained with uranyl acetate and lead citrate before examination on a Tecnai G2 TEM at 120 kV (FEI, Hillsboro, Oregon, USA) (Lam *et al.*, 1999).

Molecular study

Suspected cysts (N=50) from muscles, esophagus, tongue, and diaphragm were washed with PBS and preserved at -20°C for DNA analysis. Genomic DNA was extracted using DNeasy Blood and Tissue Kit (QIAGEN, Germany) according to the manufacturer's instructions. Genomic DNA was used as a template to amplify 18S ribosomal subunit DNA using the following pair of primers as described by Rubiola *et al.* (2020): Sar-F1: 5'GCA CTT GAT GAA TTC TGG CA3' and Sar-R1: 5'CAC CAC CCA TAG AAT CAA G3'.

PCR reactions were performed using MyTaq™ Red Mix (Bioline) according to the manufacturer's instructions. PCR cycles were as follows: An initial denaturation step at 95°C for 3 min, followed by 35 cycles of denaturation at 94°C for 1 min, annealing at 50°C for 1 min, and extension at 72°C for 40 s, with a final extension step at 72°C for 10 min. Nuclease-free water (without genomic DNA) was included in each run as a negative control. The PCR products were then run on a 1.5% agarose gel stained with ethidium bromide.

Statistical methods

Data were analyzed using the Statistical Package for Social Sciences (SPSS ver. 20 Chicago, IL, USA). Pearson Chi-square was used for testing the association between categorical variables. The level of significance was set at P<0.05.

Results

A total of 517 buffaloes were slaughtered, and their

carcasses were visually examined. Of them, 170 (32.9%) were <2 years, 215 (41.6%) ranged from 2 to 5 years, and 132 (25.5%) ranged from 5 to 10 years. As regard to the sex; 342 (66.2%) were males and 175 (33.8%) were females.

Macroscopic detection

The overall prevalence of suspected sarcocystosis was 26.5% (137/517). There was a statistically significant increase in the prevalence of *Sarcocystis* macrocysts concerning age. The prevalence was 15.3% among buffaloes aged under 2 years, 21.9% in the age category 2-5 years, and 48.5% among the age category 5-10 years ($P < 0.001$). It was found that 19.9% of males had positive results compared to 39.4% of females (Tables 1 and 2).

Table 1: Prevalence of *Sarcocystis* spp. (macrocysts) among 517 buffaloes according to age

Age of animals	Examined No.	Positive No. (%)	Negative No. (%)	P-value
<2	170	26 (15.3)	144 (84.7)	$X^2=46$ $P < .001^*$
2 to <5	215	47 (21.9)	168 (78.1)	
5 to ≤ 10	132	64 (48.5)	68 (51.5)	
Total	517	137 (26.5)	380 (73.5)	

X^2 : Pearson Chi-square test, and * Statistically significant

Table 2: Prevalence of *Sarcocystis* spp. (macrocysts) among 517 buffaloes according to sex

Sex of animals	Examined No.	Positive No. (%)	Negative No. (%)
Males	342	68 (19.9)	274 (80.1)
Females	175	69 (39.4)	106 (60.6)
Total	517	137 (26.5)	380 (73.5)

$X^2=21.7$, and $P < .001^*$

As to the distribution of *Sarcocystis* macrocysts in the different organs in the 137 infected animals, 83.2% of infected animals showed macrocysts in the esophagus, 78.8% in their muscles, 59.1% in the diaphragm, 35% in the tongues, and 14.1% animals had macrocysts in more than one site (Table 3, Fig. 1).

Table 3: Anatomical distribution of sarcocystis (macrocysts) in the 137 infected animals

Organs	No. of positive animals	Positive percentage
Esophagus	114	83.2
Muscles	108	78.8
Diaphragms	81	59.1
Tongues	48	35.0

73 animals had cysts in esophagus, muscles, and diaphragms simultaneously

Cyst morphology

Sarcocystis cysts with thin walls were isolated from the esophagus, diaphragm, and muscles; while thick-walled cysts were all detected in tongues. Observed

under light microscopy, thin-walled cysts were ovoid and larger in size, measuring $225 \pm 34.7 \mu\text{m} \times 431.3 \pm 82.4 \mu\text{m}$ whereas thick-walled cysts isolated from tongues were spindle-shaped and smaller in size ($141.6 \pm 51.4 \mu\text{m} \times 263 \pm 82.3 \mu\text{m}$). *Sarcocystis* macrocysts pressed between two slides and stained with Giemsa stain showed many bradyzoites (Figs. 1 and 2).

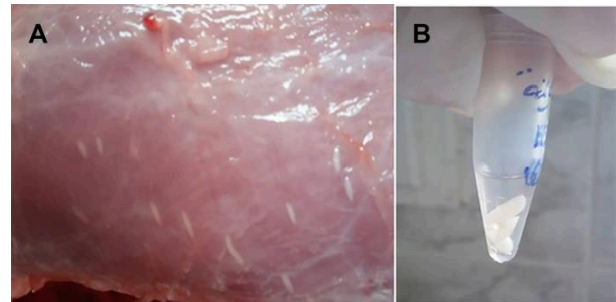


Fig. 1: Macroscopic *Sarcocystis* spp. (A) *Sarcocystis* in diaphragm, and (B) Isolated macrocysts

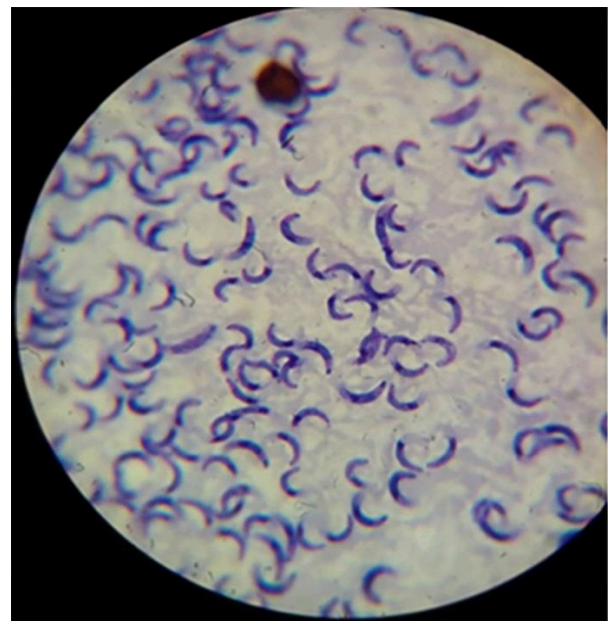

Fig. 2: Light microscopic photograph of pressed macrocysts showing huge number of mature bradyzoites stained by toluidine stain ($\times 400$)

Histological examination

Histopathological examination (Figs. 3 and 4) illustrates that among 50 macrocysts examined, *Sarcocystis* with thin wall was more prevalent ($n=37$, 74%) compared to thick-walled species ($n=13$, 26%). Microcysts were detected in 23 animals inside tissues of the tongue and esophagus.

Transmission electron microscopy (TEM)

TEM showed that cysts contained fully formed bradyzoites (Fig. 5) measuring $4.52-10.33 \mu\text{m} \times 2.3-3.39 \mu\text{m}$. Bradyzoites were separated by multiple septa dividing the cyst into chambers (Fig. 6).

Molecular analysis

PCR amplification of the *18S rRNA* gene revealed a specific band at 600 bp in 41 out of the 50 examined samples (82%). Negative samples were tested molecularly and were found to be *Cysticercus bovis* (El-Sayad *et al.*, 2021).

All DNA extracted from cysts within the esophagus, diaphragm, and muscles gave the specific distinctive band for *Sarcocystis* spp., while DNA extracted from tongue samples gave no bands in 9 out of the 12 samples examined (75%) (Table 4).

Table 4: Site of PCR results of *S. macrocysts* (n=50). Conventional PCR analysis was carried out on fifty macrocysts from different organs

PCR results	Esophagus No. (%)	Muscles No. (%)	Diaphragm No. (%)	Tongues No. (%)
Positive	13 (100)	13 (100)	12 (100)	3 (25)
Negative	0 (0)	0 (0)	0 (0)	9 (75)

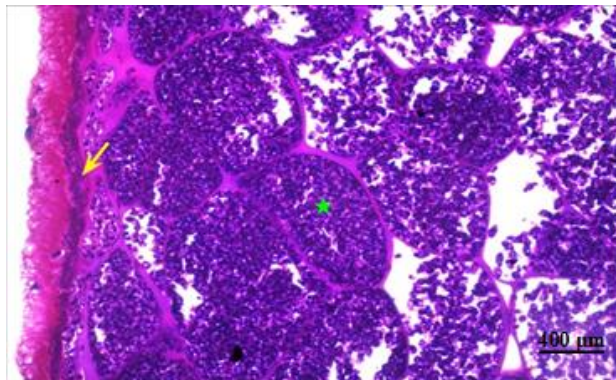


Fig. 3: The intact thin wall around the *S. fusiformis* cysts was positively stained with H&E technique (arrow). Cyst was packed with bradyzoites separated by multiple septa dividing the cyst into chambers (star)

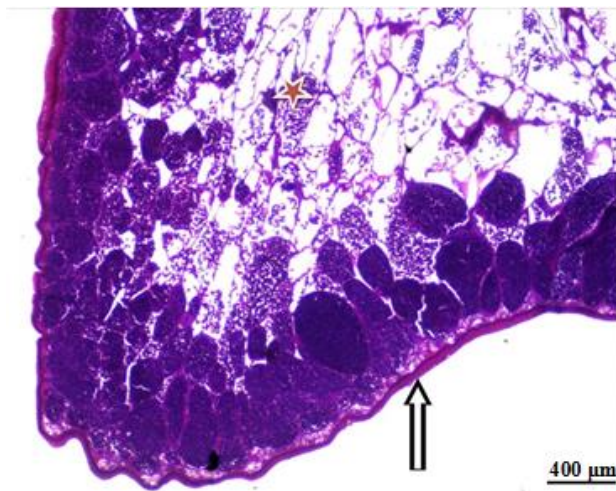


Fig. 4: Intact Sarcocysts stained with H&E impacted with numerous bradyzoites. The intact thick wall around the cysts was positively stained with H&E technique (thin blue arrow). Cyst was packed with bradyzoites separated by multiple septa dividing the cyst into chambers (thick black arrow)

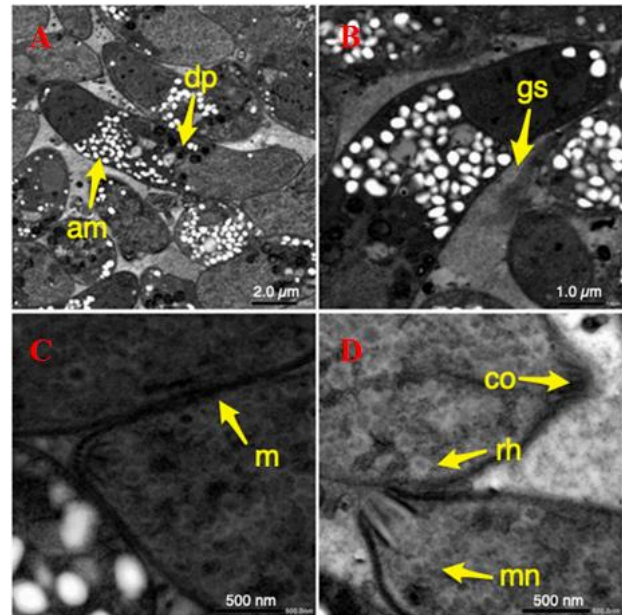


Fig. 5: TEM ultra-photograph of *Sarcocystis* macrocysts **A:** Bradyzoites containing amylopectin (am) as white granules and dense plaques (dp), **B:** Larger magnification of a bradyzoite showing the ground substance (gs), **C:** Enlarged part of a bradyzoite showing its membrane (m), and **D:** Enlarged apical part of a bradyzoite showing the conoid (co), rhoptry (rh), and micronemes (mn)




Fig. 6: TEM picture of mature bradyzoites in *Sarcocystis* macrocysts

Discussion

Diagnosis of *Sarcocystis* cysts in animals is a prerequisite for survey and surveillance of sarcocystosis in endemic re-emergent or emergent transmission zones (WHO, 2005). Visual inspection method revealed that the overall *Sarcocystis* spp. infection rate among slaughtered buffaloes was 26.5%. This high infection rate may be due to the climatic conditions in the Northern Delta of Egypt which are favorable for the survival of the parasite. Moreover, bovines are frequently exposed to infection as they are often bred in areas where stray dogs and cats are observed. Environmental contamination by the infective forms exposes all animals

to infection with *Sarcocystis*. Data from various studies showed prevalences that ranged from 25-100% in different countries (Beyazit *et al.*, 2007; Tinak, 2009; Saleh *et al.*, 2022). Differences may be attributed to the sample size, studied organs, diagnostic methods, and especially to the presence of infective stages in the environment. A high prevalence of sarcocystosis is related to close contact between the final and intermediate hosts (Tinak, 2009, Dong *et al.*, 2018).

In the current study, a greater proportion of infection was detected in older buffaloes. This may be attributed to the longer exposure over the years and the time needed for the development of macrocysts inside the carcasses. Similarly, a gradual increase in infection with age was reported in previous studies in Egypt (El-Dakhly *et al.*, 2011; Metwally *et al.*, 2014; Gareh *et al.*, 2020) and other countries (Fayer *et al.*, 2015; Mounika *et al.*, 2018; Imre *et al.*, 2019).

In the present study, infection rate in buffaloes was 39% in females and 19.9% in males with statistically significant difference ($X^2=21.7$, $P<.001^*$). Some studies found a significant association between the rate of *Sarcocystis* infection and the sex of cattle (More *et al.*, 2008; Nourani *et al.*, 2010). All infected females in the present study were more than five years old, which is under the Egyptian regulations stipulating slaughtering females after that age and this may explain the higher infection rate.

In the current study, the anatomical distribution of *Sarcocystis* macrocysts by visual examination of organs revealed preferential localization to the esophagus followed by muscles and diaphragm; the least number of macrocysts was detected in tongues. The esophagus may seemingly be an earlier station in the migration route of *Sarcocystis*. For this reason, the esophagus may be considered more helpful in detecting the infection at an earlier stage than the tongue and muscles. This result was supported by a former studies that recorded the esophagus to be the organ more often affected (Ahmed *et al.*, 2016; JyothiSree *et al.*, 2017; Elshahawy *et al.*, 2022). On the contrary, they disagreed with other reports (Beyazit *et al.*, 2007; Tinak, 2009).

Advances in diagnostic approaches for livestock are very important (WHO, 2005). In the present work, various diagnostic methods other than visual inspection were applied to cysts collected from the carcasses of slaughtered buffaloes. Microscopic examination showed the presence of microcysts inside the tissues of the tongue and esophagus only. These results were in agreement with various studies on different hosts, that recorded the presence of microscopic cysts in organs of buffaloes mainly tongues (Dafedar *et al.*, 2008; Morsy *et al.*, 2011).

Sarcocystis species are diverse. Some are thin-walled such as *S. cruzi* and *S. heydorni*, others have thick walls such as *S. hominis*, *S. hirsuta*, and *S. rommeli* (Dubey *et al.*, 2015b; Choi *et al.*, 2018). Depending on histological examination, morphologically different forms of *Sarcocystis* spp. were found in the examined animals; thin-walled species and thick-walled sarcocysts which

produce macrocysts and microcysts with separated chambers. Similar findings were reported by Beyazit *et al.* (2007) and Ayazian Mavi *et al.* (2020). Previous studies showed that *S. fusiformis* and *S. dubeyi* are the predominant species infecting buffaloes in Egypt (Hilali *et al.*, 2011; Morsy *et al.*, 2018; Ras *et al.*, 2021).

In the present study, PCR amplification of the 18S rRNA gene confirmed infection with *Sarcocystis* spp. in 82% of the examined macrocysts. All PCR-negative cysts were found in the samples of the tongue. This emphasizes the importance of molecular diagnosis in differentiating *Sarcocystis* spp. from other cyst-forming lesions.

The present study has revealed a high prevalence of bovine *Sarcocystis* in the slaughterhouses in Tanta abattoirs, Northern Delta, Egypt which suggests that the environment is heavily contaminated. The use of molecular methods in slaughterhouses should be encouraged to confirm the identity of suspected cysts.

Other studies are recommended to determine the true prevalence of sarcosporidiosis in other herbivores in different regions of Egypt. Further molecular and biochemical studies are required for differentiation between *Sarcocystis* spp., isolated from different hosts in various geographic localities. Strict control measures should be applied on stray dogs and cats in Egypt, as they possibly represent a serious source of infection.

Acknowledgements

We would like to sincerely thank the staff of Veterinary Doctors in Tanta city, the laboratory of the Pathology Department of the Medical Research Institute, and the staff of TEM Unit at Alexandria University. No fund was obtained for execution of the study.

Conflict of interest

No conflict of interest to declare.

References

- Ahmed, AM; Elshraway, NT and Youssef, AI (2016). Survey on *Sarcocystis* in bovine carcasses slaughtered at the municipal abattoir of El-Kharga, Egypt. *Vet. World*. 9: 1461-1465. doi: 10.14202/vetworld.2016.1461-1465.
- Ayazian Mavi, S; Teimouri, A; Mohebbali, M; Sharifi Yazdi, MK; Shojaee, S; Rezaian, M; Salimi, M and Keshavarz, H (2020). *Sarcocystis* infection in beef and industrial raw beef burgers from butchereries and retail stores: a molecular microscopic study. *Heliyon*. 6: e04171.
- Bancroft, JB (1990). *Theory and practice of histological techniques*. 4th Edn., London, UK, Churchill Livingstone. PP: 135-138.
- Beyazit, A; Yazicioğlu, Ö and Karaer, Z (2007). The prevalence of ovine *Sarcocystis* species in Izmir province. *Ankara Univ. Vet. Fak. Derg.*, 54: 111-116.
- Choi, TI; Hong, EJ; Ryu, SY; Sim, C; Chae, JS; Kim, HC; Park, J; Choi, KS; Yu, DH; Yoo, JG and Park, BK

- (2018). Detection and identification of *Sarcocystis cruzi* (Protozoa: Apicomplexa) by molecular and ultrastructural studies in naturally infected Korean cattle (*Bos taurus coreanae*) from Daejeon, Korea. *Korean J. Parasitol.*, 56: 121-127.
- Dafedar, AM; D'Souza, PE and Puttalakshamma, G** (2008). Prevalence of sarcocystosis in goats slaughtered at an abattoir in Bangalore, Karnataka state. *Vet. World.* 1: 335-337.
- Dong, H; Su, R; Wang, Y; Tong, Z; Zhang, L; Yang, Y and Hu, J** (2018). *Sarcocystis* species in wild and domestic sheep (*Ovis ammon* and *Ovis aries*) from China. *BMC Vet. Res.*, 14: 377. doi: 10.1186/s12917-018-1712-9.
- Dubey, JP** (2015). Foodborne and waterborne zoonotic sarcocystosis. *Food and Waterborne Parasitol.*, 1: 2-11.
- Dubey, J; Calero-Bernal, R; Rosenthal, B; Speer, C and Fayer, R** (2015a). *Sarcocystosis of animals and humans*. (2nd Edn.), CRC Press. <https://doi.org/10.1201/b19184>.
- Dubey, JP; van Wilpe, E; Calero-Bernal, R; Verma, SK and Fayer, R** (2015b). *Sarcocystis heydorni*, n. sp. (Apicomplexa: Sarcocystidae) with cattle (*Bos taurus*) and human (*Homo sapiens*) cycle. *Parasitol. Res.*, 114: 4143-4147. doi: 10.1007/s00436-015-4645-2.
- El-Dakhly, KM; El-Nesr, KA; El-Nahass, ES; Hirata, A; Sakai, H and Yanai, T** (2011). Prevalence and distribution patterns of *Sarcocystis* spp. in buffaloes in Beni-Suef, Egypt. *Trop. Anim. Health Prod.*, 43: 1549-1554. doi: 10.1007/s11250-011-9840-2.
- El-Sayad, MH; Farag, H; El-Taweel, H; Fadly, R; Salama, N; Ahmed, AAE and El-Latif, NFA** (2021). *Cysticercus bovis* in cattle slaughtered in North Egypt: Overestimation by the visual inspection method. *Vet. World.* 14: 155-160.
- Elshahawy, IS; Mohammed, E; Gomaa, A and Fawaz, M** (2022). *Sarcocystis cruzi* in Egyptian slaughtered cattle (*Bos taurus*): epidemiology, morphology and molecular description of the findings. *Iran. J. Vet. Res.*, 23: 337-348. doi:10.22099/IJVR.2022.43498.6363.
- Fayer, R** (2004). *Sarcocystis* spp. in human infections. *Clin. Microbiol. Rev.*, 17: 894-902.
- Fayer, R; Esposito, DH and Dubey, JP** (2015). Human infections with *Sarcocystis* species. *Clin. Microbiol. Rev.*, 28: 295-311. doi: 10.1128/CMR.00113-14.
- Gareh, A; Soliman, M; Saleh, AA; El-Gohary, FA; El-Sherbiny, H; Mohamed, RH and Elmahallawy, EK** (2020). Epidemiological and histopathological investigation of *Sarcocystis* spp. in slaughtered dromedary camels (*Camelus dromedarius*) in Egypt. *Vet. Sci.*, 7: 162. doi: 10.3390/vetsci7040162.
- Hilali, M; El-Seify, M; Zayed, A; El-Morsey, A and Dubey, JP** (2011). *Sarcocystis dubeyi* (Huong and Uggla, 1999) infection in water buffaloes (*Bubalus bubalis*) from Egypt. *J. Parasitol.*, 97: 527-528. doi: 10.1645/GE-2656.1.
- Hoeve-Bakker, BJA; van der Giessen, JWB and Franssen, FFJ** (2019). Molecular identification targeting *cox1* and *18S* genes confirms the high prevalence of *Sarcocystis* spp. in cattle in the Netherlands. *Int. J. Parasitol.*, 49: 859-866.
- Hu, JJ; Liao, JY; Meng, Y; Guo, YM; Chen, XW and Zuo, YX** (2011). Identification of *Sarcocystis cymruensis* in wild *Rattus flavipectus* and *Rattus norvegicus* from the people's Republic of China and its transmission to rats and cats. *J. Parasitol.*, 97: 421-424. doi: 10.1645/GE-2633.1.
- Imre, K; Darabus, G; Tirziu, E; Morariu, S; Imre, M; Plutzer, J; Boldea, MV and Morar, A** (2019). *Sarcocystis* spp. in romanian slaughtered cattle: Molecular characterization and epidemiological significance of the findings. *Biomed. Res. Int.*, 4123154. doi: 10.1155/2019/4123154.
- JyothiSree, C; Venu, R; Samatha, V; Malakondaiah, P and Rayulu, VC** (2017). Prevalence and microscopic studies of *Sarcocystis* infection in naturally infected water buffaloes (*Bubalus bubalis*) of Andhra Pradesh. *J. Parasit. Dis.*, 41: 476-482.
- Koudela, B and Modrý, D** (2000). *Sarcocystis muris* possesses both diheteroxenous and dihomoxenous characters of life cycle. *J. Parasitol.*, 86: 877-879.
- Lam, K; Watkins, K and Chan, C** (1999). First report of equine protozoal myeloencephalitis in Hong Kong. *Equine Vet. Educ.*, 11: 54-56.
- Latif, BM; Al-Delemi, JK; Mohammed, BS; Al-Bayati, SM and Al-Amiry, AM** (1999). Prevalence of *Sarcocystis* spp. in meat-producing animals in Iraq. *Vet. Parasitol.*, 84: 85-90.
- Lindsay, DS and Dubey, JP** (2020). Neosporosis, toxoplasmosis, and sarcocystosis in ruminants: An update. *Vet. Clin. North Am. Food Anim. Pract.*, 36: 205-222.
- Marques, SM; Barbosa, J; Quadros, R and Pilati, C** (2018). Occurrence of *Sarcocystis cruzi* in cattle in the state of Santa Catarina, Brazil. *Int. J. Infect. Dis.*, 73: 303. doi: 10.1016/j.ijid.2018.04.4105.
- Metwally, AM; Abd Ellah, MR; Al-Hosary, AA and Omar, MA** (2014). Microscopical and serological studies on *Sarcocystis* infection with the first report of *S. cruzi* in buffaloes (*Bubalus bubalis*) in Assiut, Egypt. *J. Parasit. Dis.*, 38: 378-382. doi: 10.1007/s12639-013-0257-x.
- Moré, G; Abrahamovich, P; Jurado, S; Bacigalupe, D; Marin, J; Rambeaud, M; Venturini, L and Venturini, MC** (2011). Prevalence of *Sarcocystis* spp. in Argentinean cattle. *Vet. Parasitol.*, 177: 162-165.
- More, G; Basso, W; Bacigalupe, D; Venturini, MC and Venturini, L** (2008). Diagnosis of *Sarcocystis cruzi*, *Neospora caninum*, and *Toxoplasma gondii* infections in cattle. *Parasitol. Res.*, 102: 671-675.
- Morsy, K; Abdel-Ghaffar, F; Bin Dajem, S; Abdel-Gaber, R and El Gazar, F** (2018). First molecular characterization and morphological aspects of *Sarcocystis fusiformis* infecting water buffalo *Bubalus bubalis* in Egypt. *Acta Parasitol.*, 63: 333-345. doi: 10.1515/ap-2018-0038.
- Morsy, K; Saleh, A; Al-Ghamdi, A; Abdel-Ghaffar, F; Al-Rasheid, K; Bashtar, AR; Al Quraishy, S and Mehlhorn, HI** (2011). Prevalence pattern and biology of *Sarcocystis capracanis* infection in Egyptian goats: a light and ultrastructural study. *Vet. Parasitol.*, 181: 75-82.
- Mounika, K; Chennuru, S; Ravipati, V; Tumati, SR and Krovvidi, S** (2018). Studies on prevalence and histomorphology of *Sarcocystis* species infecting cattle in Andhra Pradesh, India. *J. Parasitic Dis.*, 42: 77-80. doi: 10.1007/s12639-017-0968-5.
- Nourani, H; Matin, S; Nouri, A and Azizi, H** (2010). Prevalence of thin-walled *Sarcocystis cruzi* and thick-walled *Sarcocystis hirsuta* or *Sarcocystis hominis* from cattle in Iran. *Trop. Anim. Health Prod.*, 42: 1225-1227.
- Prakas, P and Butkauskas, D** (2012). Protozoan parasites from genus *Sarcocystis* and their investigations in Lithuania. *Ekologija*, 58: 45-58. doi: 10.6001/ekologija.v58i1.2349.
- Ras, R; Gouda, AA; AbdelMageed, MA; El Damaty, HM and Anter, RG** (2021). Prevalence and molecular identification of *Sarcocystis* spp. infecting water buffaloes (*Bubalus bubalis*) in Sharkia province, Egypt. *Egypt. Vet. Med. Soc. J.*, 17: 1-19.
- Rubiola, S; Civera, T; Ferroglio, E; Zanet, S; Zaccaria, T; Brossa, S; Cipriani, R and Chiesa, F** (2020). Molecular differentiation of cattle *Sarcocystis* spp. by multiplex PCR targeting *18S* and *COI* genes following identification of

- Sarcocystis hominis* in human stool samples. Food Waterborne Parasitol., 18: 00074. doi: 10.1016/j.fawpar.2020.e00074.
- Saleh, M; Spotin, A; Rostamian, M and Adami, M** (2022). Prevalence and molecular assessment of *Sarcocystis* infection in livestock in northeast Iran. Comp. Immunol. Microbiol. Infect. Dis., 80: 101738. doi: 10.1016/j.cimid.2021.101738.
- Savini, G; Dunsmore, J; Robertson, I and Seneviratna, P** (1992). The epidemiology of *Sarcocystis* spp. in cattle of Western Australia. Epidemiol. Infect., 108: 107-113.
- Slesak, G; Schafer, J; Langeheinecke, A and Tappe, D** (2015). Prolonged clinical course of muscular sarcocystosis and effectiveness of cotrimoxazole among travelers to Tioman Island, Malaysia, 2011-2014. Clin. Infect. Dis., 60: 329. doi: 10.1093/cid/ciu791.
- Tenter, AM** (1995). Current research on *Sarcocystis* species of domestic animals. Int. J. Parasitol., 25: 1311-1330.
- Tinak, SG** (2009). Prévalence de la Sarcosporidiose dans les Muscles des Petits Ruminants aux Abattoirs de Dakar (Senegal). University Cheikh Anta Diop, Dakar, Senegal. P: 103.
- World Health Organization** (2005). WHO/FAO/OIE guidelines for the surveillance, prevention, and control of taeniosis/cysticercosis: Paris: World Organisation for Animal Health.