

## Scientific Report

# Estrogen-induced mammary fibroadenoma in a lamb: hormonal and immunohistochemical aspects

Dezfoulian, O.<sup>1\*</sup>; Asadian, P.<sup>1</sup>; Sookhtehzari, A.<sup>2</sup>  
and Kheradmand, A.<sup>2</sup>

<sup>1</sup>Department of Pathobiology, School of Veterinary Medicine, Lorestan University, Khorramabad, Iran;

<sup>2</sup>Department of Clinical Sciences, School of Veterinary Medicine, Lorestan University, Khorramabad, Iran

\*Correspondence: O. Dezfoulian, Department of Pathobiology, School of Veterinary Medicine, Lorestan University, Khorramabad, Iran. E-mail: [omidvete@yahoo.com](mailto:omidvete@yahoo.com)

(Received 24 Apr 2010; revised version 18 Oct 2010; accepted 30 Oct 2010)

## Summary

A fibroadenoma was diagnosed in the mammary gland of a lamb by immunohistochemical method and measurement of oestradiol hormone. The tumor was characterized by an encapsulated firm mass with a creamy-white cut surface. Histologically, it consisted of variably-sized sinus ducts, covered by a single or multiple layers of proliferated epithelial cells, and embedded in a loose connective tissue. Immunohistochemical results revealed that more than half of the epithelial tumor cells were labelled only for estrogen, but not for progesterone. Moreover, the high level of plasma ER concentration in contrast to the normal PR value was consistent with immunohistochemical findings. Both results suggested that reproductive hormones, exclusively estrogen, influenced the developmental stage of the mammary glands and are responsible for neoplastic changes in this case. This study indicated for the first time the novel evidence of estrogen-induced fibroadenoma in a 2-month-old lamb mammary gland tissue.

**Key words:** Estrogen receptor  $\alpha$ , Fibroadenoma, Lamb, Mammary gland

## Introduction

Fibroadenoma is one of the most common benign mammary tumors in human beings (Kuijper *et al.*, 2001), cats and dogs (Misdorp *et al.*, 1999). Only a few reports in ruminants indicate that the tumor incidence is dependent to age (Gulbahar *et al.*, 2007). It is confirmed that proliferation and differentiation of numerous normal and tumor cells are regulated by the expression of nuclear hormone receptors like estrogen (ER) and progesterone (PR). (Saqui-Salces *et al.*, 2008). The estrogen- $\alpha$  is a growth factor that, when its expression increases, the stage of breast cancer formation is initiated (Anderson, 2002).

## Case presentation

A 2-month-old female lamb bred in a common livestock, in a village suburb of

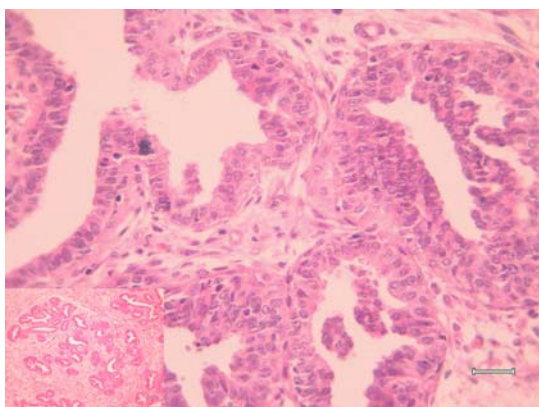
Khorramabad (center of Lorestan province) developed a pedunculated bilateral mammary gland enlargement. The lamb was kept under free run condition within a group of several small ruminants, none of which has ever been treated with chemical hormones in their history.

A blood sample was taken for evaluation of biochemical profile using disodium EDTA-containing evacuated tubes. Surgical biopsy was fixed in 10% neutral buffered formalin, processed routinely, sectioned at 5  $\mu$ m and stained with haematoxylin and eosin. Replicated sections of tumoural tissue were also immunostained with mouse monoclonal antibodies against estrogen receptor- $\alpha$  and progesterone (Dako, Glostrup, Denmark), in appropriate dilutions, using the labeled streptavidin-biotin method (LASB™ kit, Dako). Slides were counterstained with Mayer's hematoxylin. Normal ovine mammary tissue

was applied as positive control for both ER-alpha and PR. The primary antibody was replaced by non-immune serum used as negative control.

Plasma was separated by centrifugation of samples ( $1000 \times g/15$  min) and stored at  $-80^{\circ}\text{C}$  until analysis. Calcium concentration was measured by the O-cresolphthalein Complexone (Caudill and Boone, 1986). ALP activity was measured by means of p-nitrophenyl phosphate as a substrate and calculated by means of calibration curve (Zhang *et al.*, 2005). Estradiol, progesterone and prostate specific antigen were measured with enzyme immunoassay method (DRG International Inc. Elisa kit, United States).

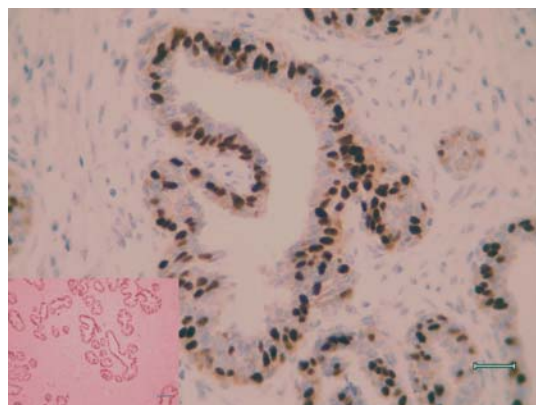
The cut surface of the submitted incisional biopsy was firm, well-circumscribed and white to creamy in colour with a glistening appearance containing multinodular structures, separated by fibrous connective tissue. Histologically, the glands were irregular in shape and were surrounded by a considerable amount of cellular connective tissue with numerous fibroblasts. The ducts were lined from single columnar to several layers of markedly hyperplastic epithelial cells with round to ovoid vesicular nuclei within the scant eosinophilic cytoplasm (Fig. 1).



**Fig. 1:** The ducts proliferate and are lined by several layers of hyperplastic epithelial cells. H&E, bar =  $30 \mu\text{m}$ . *Inset:* The proliferated glands, surrounded by fibrotic tissue. H&E, bar =  $200 \mu\text{m}$

In a few of the glands, the rate of proliferation of epithelial cells was sufficient enough to fill the lumen, whereas in some of them the proliferated cells tended to form papilliform structures which project into the

lumen of acini. Immunohistochemical examination revealed that only ER-alpha was expressed in nearly 70% of the nuclei in the tumoral epithelial cells (Fig. 2), however they were negative for PR ( $\text{ER}^+/\text{PR}^-$ ). The control specimen was negative for both ER and PR.



**Fig. 2:** The nuclei of epithelial cells in a single gland strongly stained with anti-estrogen receptor  $\alpha$ . SAB immunolabelling, Mayer's hematoxylin counter stain bar =  $200 \mu\text{m}$ . *Inset:* The photomicrograph shows nuclear immunolabeling of lower magnification. SAB immunolabelling, Mayer's hematoxylin counter stain bar =  $30 \mu\text{m}$

Serum diagnostic tests included both biochemical analysis and determination of hormones concentration. The following abnormalities were found in serum biochemical analyses: low calcium concentration ( $6.8 \text{ mg/dl}$ ; normal range,  $9.5 \pm 0.04$ ), high ALP concentration ( $632 \text{ U/L}$ ; normal range,  $184.24 \pm 3.21 \text{ U/L}$ ) and high LDH ( $1138 \text{ U/L}$ ; normal range,  $448.66 \pm 1.11 \text{ U/L}$ ) diagnosed as biochemical profile. Hormonal assays indicated the high serum concentration of estradiol ( $42.9 \text{ pg/ml}$  vs.  $7.6 \pm 0.4$  as maximum reported concentration) and normal progesterone content ( $0.2 \text{ ng/ml}$ , vs.  $2.5\text{-}4 \text{ ng/ml}$  as maximum reported concentration).

## Discussion

The numerous expressions of estrogen receptors in tumor tissue sections as well as the high levels of this hormone and the low concentration of progesterone has indicated that the occurrence of fibroadenoma in the present case is related to estrogen

stimulation, similar to the findings in other studies (Selcer *et al.*, 2007). However some cats with mammary fibroadenomatous hyperplasia, when treated by progestin antagonist, their developmental mass were completely regressed (Wehrend *et al.*, 2001). Therefore, the documented evidence in the present or other studies show that the induction of fibroadenoma is mainly hormone-dependent tumor growth.

It is now well-established that for the physiological maturation and development of mammary gland structure or even neoplastic changes, both estrogen and progesterone have an essential role. In this regard, estrogen stimulates the ductal development (individually has a direct effect on those cells that express receptor for estrogen) and both hormones participate in the development and differentiation of lobulo-alveolar tissues (Anderson, 2002).

Prior to puberty, estradiol and progesterone serum concentrations are similar at basal levels in adult ewes without reaching concentrations that correspond with ovarian cyclicity (Meikle *et al.*, 1997). Just near the onset of behavioral estrus there is a sudden rise in plasma oestrogen, especially estradiol (Arthur *et al.*, 1996). The peak of estradiol concentrations before the first and second ovulation in the breeding season of ewes are  $7.6 \pm 0.4$  and  $5.6 \pm 0.5$  pg/ml, respectively (Bartlewskia *et al.*, 1999). Estradiol concentration in this case was 42.9 pg/ml (six times more than the maximum concentration in adolescent). The ability of breast tumors to synthesize sex steroid hormones is well-recognized and their local production is thought to play a role in breast cancer development and growth (Mady *et al.*, 2000). The parenchymal cells of the normal breast convert estrone sulfate to estradiol and estrone (Chatterton *et al.*, 2003).

There is only one report concerning mammary gland fibroadenoma in a slaughtered lamb without any hormonal measurement by Gulbahar *et al.* (2007). They found neither estrogen nor progesterone positive cells on tissue sample. Also, they failed to show that serum hormonal changes induced fibroadenoma.

Prostate specific antigen (PSA) is a favorable diagnostic indicator in

differentiation between breast cancer and those with benign breast disease in women. Although there was no significant difference in PSA content between fibroadenoma and the healthy control group in a study conducted in Britain, the total PSA levels had decreased with age in normal controls and malignant breast cancer patients but not in those with benign breast disease, rather 7% elevation was observed in fibroadenoma patients (Romppanen *et al.*, 1999). Nevertheless, no elevation in total PSA concentration occurred in our patient.

Alkaline phosphatase (ALP) is a membrane-bound enzyme present in multiple molecular forms (isoenzymes) in many tissues, like placenta. The placental isoenzyme A has been detected in a very low concentration in pregnant ewes (Antonov and Malchevski, 1983).

To the best of our knowledge, increasing activity of total alkaline phosphatase (TALP) in the serum has not been reported in association with mammary lesions in ruminant so far, and this may be the first report of ALP elevation in a benign mammary tumor in lambs. In one study, Karayannopoulou *et al.* (2003) investigated the ALP activity in canine mammary neoplasms. Their findings showed that ALP activity in 42.9% of dogs with fibroadenoma was within normal range, but up to 2 times, 2-4 times and 4-8 times in 28.6, 14.3 and 14.3% of patients had increasing activity, respectively.

In histochemical studies of human breast tumors, the activity of ALP was compared in benign and malignant lesions. ALP was prominent in normal mammary epithelium, limited to the myoepithelial layer in benign tumors and was absent in malignant cell lines (Livni and Laufer, 1975). ALP isoenzymes varieties were not evaluated in this study. On the other hand, evaluation of calcification in the human breast lesions is a major assessment criterion for breast mammography (Tse *et al.*, 2008). However in this case, serum calcium concentration fluctuated in its normal range.

It should be considered that breast tumors may be a hormone-dependent disorder and therefore, diagnostic methods, like immunohistochemistry and biochemical analysis are inevitable for proper

implementation of treatment strategy.

This study is probably the first report of mammary fibroadenoma induced by estrogen in veterinary literature.

## References

- Anderson, E (2002). The role of oestrogen and progesterone receptors in human mammary development and tumorigenesis. *Breast Cancer Res.*, 4: 197-201.
- Antonov, S and Malchevski, M (1983). Alkaline phosphatase activity and isoenzymes in the blood serum of cattle, sheep and swine. *Vet. Med. Nauki.*, 20: 3-11.
- Arthur, GH; Noakes, DE; Pearson, H and Parkinson, TJ (1996). *Veterinary reproduction and obstetrics*. 7th Edn., London, W. B. Saunders Co., PP: 27-29.
- Bartlewska, PM; Beard, AP and Rawlings, NC (1999). Ovarian function in ewes at the onset of the breeding season. *Anim. Reprod. Sci.*, 57: 67-88.
- Caudill, SP and Boone, DJ (1986). Analytical variance and definition of a reference change as a function of calcium concentration. *Clin. Chem.*, 32: 308-313.
- Chatterton, RTJr; Geiger, AS; Gann, PH and Khan, SA (2003). Formation of estrone and estradiol from estrone sulfate by normal breast parenchymal tissue. *J. Steroid. Biochem. Mol. Biol.*, 86: 159-166.
- Gulbahar, MY; Guvenc, T; Yarim, M; Kabak, YB and Sozgen, Y (2007). Mammary fibroadenoma in a lamb. *J. Vet. Sci.*, 8: 423-425.
- Karayannopoulou, M; Koutinas, AF; Polizopoulou, ZS; Roubies, N; Fytianou, F; Saridomichelakis, MN and Kladrymidou, E (2003). Total serum alkaline phosphatase activity in dogs with mammary neoplasms: a prospective study on 79 natural cases. *J. Vet. Med.*, 50: 501-505.
- Kuijper, A; Mommers, ECM; van der Wall, E and van Diest, PJ (2001). Histopathology of fibroadenoma of the breast. *Am. J. Clin. Pathol.*, 115: 736-742.
- Livni, N and Laufer, A (1975). Histochemical studies of human breast tumors: activity of alkaline phosphatase, acid phosphatase and glucose-6-phosphate dehydrogenase. *Pathol. Microbiol.*, 42: 159-170.
- Mady, EA; Ramadan, EE and Ossman, AA (2000). Sex steroid hormones in serum and tissue of benign and malignant breast tumor patients. *Dis. Markers*. 16: 151-157.
- Meikle, A; Tasenda, C; Rodriguez, M and Garofalo, EG (1997). Effects of estradiol and progesterone on the reproductive tract and on uterine sex steroid receptors in female lambs. *Theriogenology*. 48: 1105-1113.
- Misdorp, W; Else, RW; Hellmen, E and Lipscomb, TP (1999). *Histological classification of mammary tumors of the dog and cat*. Vol. 7, Washington D.C., Armed Forces Institute of Pathology, American Registry of Pathology. PP: 11-15.
- Romppanen, J; Kesikuru, R; Kataja, V; Eskelinen, M; Kosma, VM; Savolainen, K; Uusitupa, M and Mononen, I (1999). Measurement of prostate-specific antigen in detection of benign or malignant breast disease in women. *Br. J. Cancer.*, 79: 1583-1587.
- Saqui-Salces, M; Neri-Gomez, T; Gamboa-Dominguez, A; Ruiz-Palacios, G and Camacho-Arroyo, I (2008). Estrogen and progesterone receptors isoforms expression in the stomach of Mongolian gerbils. *World J. Gastroenterol.*, 14: 5701-5706.
- Selcer, KW; Difrancesca, HM; Chandra, AB and Li, PK (2007). Immunohistochemical analysis of steroid sulfatase in human tissues. *J. Steroid. Biochem. Mol. Bio.*, 105: 115-123.
- Tse, GM; Tan, PH; Pang, AL; Tang, AP and Cheung, HS (2008). Calcification in breast lesions: pathologists' perspective. *J. Clin. Pathol.*, 61: 145-151.
- Wehrend, A; Hospes, R and Gruber, AD (2001). Treatment of feline mammary fibroadenomatous hyperplasia with a progesterone-antagonist. *Vet. Rec.*, 148: 346-347.
- Zhang, L; Balcerzak, M; Radisson, J; Thouverey, C; Pikula, S; Azzar, G and Buchet, R (2005). Phosphodiesterase activity of alkaline phosphatase in ATP-initiated Ca (2+) and phosphate deposition in isolated chicken matrix vesicles. *J. Biol. Chem.*, 280: 37289-37296.