

Scientific Report

Use of three-dimensional ultrasonography of the eye and measurement of optical long axis in dog

Vosough, D.^{1*}; Masoudifard, M.²; Vajhi, A.²;
Molazem, M.² and Veshkini, A.²

¹Department of Clinical Sciences, Faculty of Veterinary Medicine, Shahid Bahonar University of Kerman, Kerman, Iran; ²Department of Clinical Sciences, Faculty of Veterinary Medicine, University of Tehran, Tehran, Iran

*Correspondence: D. Vosough, Department of Clinical Sciences, Faculty of Veterinary Medicine, Shahid Bahonar University of Kerman, Kerman, Iran. E-mail: vosough@vetmed.ut.ac.ir

(Received 19 Jun 2006; revised version 24 Feb 2007; accepted 4 Mar 2007)

Summary

This study was conducted to determine the use of three-dimensional ultrasonography (3DU) in ocular imaging of the dog and measuring of its optical axis. 12 healthy mixed-breed dogs including 6 males and 6 females were studied. 3DU of the eyes were done using a 5–12 MHz linear trapezoid transducer. 3DU of the eyes were evaluated and the normal optical long axis through a line between the cornea and the optic disc in three-dimensional images were measured. In 3D images, vitreous body, anterior chamber, and lens cortex and its nucleus had a distinct anechogenic to hypoechogenic pattern. Details of the eyes compartments were better observed by rotating the images in all possible angles and planes using 3D facilities. Anterior and posterior lens capsule and the optic disk were hyperechogenic. The mean \pm SD optical axis was 20.7 ± 0.9 mm in males and 26.3 ± 0.6 mm in females ($P < 0.05$). No significant difference existed between the measurements made in left and right eyes. We found marked advantages in image acquisition for interpretation of all aspects of the ocular structures.

Key words: Three-dimensional ultrasonography, Eye, Optical axis

Introduction

In veterinary ophthalmology, B-scan ultrasound provides a two-dimensional real-time image and is the most common mode of ultrasound used in clinical settings. In the last decade, three-dimensional ultrasonography (3DU) has been increasingly used as a diagnostic tool in human (Finger and Romero, 1998) but it is still not common in veterinary practice. Presence of small disorders, hyphema, foreign bodies, and tumours are plain to investigate by 3DU. This is probably due to possibility of different angle of scanning which provides favourite images for the clinician (Finger, 2002). If a local retinal detachment has not been seen in 2D examination, it is much easier to be found by 3DU (Julian and Garcia, 2001). Also, 3DU of the eye can

result in better determination of choosing surgical treatment for the tumours which are placed in the caudal region of the orbit (Kealy and McAllister, 2000).

Materials and Methods

Twelve (six male and six female) 2-year-old healthy dogs with no evidence of ocular diseases were selected. GE Voluson 730-Pro ultrasound equipment with “3D small parts” option of a 5–12 MHz linear trapezoid of 3D-4D transducer was applied for all the examinations. All the cases were sedated and tetracaine HCl 0.05% drop was used to partially prevent eye movements. Transpalpebral method and liberal amounts of acoustic gel were directly applied to the eyelid for scanning of the eye (Nyland and Matton, 2002). At the first, 2D images of the

eye were obtained. After exact tracing of ocular structures, 3DU image acquisition was performed as a volume of data with nearly immediate reconstruction and simultaneous display of sectional anatomy in three orthogonal planes (sagittal plane, transverse or coronal plane) or any arbitrary oblique plane and also finally a 360-degree rotating 3D plane. Finally, the normal values of the optical long axis were measured from a line between cornea and optic disc in males and females, left and right eyes. All the obtained data were compared by paired-sample Student's t-test.

Results

The 3DU method was found to be a valuable technique for canine ophthalmic evaluations. All of the ocular structures at different planes could be finely displayed and analysed. In the obtained 3D images, vitreous body, anterior chamber and lens cortex and nucleus showed distinct anecho- to hypoecho-genicity. By using different probe angle, it was easily possible to detect different scans of complete lens, cornea, iris, ciliary body and optic disc. However, it was easier to see all sagittal, corneal, and transverse planes by changing the position of the cursor presents on the monitor into the favourite plane (Fig. 1). The 3DU image acquisition required less than 10 sec using this advanced ultrasound machine. Finally a 3D rotating animation of the ocular structures at the desired angle could be reconstructed for better visualization and recognition of different parts of the eye (Fig. 2). The values of the optical long axis in obtained 3D images—the distance between the cornea and the optic disc—are shown in Table 1. There was a significant difference ($P<0.05$) between ocular measurements of male and female dogs. No significant difference was observed between left and right eyes (Table 2).

Discussion

Some researches have shown the usefulness of 3DU in investigation of different disorders. Choroids melanomas have been diagnosed, described and

measured by this technique (Finger and Romero, 1998). Finger (2002) detected a

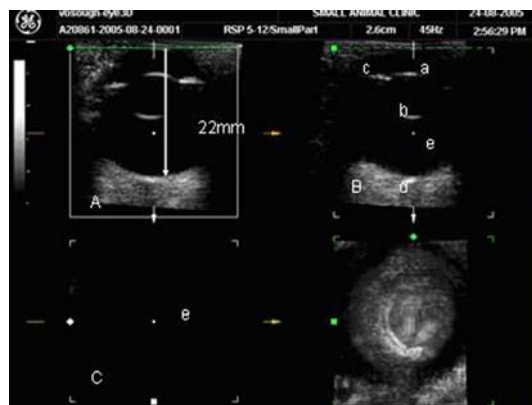


Fig. 1: 3D image of the eye which has the potential to demonstrate all the planes by changing the cursor on the voluntary point and measurement of optical long axis in plane A, A: longitude section, B: transverse section and C: horizontal section, a = anterior lens capsule, b = posterior lens capsule, c = ciliary body, e = vitreous body and d = optic disc

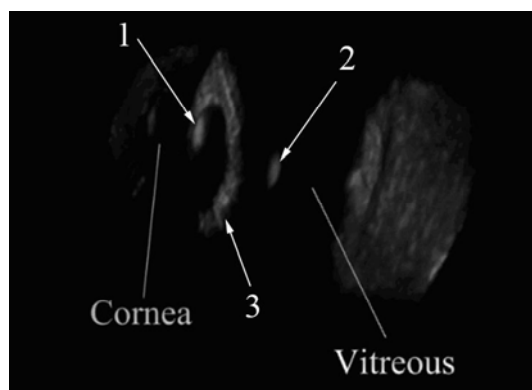


Fig. 2: The reconstructed 3D, final, rotating image of the eye; 1: anterior capsule, 2: posterior capsule and 3: ciliary body

Table 1: Measurements of right and left eye long axes in female and male dogs

Case No.	Sex	Long axis (mm)	
		Right eye	Left eye
1	M	22	20
2	M	21	22
3	M	20	20.5
4	M	21	21.5
5	M	20.5	21.5
6	M	20.2	19.8
7	F	27	28
8	F	26	27.5
9	F	26.5	28
10	F	27.8	27.2
11	F	27	27
12	F	27.4	27.8

Table 2: Mean and SD of right and left eye long axes in male and female dogs

	Male		Female	
	Right eye	Left eye	Right eye	Left eye
Mean (mm)	20.7	20.8	26.9	27.5
SD	0.7	0.9	0.6	0.4

retinoblastoma and its distribution in the eye in all 3D views. Julian and Garcia (2001) measured the size of the optic disc by 3DU and computed tomography (CT) and showed that 3DU is more accurate than CT. In veterinary medicine, ocular biometry can be used in determining the lens implant size, in calculation of the lens refractive power, and in estimating the size of the prosthetic globe after enucleation. Axial ocular length is significantly longer in men than women (Cottrill *et al.*, 1989). The same result was found in the dog (Tomlinson and Phillips, 1990); however, a later independent study reported no significant differences (Schiffer *et al.*, 1982). The lengths of the right and the left eyes are equal in all species studied (Cottrill *et al.*, 1989). Dolichocephalism breeds have a longer globe than do mesocephalic breeds. The results of this preliminary study proved usefulness of 3DU in canine ophthalmology as well. More investigations are necessary for clinical

application of this technique in veterinary medicine.

References

- Cottrill, NB; Banks, WJ and Pechman, RD (1989). Ultrasonography and biometric evaluation of the eye and orbit of dogs. *Vet. Res.*, 50: 898-903.
- Finger, PT and Romero, JM (1998). Three dimensional ultrasonography of choroidal melanoma. *Arch. Ophthalmol.*, 116: 305-312.
- Finger, PT (2002). Three dimensional ultrasonography of retinoblastoma: initial experience. *Ophthalmology*. 86: 1136-1138.
- Julian, PS and Garcia, Jr (2001). Optic nerve measurement by 3D ultrasonography. *Arch. Ophthalmol.*, 24: 102-105.
- Kealy, KJ and McAllister, H (2000). *Diagnostic radiology and ultrasonography of the dog and cat*. 3rd. Edn., Philadelphia, W. B. Saunders Co., PP: 377-378.
- Nyland, TG and Matton, JS (2002). *Small animal diagnostic ultrasound*. 2nd. Edn., Philadelphia, W. B. Saunders Co., PP: 306-322.
- Schiffer, SP; Rantanen, NW and Leary, GA (1982). Biometric study of the canine eye, using A-mode ultrasonography. *Am. J. Vet. Res.*, 43: 826-830.
- Tomlinson, A and Phillips, CI (1990). Aplanation tension and axial length of the eyeball. *Brit. J. Ophthalmol.*, 54: 548-553.