

Scientific Report

Exocrine pancreatic adenocarcinoma in a toy breed dog

Oskoui-zadeh, K.¹; Jamshidi, Sh.^{2*}; Ashrafihelan, J.³
and Veshkini, A.²

¹Department of Clinical Sciences, Faculty of Veterinary Medicine, University of Shahrekord, Shahrekord, Iran; ²Department of Clinical Sciences, Faculty of Veterinary Medicine, University of Tehran, Tehran, Iran; ³Department of Pathobiology, Faculty of Veterinary Medicine, University of Tabriz, Tabriz, Iran

*Correspondence: Sh. Jamshidi, Department of Clinical Sciences, Faculty of Veterinary Medicine, University of Tehran, Tehran, Iran. E-mail: shjamshidi@vetmed.ut.ac.ir

(Received 12 Nov 2006; revised version 24 Feb 2007; accepted 27 Jun 2007)

Summary

A 4-year-old female miniature pincher with a 40-day history of weight loss, lethargy and vomiting was referred to Small Animal Hospital, Faculty of Veterinary Medicine, University of Tehran. The case also had severe jaundice, chronic diarrhoea and steatorrhoea. The efforts for saving the life of the case were not successful and finally the animal died of hypovolaemic shock and electrolyte imbalance. At necropsy, the body was cachectic, oedematous and severely icteric. A haemorrhagic ascitic fluid, without fibrin and clot was also noticed in the abdominal cavity. Firm tumour masses originated from pancreas were seeded to peritoneum with multiple attachments to duodenum. There were also metastasis to regional lymph nodes and liver. Based on histopathologic characteristics of the tumour, the mass was diagnosed as relatively well-differentiated exocrine pancreatic adenocarcinoma.

Key word: Adenocarcinoma, Dog, Exocrine pancreas, Histopathology, Jaundice

Introduction

Exocrine pancreatic tumours are rare in dog (Ettinger and Feldman, 2005) and cat (Dill-Macky, 1993). Bennett *et al.* (2001) reported an estimated incidence of 17.8/100,000 patient per years at risk for dog and 12.6/100,000 patient per years at risk for cat. This differs from human, in whom pancreatic neoplasia is the fifth most common cause of cancer-related mortality (Mayer, 1991). Although older female dogs and spaniels have been described as being at higher risk (Withrow and Macewen, 2001), it has not been documented in some other reports (Bennett *et al.* 2001). The etiology of neoplastic conditions of the exocrine pancreas is usually unknown. There is an association between cigarette smoking and pancreatic tumours in humans (Poston *et al.*, 1991), but there are too few animals studied to associate the disease to the presence of

smokers in the household. Increasing the soya meal content of rat's diet increases the risk of pancreatic neoplasia, possibly through an increase in cystokinin—a pancreatic growth stimulant—via a trypsin inhibitor found in the soya meal (Watanapa and Williamson, 1993).

Clinical signs and laboratory findings are often nonspecific and misleading, but weight loss, vomiting, and anorexia are relatively common (Ettinger and Feldman, 2005). Paraneoplastic alopecia was reported in a cat (Tasker *et al.*, 1999) and exocrine pancreatic insufficiency was seen in a dog (Bright, 1985). Clinicopathologic tests can show increases in pancreatic enzymes, but evidence of extrahepatic biliary obstruction is more frequently seen. Indeed, changes in the liver enzymes (i.e., serum alkaline phosphatase and alanine aminotransferase) can be more increased than the activities of amylase and lipase (Bennett *et al.*, 2001).

There are no reports of successful treatment of exocrine pancreatic neoplasia in neither dog nor cat, and most patients have widely metastatic disease at the time of diagnosis (Garvey and Zawie, 1984). Herein, we described some aspects of clinical signs and laboratory findings combined with gross and histopathologic characteristics of exocrine pancreatic adenocarcinoma in a dog.

Case report

A 4-year-old female miniature pincher was referred to Small Animal Hospital, Faculty of Veterinary Medicine, University of Tehran with a history of anorexia and vomiting that had been progressed gradually during 40 days. In addition, icterus, constipation, and sometimes steatorrhea were present in the history. In clinical examination, severe jaundice in mucus membranes—even in the entire skin—combined with abdominal tenderness was obvious. The body temperature of 38.5°C, pulse rate of 180/min and respiratory rate of 20/min were all normal. Leukocytosis and elevations of serum ALP, AST and ALT were considered as the main laboratory abnormalities. Total protein was in lower limit of normal (Table 1). The animal did not improve with initial treatment including cephalexin (30 mg/kg, q8h, PO), sorbitol (3 ml/kg), vit. K (2 mg/kg, IM), vit. B₁₂ (20 µg/kg, IM) and vit. C (50 mg/kg, qd, PO).

Radiographic findings

Plain lateral radiographs were unremarkable. In ventrodorsal view, the C-

loop of duodenum was outlined by a radiolucent gas inside it. Duodenum was also become close to the right abdominal wall. There was soft tissue opacity on the medial side of the duodenum. Stomach was almost empty (Fig. 1). Contrast ventrodorsal view confirmed lateral deviation of duodenum by a soft tissue mass. There were no abnormalities on initial gastric emptying time in both lateral and ventrodorsal radiographs.

Primary radiographic findings were compatible with pancreatic enlargement.

With respect to incompliance of the owner for exploratory laparotomy, broad-spectrum antibiotic therapy was started to control probable septicaemia and pancreatitis. Although at first, there was some improvement in clinical signs, it was transient and with subsequent deterioration of the signs the animal ultimately died after five days.

Pathologic findings

At necropsy, the body was apparently cachectic, oedematous and severely icteric. About 100 ml free bloody fluid without fibrin and clot was found in the abdomen. A firm pale yellow tumour mass originating from the pancreas was present that extended to the duodenum (Fig. 2). The tumour was metastatic and diffuse serosal implants as miliary nodules were present on the omentum, peritoneum and mesenteries. The hepatic and mesenteric lymph nodes were also involved. There were multiple metastatic foci in the liver. The duodenum and the gallbladder were grossly infiltrated with tumour masses. The gallbladder had been distended and occupied with thick bile. It appears that following local infiltrative growth of the tumour, destruction of the common bile duct and widespread metastasis into the hepatic parenchyma lead to compromising of biliary drainage and formation of posthepatic icterus.

At cut surface, the yellow lobulated structure of normal gland was replaced by grayish cirrhotic tissue associated with some areas of necrosis and haemorrhage. The liver was congested, enlarged and extensively involved with fleshy light yellow tumour nodules. The nodules diameters varied from miliary to 1–2 cm. Many of the nodules

Table 1: Haematologic and biochemical findings in the case suspected for exocrine pancreatic adenocarcinoma

		Normal ranges*
PCV (%)	27	37–55
NRBC (%)	10	0–1
WBC (/µl)	47500	8000–17000
Neut. (%)	93	60–70
Band (%)	4	0–4
Lymph. (%)	3	12–30
Total protein (g/dl)	5	5–7.2
Total bilirubin (mg/dl)	4	0–0.6
BUN (mg/dl)	18	10–26
Amylase (IU/L)	735	350–1650
ALP (IU/L)	600	8–76
ALT (IU/L)	135	60–70
AST (IU/L)	130	10–43

*Adapted from Tilley and Smith (2000)

appeared necrotic and haemorrhagic with soft consistency in incised sections (Fig. 2).

Histopathologic examination revealed solid sheets of pleomorphic neoplastic cells with large oval nuclei, prominent nucleoli and coarse chromatin. The cytoplasm of the neoplastic cells were scanty eosinophilic with few zymogenic granules. In some regions, the tumour cells were forming both acinar and tubular structures that resembled exocrine portion of pancreas merging from poorly differentiated region (Figs. 3 and 4).

The nuclear to cytoplasm ratio (N/C) was increased from 1/5 (1/4 to 1/6) in normal cells to 1/1. Karyomegaly, atypical mitotic figures, foci of necrosis and haemorrhages and thrombi were also present. Metastasis to the lymphatic and

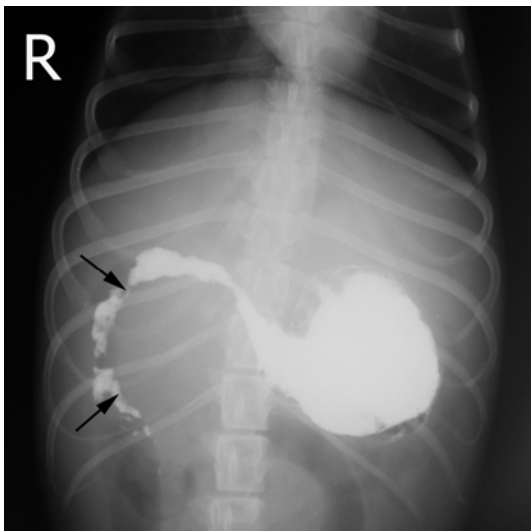


Fig. 1: Ventrodorsal radiograph of the dog. The pylorus is displaced to the left (arrows), and the proximal duodenum is broadly curved due to pancreatic tumour growth

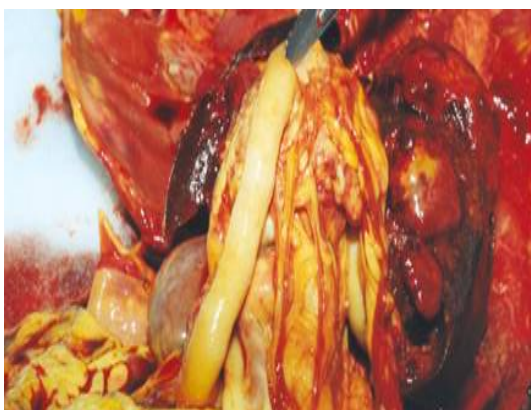

Fig. 2: Macroscopic view of the tumour mass showing severe icterus

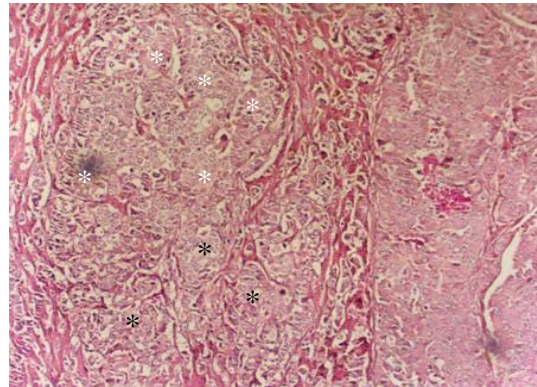


Fig. 3: Microscopic section of exocrine pancreatic adenocarcinoma. Invasion of large masses of neoplastic cells into the hepatic parenchyma. Both acinar (white stars) and tubular structures (black stars) have been formed by neoplastic cells (H&E, ×100)

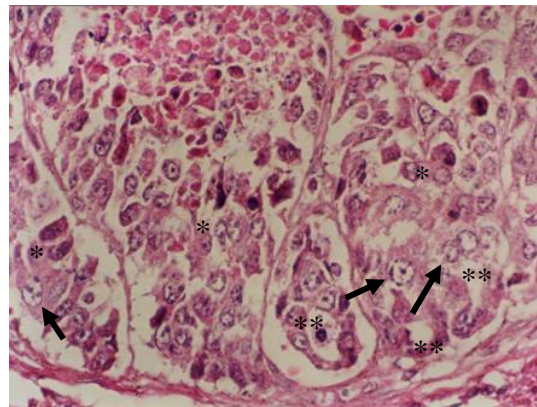


Fig. 4: A microscopic section of exocrine pancreatic adenocarcinoma. The neoplastic cells forms acinar (single stars) and tubular (double stars) structures. Pleomorphism (arrows), karyomegaly (arrows) and necrosis are present (H&E, ×400)

blood vessels especially to the liver was also observed. In Masson's trichrome staining, zymogen acidophilic granules in the cytoplasm of a few cells were observed. These granules resembled spherical and eosinophilic in haematoxyline and eosin stained sections. In ×400 magnification, mitotic index was five mitoses per field. Furthermore, normal hepatic parenchyma was replaced by large masses of neoplastic cells (Fig. 3).

Discussion

The origin of pancreatic adenocarcinomas may be either acinar or ductal, although in most cases they originate from ductal

system (Ettinger and Feldman, 2005). The case presented in this report is unique in that its tumour had both the acinar and ductal schemes (Figs. 2 and 3). The pancreatic adenocarcinomas often have an aggressive behaviour and metastasis is common with implantation on the peritoneum. Metastasis to the liver is also usual either as small nodules or a few large ones. Local lymph nodes may contain metastases; direct invasion to the duodenal wall is also frequent (Jubb *et al.*, 1993). Because of the extensive liver involvement in some dogs, bile duct carcinoma, in contrary to the histopathologic report, may be considered as the probable primary tumour. Similarly, the lymph node, mesenteric, and omental involvement in some dogs is resembled malignant lymphoma in gross appearances (Anderson and Johnson, 1967).

Hepatic involvement is usually indicated by increased serum alkaline phosphatase and bilirubin, with lesser increase in ALT, suggestive of an obstructive hepatopathy (Ettinger and Feldman, 2005). Jaundice and cholestasis are often features of well-established tumours, resulting from obstruction of the bile duct by the tumour and or secondary liver disease. Ascites may also occur as a result of transcoelomic spread of neoplasia or as a consequence of compression of the portal vein and its major branches or in response to hypoproteinaemia (Meuten, 2002). Hypoproteinaemia in this case could be associated with protein loss into the peritoneal space, or loss through the kidney due to immune-complex deposition. The neutrophilia was attributed to either inflammation due to the tumour or tumour necrosis (Bennett *et al.*, 2001).

Concerning other laboratory findings, the results may be unremarkable. Presence of steatorrhoea may be interpreted by exocrine pancreatic insufficiency (EPI) and obstruction of the pancreatic biliary ducts. However, in general, clinical signs or even radiographic and sonographic findings are nonspecific. If peritoneal effusion is identified in abdominal ultrasonography, a sample should be aspirated and evaluated cytologically. Nonetheless, in most cases malignant cells do not readily exfoliate into the peritoneal effusion, and neoplastic cells are not routinely identified on cytology. So

exploratory laparotomy and histopathologic examination of the samples remain the method of choice in definitive diagnosis (Ettinger and Feldman, 2005).

In general, the clinicians should be aware that in cases with long-standing icterus, weight loss and vague signs of gastrointestinal system, especially in middle- and old-aged cases, pancreatic adenocarcinoma should be included in their differential diagnosis. It should also be reminded that at the time of diagnosis in most cases, the tumour often present at a late stage and chemotherapy or radiation therapy have shown little success in human or veterinary patients (Bennett *et al.*, 2001).

Acknowledgement

We thank the late Dr. Reza Naghshineh for his experienced assistance in pathologic diagnosis.

References

- Anderson, NV and Johnson, KH (1967). Pancreatic carcinoma in the dog. *JAVMA*. 150: 286-295.
- Bennett, PF; Hahn, KA; Toal, RL and Legendre, AM (2001). Ultrasonographic and cytopathological diagnosis of exocrine pancreatic carcinoma in the dog and cat. *J. Am. Anim. Hosp. Assoc.*, 37: 466-473.
- Bright, JM (1985). Pancreatic adenocarcinoma in a dog with a maldigestion syndrome. *J. Am. Vet. Med. Assoc.*, 187: 420-421.
- Dill-Macky, E (1993). Pancreatic diseases of cats. *Comp. Cont. Educ. Pract. Vet.*, 15: 589-598.
- Ettinger, SJ and Feldman, EC (2005). *Textbook of veterinary internal medicine*. 6th. Edn., Philadelphia, W. B. Saunders Co., P: 1488.
- Garvey, MS and Zawie, DA (1984). Feline pancreatic disease. *Vet. Clin. N. Am.*, 14: 1231-1246.
- Jubb, KVF; Kennedy, PC and Palmer, N (1993). *Pathology of domestic animals*. Vol. 2, 4th. Edn., San Diego, Academic Press. PP: 417-418.
- Mayer, RJ (1991). Pancreatic neoplasia. In: Wilson, JD; Braunwald, E and Isselbacher, KJ (Eds.), *Harrison's principles of internal medicine*. (14th. Edn.), New York, McGraw-Hill. PP: 1383-1386.
- Meuten, DJ (2002). *Tumors in domestic animals*. 4th. Edn., Ames, Iowa, Iowa State Press. PP: 478-481.

- Poston, GJ; Gillespie, J and Guillou, PJ (1991). Biology of pancreatic cancer. *Gut*. 32: 800-812.
- Tasker, S; Griffon, DJ; Nuttall, TJ and Hill, PB (1999). Resolution of paraneoplastic alopecia following surgical removal of a pancreatic carcinoma in a cat. *J. Small Anim. Pract.*, 40: 16-19.
- Tilley, LP and Smith, FWK (2000). *The five-min veterinary consult (canine and feline)*. 2nd. Edn., Baltimore, Maryland, USA, Williams and Wilkins Pub., PP: 1324-1325.
- Watanapa, P and Williamson, RCN (1993). Experimental pancreatic hyperplasia and neoplasia: effects of dietary and surgical manipulation. *Brit. J. Cancer*. 67: 877-884.
- Withrow, S and Macewen, EG (2001). *Small animal clinical oncology*. 3rd. Edn., Philadelphia, W. B. Saunders Co., PP: 321-323.