

# Morphology and morphometrical study of hamster middle ear bones

Mohammadpour, A. A.

Department of Basic Sciences, Faculty of Veterinary Medicine, Ferdowsi University of Mashhad, Mashhad, Iran

**Correspondence:** A. A. Mohammadpour, Department of Basic Sciences, Faculty of Veterinary Medicine, Ferdowsi University of Mashhad, Mashhad, Iran. E-mail: mohammadpour@ferdowsi.um.ac.ir

(Received 15 Mar 2010; revised version 15 Jan 2011; accepted 16 Jan 2011)

## Summary

The objective of the current study was to determine the anatomical features of the auditory ossicles in hamster. Twenty temporal bones from 10 adult hamsters, weighing 275-300 g were used. After dissecting them, the features of the ossicles were assessed with an ocular micrometer and photographed by a stereomicroscope. Finally, all data were evaluated and analysed using the Sigma Statt software. The auditory ossicles were three bones: the malleus, the incus, and the stapes. The lenticular bone was a distinct bone, articulated with the tip of the long crus of incus. The malleus had an average length of 2.87 mm. In addition to head and handle (manubrium), the malleus had two distinct processes; lateral and muscular. The rostral process was unclear and appeared not developed. The incus had a total length of 1.18 mm. It had long and short crura, the long crus better developed than the short one. The lenticular bone was a round bone that articulated with the long crus of the incus. The stapes had a total length of 0.77 mm. It had a large stapedial base with anterior and posterior crura. The posterior crus was larger than the anterior one. The hole in stapes (obturator foramen) was very large and triangular in shape.

**Key words:** Auditory ossicles, Hamster, Middle ear, Morphology, Morphometry

## Introduction

Ear, the special sensory organ of the body associated with hearing and equilibrium in vertebrates, has three distinct subdivisions referred to as the external, the middle and the inner ear. The auditory ossicles are placed in the dorsal aspect of the tympanic cavity, and are responsible for transmitting air vibrations from the tympanic membrane to the middle and the inner ear. The chain of auditory ossicles of the middle ear has a fundamental role in the transmission of sound, and therefore in animal behavior. The different auditive ability of the various species is also due to the morphological diversity of the auditory ossicles, of their articulations, and of the associated ligaments and muscles. The temporal bone contains the vestibulo-cochlear organ, which is significant in the pathology of humans and animals. Accurate anatomical description of the human ear with all its structures is found in every

anatomy textbook and in specialist monographs. Analogical descriptions of the ear structures of animals, found in veterinary anatomy textbooks, are scarce, schematic and do not go beyond a rough enumeration of the structures, often with no data on topography and variability (Konig and Liebich, 2004; Dyce *et al.*, 2010).

Rodents are one of the most diversified and successful mammalian orders. Not only are they widespread geographically, but they also inhabit many different ecological niches. They have been the subject of many anatomical, physiological, ethological, and ecological studies, and some species have become important models in biomedical research. While experiments on the vestibulocochlear organ in laboratory animals, especially rodents, cover a wide spectrum of problems in the field of experimental and clinical medicine (Bhatt *et al.*, 1991; Kesser *et al.*, 1999; Cagdas, 2005), there are only a few publications dealing with the anatomy of the rodent's ear

(Judkins and Hongyan, 1997). The aim of the present study was to come up with a systematic anatomical description of auditory ossicles in hamster for clinical purposes.

## Materials and Methods

Twenty temporal bones derived from 10 adult hamsters, weighing 275-300 g were used for the study. The animals were obtained from the Razi Institute in Mashhad, Iran and were not deliberately deprived of life, but rather routinely euthanised after the end of other scientific experiments. Thus it was not necessary to acquire permission from the Bioethics Committee. All of the specimens were dissected and examined under a binocular stereomicroscope (Stemi SV 6, Zeiss, Germany), using magnifications of up to  $\times 50$ . After dissecting them, the tympanic parts of the petrosal bones were separated from the heads by dissection and the auditory ossicles were gently removed from their situs. The features of the ossicles were measured with an ocular micrometer and photographed by stereomicroscope.

Finally, data were evaluated and analysed using the Sigma Statt statistics software.

## Results

In this study, the auditory ossicles of the hamster observed were three small bones: the malleus, the incus and the stapes. The lenticular bone was round shaped and articulated with the tip of the long crus of the incus. The diameter of the lenticular bone was 0.2-0.22 mm.

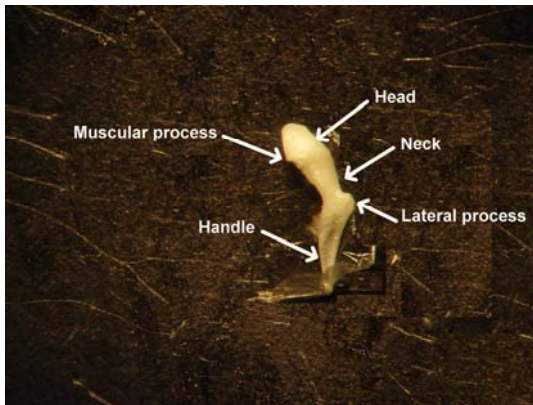
The malleus, the most lateral and largest ( $2.86 \pm 0.02$  mm) of the three bones, had a distinctly developed head mounted on a long neck and a slim handle, considerably thinner than the neck (Fig. 1 and Table 1).

The head ( $1.16 \pm 0.02 \times 0.49 \pm 0.02$  mm) of the malleus was oval shape and articulated with the body of the incus via its prominent articular surface, facing caudally. The articular surface was divided by a small ridge.

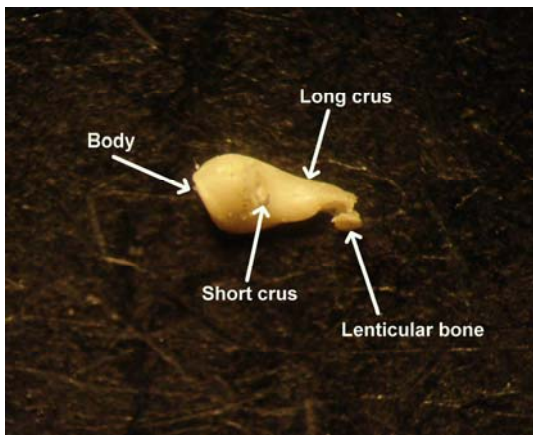
The neck ( $0.19 \pm 0.01 \times 0.29 \pm 0.01$  mm) was a relatively small component of the malleus. It joins the head with the handle, which extends cranially onto the

**Table 1: Morphometric features of the hamster middle ear bones. Data are presented as mean  $\pm$  SD (min-max), n = 10**

| Ear ossicles      | Parameters              | Value (mm)                  |
|-------------------|-------------------------|-----------------------------|
| Malleus           | Total length            | $2.86 \pm 0.02$ (2.83-2.90) |
|                   | Head and neck length    | $1.35 \pm 0.02$ (1.33-1.39) |
|                   | Head length             | $1.16 \pm 0.02$ (1.13-1.18) |
|                   | Head width              | $0.49 \pm 0.02$ (0.45-0.52) |
|                   | Neck length             | $0.19 \pm 0.01$ (0.18-0.22) |
|                   | Neck width              | $0.29 \pm 0.01$ (0.27-0.32) |
|                   | Handle length           | $1.50 \pm 0.02$ (1.47-1.54) |
|                   | Lateral process length  | $0.24 \pm 0.01$ (0.23-0.27) |
|                   | Muscular process length | $0.11 \pm 0.01$ (0.10-0.14) |
|                   | Incus                   | Total length                |
| Body length       |                         | $0.58 \pm 0.01$ (0.57-0.61) |
| Body width        |                         | $0.46 \pm 0.01$ (0.44-0.49) |
| Long crus length  |                         | $0.75 \pm 0.01$ (0.74-0.78) |
| Short crus length |                         | $0.12 \pm 0.01$ (0.10-0.15) |
| Stapes            | Total length            | $0.76 \pm 0.01$ (0.74-0.79) |
|                   | Base length             | $0.89 \pm 0.02$ (0.86-0.93) |
|                   | Base width              | $0.24 \pm 0.01$ (0.23-0.26) |
|                   | Head length             | $0.20 \pm 0.01$ (0.18-0.22) |
|                   | Head width              | $0.12 \pm 0.01$ (0.10-0.14) |
|                   | Anterior crus length    | $0.39 \pm 0.01$ (0.38-0.42) |
|                   | Posterior crus length   | $0.49 \pm 0.01$ (0.47-0.52) |
|                   | Muscular process length | $0.07 \pm 0.01$ (0.05-0.09) |



**Fig. 1: Features of the left malleus in hamster, labelled to illustrate anatomical terms, external view**



**Fig. 2: Features of the left incus in hamster, labelled to illustrate anatomical terms, internal view**

upper half of the tympanic membrane.

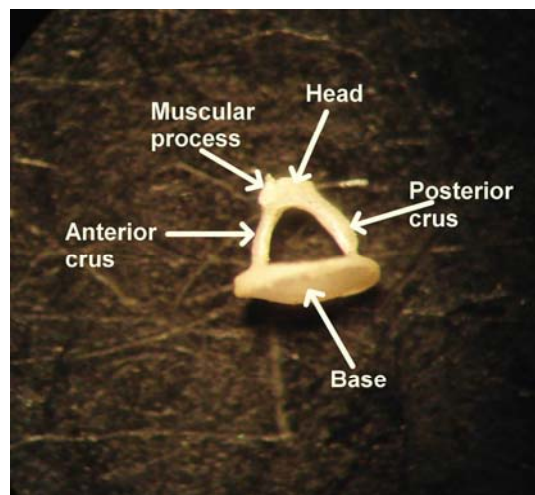
The handle was the longest ( $1.50 \pm 0.02$  mm) element of the malleus. It decreased in size towards its extremity. It was three sided and the side embedded in the tympanic membrane was wider and smoother than the other two.

The malleus had two distinct processes, lateral ( $0.24 \pm 0.01$  mm) and muscular ( $0.11 \pm 0.01$  mm). The rostral process was unclear and not well developed. The lateral process was cone-shaped and it was located in the junction point of the handle and neck. This process was in contact with the tympanic membrane.

The incus was the second of the ossicles. It was smaller ( $1.18 \pm 0.01$  mm) than the malleus, and had a body ( $0.58 \pm 0.01 \times 0.46 \pm 0.01$  mm) and two processes; long and short crura. The body of the incus was

strong and oblong-shaped. It had a laterally articular surface for the head of the malleus. The long crus ( $0.75 \pm 0.01$  mm) was larger than the short crus ( $0.12 \pm 0.01$  mm) and located caudoventrally, almost neighboring to the handle of the malleus. The lenticular bone was round shaped and articulated with the tip of the long crus. The short crus was very small and pointed caudally. (Fig. 2 and Table 1).

The stapes ( $0.76 \pm 0.01$  mm) was the innermost and smallest bone of the middle ear bones. It was triangular in shape, consisting of a head, neck, base (footplate), muscular process and two anterior and posterior crura. The head ( $0.20 \pm 0.01 \times 0.12 \pm 0.01$  mm) of the stapes was oval shaped and was located laterally to meet the lenticular bone that articulated in the tip of the long crus of the incus. The posterior crus ( $0.49 \pm 0.01$  mm) was longer than the anterior crus ( $0.39 \pm 0.01$  mm). Obturator membrane (stapedial membrane) between the crura was large and triangular. The muscular process ( $0.07 \pm 0.01$  mm) was a small prominent in the neck at the origin of the anterior crus. It had a large stapedial base with anterior and posterior crura (Fig. 3 and Table 1).



**Fig. 3: Features of the left stapes in hamster, labelled to illustrate anatomical terms, dorsal view**

## Discussion

The middle ear is housed in the temporal bone and is essentially the small air-filled

space known as the tympanic cavity. It is lined with a thin mucous membrane and communicates with the nasopharynx by the auditory tube. The tympanic cavity may be divided into dorsal, middle and ventral parts. The dorsal part (epitympanic recess) is situated above the level of the tympanic membrane. It contains the chain of auditory ossicles and the two associated muscles. The middle part includes the tympanic membrane in its lateral wall and opens rostrally into the nasopharynx via the auditory tube. The ventral part is an enlarged bulbous extension of the temporal bone known as the tympanic bulla. The bulla varies in prominence among species; in some animals it is subdivided into numerous body cells. The function is not known with certainty but it has been suggested that it may improve the perception of sounds of very low and very high frequencies. The tympanic membrane is a thin partition separating the lumen of the external auditory or acoustic meatus from that of the tympanic cavity. The dorsal part of the tympanic membrane is more lateral than the ventral part, and its surface area is thus considerably larger than that of the transacted external acoustic meatus. The handle of the malleus, the most lateral of the ear ossicles, is embedded in the medial surface of the tympanic membrane (Dyce *et al.*, 2010).

The transmission of sound waves across the tympanic cavity is mediated by the three auditory ossicles known, in lateromedial sequence, as malleus, incus and stapes. The handle of the malleus is embedded in the tympanic membrane so that the head of the malleus protrudes above the membrane by a few millimetres. The head articulates with the body of the incus and the latter articulates with the head of the stapes by means of its long crus. The base of the stapes sits in the vestibular window in the medial wall of the tympanic cavity (Konig and Liebich, 2004; Dyce *et al.*, 2010).

Otological research frequently requires the use of experimental models, mainly guinea pigs, hamsters and rats because they are easy to handle and their ears are similar to those of humans.

Knowledge about the anatomy of the ears from these animals is paramount in the field of otology. A better use of these

animals makes the results attained more reliable, avoiding the use of techniques which are not adequate for a certain species and, thus, causing unnecessary morbidity and mortality to a large number of animals.

Most of the research in the medical field is undertaken with small size animals (mice, rats, hamsters, guinea pig or gerbil) and comprehend almost 90% of all the species of animals used in a laboratory (Schanaider and Silva, 2004). Regarding the labyrinthine system, the guinea pig hearing and vestibular systems are very similar to those of humans, and it is an animal that is very good for experiments with the labyrinth (Oliveira, 1989).

There are general anatomic explanations about the middle ear ossicles in anatomy textbooks. However, there are no studies in the literature on the morphology of auditory ossicles in the hamster. The auditory ossicles of hamster had a similar topography with respect to the same in the other rodents (Barone *et al.*, 1973; McLaughlin and Chiasson, 1990; Wysocki, 2008).

In hamster, the lenticular bone was round shaped and articulated with the tip of the long crus. The connection between the long process and the lenticular process of the incus is extremely fine, in a way that some authors have treated the lenticular process as a separate bone. The region is important clinically as a frequent point of attachment for prostheses. It is also important in determining how sound is transmitted from the incus to the stapes. The nature of the bony pedicle may also be important in modelling the mechanics of the ossicular chain. The author suggested that the pedicle may bend significantly, and may even provide more flexibility than the actual incudostapedial joint does to the coupling between the incus and the stapes. This model-based prediction of significant bending of a bony part of the middle ear is reminiscent of the prediction of manubrial bending (Funnell *et al.*, 1992; Robert *et al.*, 2004).

Shrapnell (1832) in human ear observed that the “most generally received opinion appears to be that it is a separate bone” and proceeded to illustrate convincingly that such is not the case. He clearly showed the bony pedicle joining the lenticular plate to

the long process of the incus. The pedicle is shown to be four or five times wider in one direction than in the other, and somewhat curved.

Descriptions of the lenticular process in other species have been few, and they have often been unspecific and ambiguous. Doran (1878) referred to it as an apophysis, or perhaps epiphysis, of the incus. Henson (1961) described middle-ear structures in three insectivores and eight bats; his overall description of the lenticular process was as "a small cartilaginous disk mounted on an osseous pedicle".

Trauma of the ossicular chain is a frequently seen complication of temporal bone injury (Meriot *et al.*, 1997). As a result, recent studies have focused on the reconstruction of defects occurring in these ossicles (Mills, 1996). To aid in the development of new surgical techniques, researchers have studied the ossicular chain of several animals (Masuda *et al.*, 1986; Vrettakos *et al.*, 1988; Judkins and Li, 1998).

In summary, as there was a lack of detailed data on the auditory ossicles in the hamster, this study made an effort to obtain detailed features of the ossicles in the hamster for experimental otologic studies.

## Acknowledgements

The author wishes to express his appreciation to the Research Council of the Ferdowsi University of Mashhad for the financial support (Research project No:14351). I also wish to thank Mr. M. Zare for his assistance.

## References

- Barone, R; Pavaux, C; Bilin, PC and Cuq, P (1973). *Atlas of rabbit anatomy*. 2nd Edn., Paris, Mason and Cie Editeurs. PP: 183-184.
- Bhatt, S; Halpine, C; Hsu, W; Thedinger, BA; Levine, RA; Tuomanen, E and Nadol, JB (1991). Hearing loss and pneumococcal meningitis: an animal model. *Laryngoscope*. 101: 1285-1292.
- Cagdas, KK (2005). The role of experimental myringosclerosis in interpretation of tympanograms and its possible clinical implications. *Med. Hypotheses*. 64: 1132-1134.
- Doran, AHG (1878). *Morphology of the mammalian Ossicula auditûs*. 2nd Edn., Vol. I, London, Transactions, Linnean Society. PP: 371-497.
- Dyce, KM; Sack, WO and Wensing, CJG (2010). *Textbook of veterinary anatomy*. 4th Edn., Philadelphia, W. B. Saunders Co., PP: 346-351.
- Funnell, WRJ; Khanna, SM and Decraemer, WF (1992). On the degree of rigidity of the manubrium in a finite-element model of the cat eardrum. *J. Acoust. Soc. Am.*, 91: 2082-2090.
- Henson, OWJ (1961). Some morphological and functional aspects of certain structures of the middle ear in bats and insectivores. *Univ. Kansas Sci. Bull.*, 42: 151-255.
- Judkins, RF and Hongyan, L (1997). Surgical anatomy of the rat middle ear. *Otolaryngol Head Neck Surg.*, 117: 438-447.
- Judkins, RF and Li, H (1998). Surgical anatomy of the rat middle ear. *Otolaryngol Head Neck Surg.*, 117: 438-447.
- Kesser, BW; Hashisaki, GT; Spindel, JH; Ruth, RA and Scheld, WM (1999). Time course of hearing loss in an animal model of pneumococcal meningitis. *Otolaryngol Head Neck Surg.*, 120: 628-637.
- Konig, HE and Liebich, HG (2004). *Veterinary anatomy of domestic animals: textbook and color atlas*. 1st Edn., Stuttgart, Germany, Schattauer Co., PP: 284-286.
- Masuda, Y; Honjo, H; Naito, M and Ogura, Y (1986). Normal development of the middle ear in the mouse: a light microscopic study of serial sections. *Acta Med. Okayama*. 40: 201-207.
- McLaughlin, CA and Chiasson, RB (1990). *Laboratory anatomy of the rabbit*. 3rd Edn., Boston, McGraw and Hill. PP: 99-100.
- Meriot, P; Veillon, F; Garcia, JF; Nonent, M; Jezequel, J; Bourjat, P and Bellet, M (1997). CT appearances of ossicular injuries. *Radiographics*. 17: 1445-1454.
- Mills, RP (1996). Physiological reconstruction of defects of the incus long process. *Clin. Otolaryngol.*, 21: 499-503.
- Oliveira, JAA (1989). *Audio-vestibular toxicity of drugs*. 2nd Edn., Florida, CRC Press. P: 560.
- Robert, W; Funnell, J; Heng Siah, T; McKee, MD; Daniel, SJ and Decraemer, WF (2004). On the coupling between the incus and the stapes in the cat. *JARO*, PP: 1-15.
- Schanaider, A and Silva, PC (2004). Uso de animais em cirurgia experimental. *Acta Cir. Bras.*, 19: 441-447.
- Shrapnell, HJ (1832). *On the structure of the Os incus*. 1st Edn., London Medical Gazette. PP:

171-173.  
Vrettakos, PA; Dear, SP and Saunders, JC  
(1988). Middle ear structure in the chinchilla:  
a quantitative study. *Am. J. Otolaryngol.*, 9:  
58-67.

Wysocki, J (2008). Topographical anatomy and  
measurements of selected parameters of the  
rat temporal bone. *Folia Morphol.*, 67: 111-  
119.