



**IJVR**

ISSN: 1728-1997 (Print)  
ISSN: 2252-0589 (Online)

**Vol. 19**

**No. 1**

**Ser. No. 62**

**2018**

**IRANIAN  
JOURNAL  
OF  
VETERINARY  
RESEARCH**



## Letter to Editor

## 3-D computed tomography reconstruction: another tool to teach anatomy in the veterinary colleges

Jaber, J. R.<sup>1\*</sup>; Carrascosa, C.<sup>2</sup>; Arencibia, A.<sup>1</sup>; Corbera, J. A.<sup>2</sup>;  
Ramirez, A. S.<sup>2</sup> and Melian, C.<sup>2</sup>

<sup>1</sup>Department of Morphology, Faculty of Veterinary Medicine, Universidad de Las Palmas de Gran Canaria, Spain; <sup>2</sup>Department of Pathology and Food Technology, Faculty of Veterinary Medicine, Universidad de Las Palmas de Gran Canaria, Spain

\*Correspondence: J. R. Jaber, Department of Morphology, Faculty of Veterinary Medicine, Universidad de Las Palmas de Gran Canaria, Canary Islands, 35413, Trasmontaña, Spain. E-mail: joserraduan.jaber@ulpgc.es

(Received 12 Jun 2017; revised version 7 Dec 2017; accepted 20 Dec 2017)

### Dear Editor,

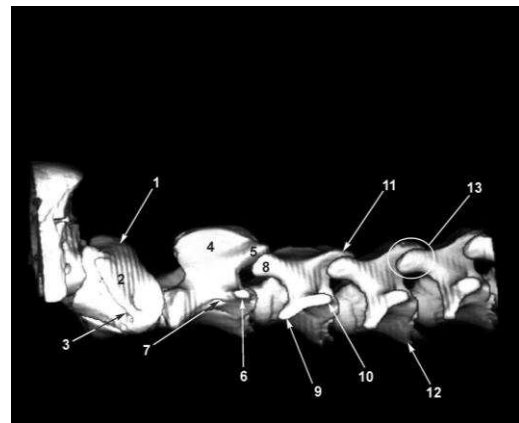
This letter underpins the use of three-dimensional computed tomography (3D-CT) reconstruction as an aid to teach veterinary anatomy. Cases were presented to students in order to observe normal and clinically abnormal patients. The images provided excellent details of relevant structures and could serve as a tool for teaching anatomy.

Many sources describe different options to enhance anatomical learning by students through the use of modern imaging techniques such as computed tomography (CT) or magnetic resonance (MR) imaging.

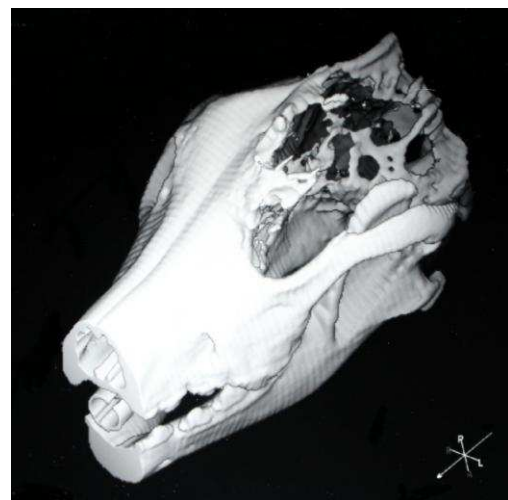
The contribution of CT to anatomical knowledge is limited due to the high cost and the lack of a suitable design for large animals, although recently studies have been reported on foals head (Cabrera *et al.*, 2015). Advances in CT studies involve the generation of 3D-CT of the canine spine (Drees *et al.*, 2009), the sea lion head (Dennison and Schwarz, 2008), or orbital diseases (Zafra *et al.*, 2012). This study reports examples of this technique and its contribution to the understanding by the students.

The CT images were obtained at the Veterinary Hospital of Las Palmas University from different cases. Transverse images were obtained using fourth generation CT equipment. Each patient was subjected to 3D reconstruction using a standard DICOM 3D format.

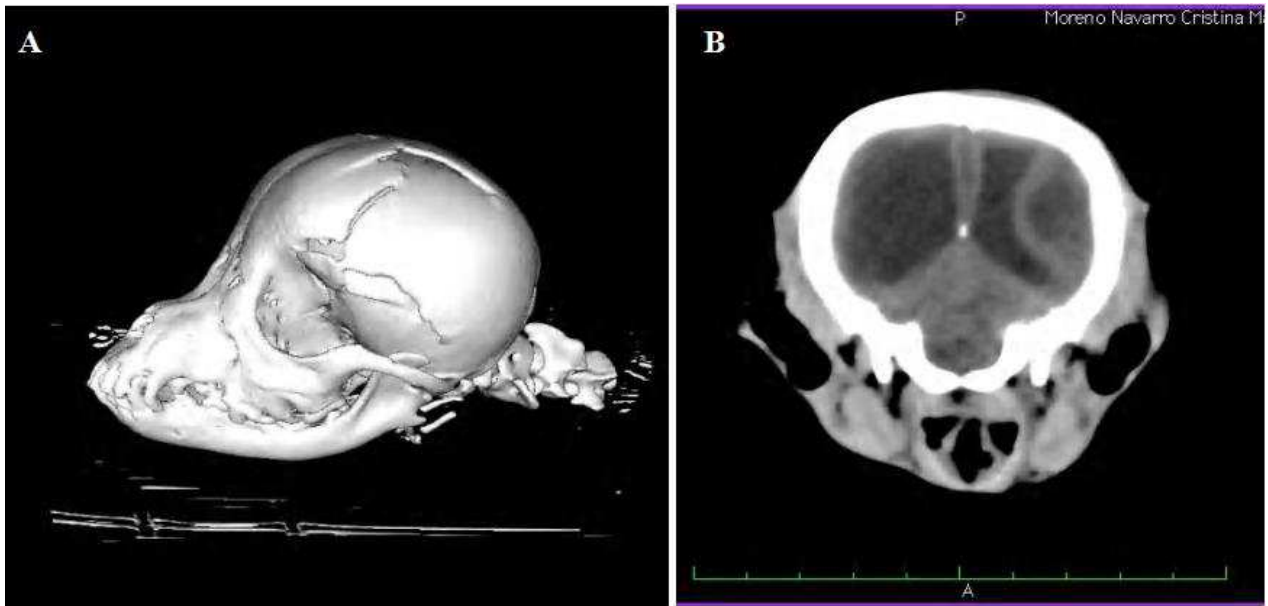
The images were showed to a group of 20 students that had completed their basic training by learning anatomy through computer simulations. They could label relevant structures of the cervical spine of foal, including the atlas and its occipital articulation and the modified spinous process of axis (Fig. 1). In relation to the dog head, the 3D-CT showed the extent of the bony lesions, occupying the orbital region. It affected the maxillary border of the zygomatic and frontal bone (Fig. 2). In the last case, students visualized fractures of the dogskull. Additional transverse image showed contusional hemorrhage in the left parietal lobe and dilatation of lateral ventricles (Fig. 3).



**Fig. 1:** 3D-CT of the foal cervical spine. **1.** Dorsal arch of atlas, **2.** Wing of atlas, **3.** Transversal foramen of atlas, **4.** Spinous process of axis, **5.** Caudal articular process of axis, **6.** Transversal process of axis, **7.** Transversal foramen of axis, **8.** Cranial articular process of third vertebra, **9.** Ventral tubercle of transverse process of third vertebra, **10.** Dorsal tubercle of transverse process of third vertebra, **11.** Caudal articular process of third vertebra, **12.** Ventral crest on vertebrae body, and **13.** Joint between articular processes



**Fig. 2:** 3D-CT of the dog skull. Extraorbital mass involvement, focused on frontal and parietal areas, showing bone lysis and cranial cavity invasion



**Fig. 3:** Dog with multiple fractures, (A) these can be seen involving supra-orbital margin, as well as the left temporal, parietal and frontal bones (3D image). (B) Contusional hemorrhage in the left parietal lobe and severe hydrocephalus (transverse image)

The 3D-CT images provided better understanding of the anatomical CT cross-sections. The possibilities of 3D-reconstructions have been demonstrated by generating virtual casts of specific areas from different specimens.

In conclusion, 3D-CT may facilitate teaching veterinary anatomy to students by allowing the view of structures in a realistic manner without superimposition of other structures, eliminating the difficulties of visualizing the extension of different types of lesions.

## References

Cabrera, L; Arencibia, A; Rizkallal, C; Blanco, D; Farray,

D; Díaz-Bertrana, ML; Carrascosa, C and Jaber, JR (2015). Computed tomographic imaging of the brain of normal neonatal foals. *Arch. Med. Vet.*, 47: 209-214.

Dennison, SE and Schwarz, T (2008). Computed tomographic imaging of the normal immature California sea lion head. *Vet. Radiol. Ultrasound.*, 49: 557-563.

Drees, R; Dennison, SE; Keuler, NS and Schwarz, T (2009). Computed tomographic imaging protocol for the canine cervical and lumbar spine. *Vet. Radiol. Ultrasound.*, 50: 74-79.

Zafra, R; Carrascosa, C; Suarez-Bonnet, A; Melián, C; Fernández, T; Monzón, M; Quesada, O; Suarez, F and Jaber, JR (2012). Three-dimensional reconstruction by computed tomography of an undifferentiated sarcoma in a dog. *J. Appl. Anim. Res.*, 40: 289-291.