

The superiority of paracostal endoscopic-assisted gastropexy over open incisional and belt loop gastropexy in dogs: a comparison of three prophylactic techniques

Tavakoli, A.^{1*}; Mahmoodifard, M.^{1,2} and Razavifard, A. H.³

¹Department of Clinical Sciences, Faculty of Veterinary Medicine, Garmsar Branch, Islamic Azad University, Garmsar, Iran;

²Resident of Veterinary Surgery, Department of Clinical Sciences, School of Veterinary Medicine, Shiraz University, Shiraz, Iran;

³Graduated from Faculty of Veterinary Medicine, Garmsar Branch, Islamic Azad University, Garmsar, Iran

*Correspondence: A. Tavakoli, Department of Clinical Sciences, Faculty of Veterinary Medicine, Garmsar Branch, Islamic Azad University, Garmsar, Iran. E-mail: azin.tavakoli@gmail.com

(Received 28 Jun 2015; revised version 7 Nov 2015; accepted 14 Dec 2015)

Summary

Prophylactic gastropexy is a procedure that prevents the occurrence of a life threatening condition known as gastric dilation and volvulus (GDV) in dogs. The objective of this study was to compare incisional, belt loop and minimally invasive endoscopically assisted gastropexy by evaluating different parameters such as surgical time, length of scar and score of pain in dogs. Twenty-one healthy, mixed-breed adult dogs weighting 14.3 ± 2.6 kg were randomly divided into three groups. Three gastropexy techniques applied in the following order: incisional (group I), belt loop (group B), and endoscopically assisted gastropexy (group E). Surgical time, anesthetic time, length of surgical incision and score of pain 3 h after surgery were recorded for all dogs. Two weeks after the surgery, positive-contrast gastrography was used to evaluate stomach position and total gastric emptying time. Ultrasonography was also used to evaluate the gastropexy two months after the surgery. Adhesion was confirmed two months after the surgery between the stomach wall at the pyloric antrum and the right side of the body wall in all dogs by ultrasound. The mean surgical time, length of surgical incision and score of pain were significantly lower in group E compared to group I and B ($P < 0.05$). No significant differences were found in total gastric emptying time and gastropexy thickness post-operatively ($P > 0.05$). Due to advantages observed in the current study, the endoscopically assisted technique seems to be a suitable alternative to open incisional and belt loop gastropexies for performing prophylactic gastropexy, especially when performed by skilled surgeons.

Key words: Canine, GDV, Minimally invasive, Prophylactic gastropexy

Introduction

Prophylactic gastropexy, which is a preventive procedure highly recommended by veterinarians, prevents the occurrence of a life threatening condition known as gastric dilation and volvulus (GDV) in dogs. Gastropexy is performed in all patients with GDV to prevent the recurrence of the disease. Previous studies suggest a recurrence rate of 70% and a mortality rate of 80% if gastropexy is not performed in the affected patient (Eggertsdottir and Moe, 1995; Rasmusen, 2003; Fossum, 2007).

Gastric dilation and volvulus most often affect large and giant-breed dogs with deep and narrow chests such as Great Danes, Saint Bernards, Weimaraners, Irish Setters, Gordon Setters, Standard Poodles, Basset Hounds, Doberman Pinschers, Greater Swiss Mountain dogs and Old English sheepdogs (Waschak *et al.*, 1997; Monnet, 2003). Other risk factors associated with the development of GDV are age, ingesting large amounts of food or water, eating rapidly or from an elevated food dish, fearful temperament and exercise after eating (Glickman *et al.*, 1997; Raghavan *et al.*, 2004). Dogs with a higher thoracic depth to width ratio are believed to have a higher risk of developing bloat, which facilitates the development of GDV (Schellenberg, 1998).

Additionally, studies show that having a first-degree relative of dogs affected with GDV increases the risk of this condition (Glickman *et al.*, 2000). The costs associated with the treatment of GDV should also be considered. Prophylactic gastropexy is strongly recommended in dogs with higher risks of developing GDV.

Many gastropexy techniques have been described for dogs, their objective being to create a permanent and strong adhesion of the stomach to the abdominal wall to prevent the stomach from rotating on its axis when it dilates. Incisional gastropexy is a fast and simple procedure that results in the long-term adhesion of the stomach to the body wall. This easy technique involves apposing the muscular layer of the gastric wall and the right transverse abdominis muscle (Waschak *et al.*, 1997; Wacker *et al.*, 1998; Monnet, 2003). This technique is reported to be associated with few post-operative complications (MacCoy *et al.*, 1982; Hardie *et al.*, 1996; Waschak *et al.*, 1997; Tanno *et al.*, 1998).

Belt-loop gastropexy results in a strong adhesion between the stomach and abdominal wall as well (Fossum, 2007). A seromuscular flap of the stomach is elevated and passed through a tunnel in the muscular layer of the abdomen. Minimal complications have been reported; however, pneumothorax can occur sub-

sequently (Rasmusen, 2003).

Alternative procedures to prophylactic gastropexy are minimally invasive veterinary surgeries such as aparoscopic - and endoscopic - assisted gastropexy. Laparoscopic assisted gastropexy has been shown to create a permanent and strong adhesion between the stomach and the body wall. However, it requires expensive laparoscopic equipment and expertise (Wilson *et al.*, 1996; Rawlings *et al.*, 2001; Rivier *et al.*, 2011). Dujowich *et al.* (2010) reported endoscopically assisted gastropexy to be a simple, fast, safe, and reliable method of performing prophylactic gastropexy in dogs. Smaller incisions, less pain and quicker recovery make this minimally invasive procedure a remarkable and appealing option for prophylactic gastropexy in dogs with high risks of developing GDV in their lifetime (Mayhew and Brown, 2009). Due to the fact that the procedure is minimally invasive, the results are more satisfactory for the owners who expect less discomfort for their dog.

Theoretically speaking, the disadvantage of minimally invasive endoscopic assisted gastropexy is that the location of the gastropexy relative to the stomach is blind when compared to either open or laparoscopic techniques, hence causing the possible malpositioning of the stomach. This study was conducted to compare the two common gastropexy techniques, the incisional and the belt loop technique, with a minimally invasive endoscopically assisted gastropexy in dogs, and to evaluate the feasibility, safety and possible complications of such procedure.

Materials and Methods

Animals

Twenty-one healthy, mixed-breed, adult dogs weighting 14.3 ± 2.6 kg were used in this experiment after approval of the University Research Committee in accordance with the guidelines of its Institutional Animal Experimentation Ethics Committee. The dogs were randomly assigned to three different groups, with seven dogs each in the following order:

Group I: Incisional gastropexy

Group B: Belt loop gastropexy

Group E: Endoscopic assisted gastropexy

Food was restricted 8 h prior to surgery for all animals. Acepromazine (0.05 mg/kg, IM [Neurotranq[®], Alfasan, Woerden-Holland]) was used as premedication and general anesthesia was induced by IV administration of a combination of diazepam (0.22 mg/kg [Zepadic[®], Caspian Tamin Pharmaceutical Co., Rasht, Iran]) and ketamine (6 mg/kg [Ketalar[®], Alfasan, Woerden, Holland]). Isoflurane (1.7%) [Nicholas Piramal Limited, London, UK] in 100% Oxygen was used to maintain anesthesia. Cefazolin (22 mg/kg, IV [Cefazex[®], Loghman pharmaceutical Co., Tehran, Iran]) was used as prophylaxis when anesthesia was induced. After the induction of general anesthesia, the abdominal area from the xiphoid to the pubis of each selected dog was prepared for the aseptic surgery. The same surgeon

performed all surgeries.

Surgical technique

Group I: Incisional gastropexy

Midline celiotomy was performed in group I with the stomach in normal position, and the pyloric antrum was located. A 4 to 5-cm incision was then made through the seromuscular layer of the pyloric antrum. The incision was parallel to the longitudinal axis of the stomach, midway between the greater and lesser curvatures. Care was taken to avoid penetrating the lumen during gastric incision. Next, a 4 to 5 cm full thickness incision angling from the craniodorsal to the caudoventral, through the peritoneum and superficial musculature of the right ventrolateral body wall, caudal to the last rib and 6 to 8 cm to the right of the midline was made through the right abdominal wall. The gastric and abdominal wall incisions were apposed using 2-0 polyglycolic acid sutures with a simple continuous suture pattern. Initially, the dorsal portions of both incisions were sutured together and the ventral portion of the incisions were apposed. The abdominal incision was closed in three layers of linea alba, subcutaneous, and skin.

Group B: Belt loop gastropexy

Midline celiotomy was performed in group B as well. After the pyloric antrum was located with the stomach in its normal position, a 5 cm long and 4 cm wide seromuscular flap of the gastric antrum was elevated. Afterwards, two 5 cm transverse and full thickness incisions were made in the right ventrolateral abdominal wall. The incisions were 4 cm apart. Forceps were then used to make a tunnel under the abdominal muscles through the parallel incisions. A stay suture was placed at the edge of the gastric flap to pass the flap under the created tunnel in the abdominal musculature. Finally, the flap was sutured on its original gastric margin with a 2-0 polyglycolic acid suture using simple continuous sutures (Fig. 1). Care was taken not to traumatize the edge of the flap while it was being passed under the abdominal muscle flap. The abdominal incision was closed in three layers of linea alba, subcutaneous and skin.

Group E: Endoscopic assisted gastropexy

Prior to the study the pilot experience was performed using endoscopic assisted gastropexy on two dogs. The purpose was to recognize and evaluate the pyloric antrum through an endoscope and to experience the technique.

A 120 cm flexible video endoscope was inserted from the oral cavity and upper gastric endoscopy was performed. The endoscope entered the pyloric antrum, and the pyloric antrum and pylorus were located. Next, percutaneous stay sutures were placed to grasp the gastric wall at the right cranioventral abdominal wall using a 10 cm curved needle to perform a temporary gastropexy. The endoscopic light was used as a guide. The gastric wall was then pushed from the outside and percutaneous seromuscular gastric sutures were placed while we visualized the procedure through the video

(Fig. 2). The sutures were placed at the beginning and end point of the gastropexy line. The sutures were approximately 7 cm apart. The skin, abdominal muscles and the seromuscular layer of the gastric wall were then incised separately without entering the gastric lumen (Fig. 3). The incision was paracostal, located at the right proximal abdomen. The gastric and abdominal wall incisions were apposed using a 2-0 polyglycolic acid suture with a simple continuous suture pattern. Initially, the lateral portions of both incisions were sutured together. The medial portions of the incisions were then apposed (Fig. 4). Finally, stay sutures of the temporary gastropexy were removed and the abdominal incision was closed in three layers of abdominal musculature, subcutaneous and skin.

Measured parameters

Surgical time (time from starting the skin incision to turning off the vaporizer), anesthetic time (time from loss of consciousness to sternal recumbency), length of surgical incision (length between the beginning and ending points of the incision) and score of pain using UMPS (University of Melbourne Pain Scale, [Firth and Haldane, 1999]) 3 h after the surgery were recorded in all dogs. Two weeks after the surgery positive-contrast gastrography was used to evaluate stomach position and total gastric emptying time. Ultrasonography was also used to evaluate the gastropexy site two months after the surgery. The distance between the gastropexy line and the last rib was measured in all dogs to determine the

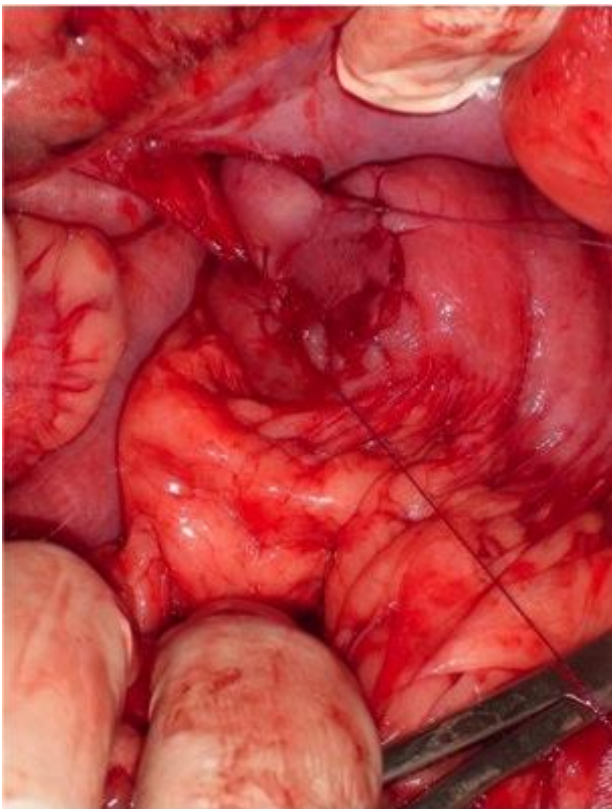


Fig. 1: The elevated seromuscular gastric flap was sutured on its original gastric margin in group B, for which belt loop gastropexy was performed

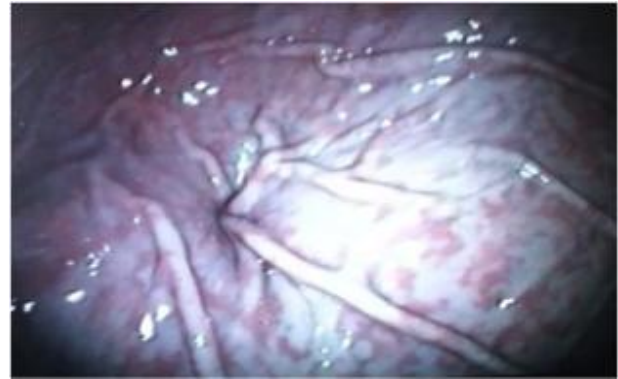


Fig. 2: Percutaneous seromuscular gastric sutures were placed while they were visualized through video using endoscopic assisted gastropexy in group E, for which endoscopic assisted gastropexy was performed

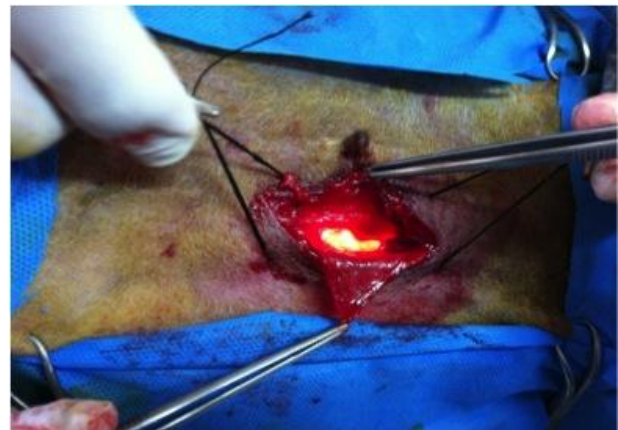

Fig. 3: The skin, abdominal muscles and seromuscular layer of the stomach wall were incised in group E (endoscopic assisted gastropexy). Note the endoscopic light that could be observed from outside

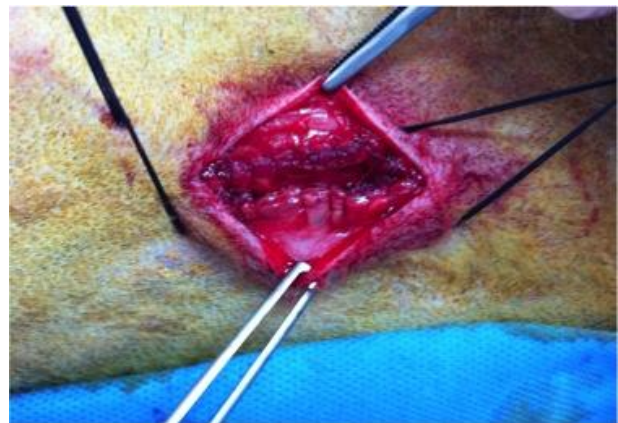

Fig. 4: Gastric and abdominal wall incisions were apposed using simple continuous sutures while performing endoscopic assisted gastropexy in group E (endoscopic assisted gastropexy)

location of the gastropexy from the ribs.

Results

No complication occurred during or after surgery in

any group. Ultrasound confirmed adequate adhesion of the stomach and body wall two months after the surgery in all dogs. For two group E dogs, needles were bent while the stomach wall was being grasped. Mean surgical time was significantly shorter in group E compared to groups I and B ($P < 0.05$). However, anesthesia time did not differ significantly among any of the three groups ($P > 0.05$). The score of pain 3 h after surgery was significantly lower in group E ($P < 0.05$). No significant differences were found in total gastric emptying time and gastropexy thickness post operatively

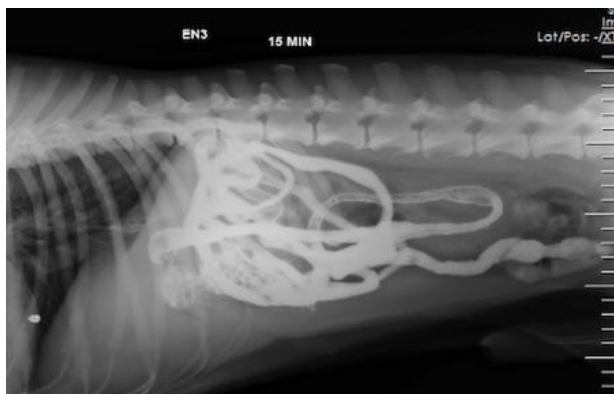

Fig. 5: Positive-contrast radiography 15 min after the passage of the contrast media from the esophagus indicated normal gastric emptying time and the normal position of the stomach in the lateral position in a group E patient

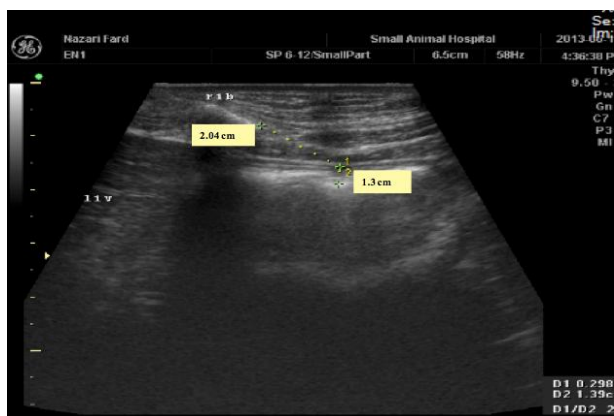


Fig. 6: The distance between the gastropexy site and the last rib (2.04 cm) (1) and the gastropexy thickness (1.30 cm) (1-2) were measured in ultrasonographic examinations in group E patients

in radiographic and ultrasonographic examinations ($P > 0.05$). The distance between the gastropexy site to the last rib did not significantly differ among the patients of group E (Fig. 5). The measured parameters are summarized in Table 1.

Ultrasound revealed that the right side of the stomach wall at the pyloric antrum was firmly attached to the right side of body wall in all dogs and that the stomach was not malpositioned. The stomach wall was thicker at the gastropexy site and the pylorus was normal in all dogs (Fig. 6).

Discussion

Gastric dilation and volvulus is a life threatening condition; however, its occurrence could be predicted in specific dog breeds considering the risk factors (Glickman *et al.*, 1998; Glickman *et al.*, 2000; Raghavan *et al.*, 2004). Prophylactic gastropexy not only prevents the disease and its consequent distress in dogs but also reduces the cost of treatment (Ward *et al.*, 2003). Endoscopically assisted gastropexy is believed to have the benefits of minimally invasive surgery, such as decreasing morbidity rate and anesthetic time (Dujowich and Reimer, 2008).

Two open and commonly used prophylactic procedures, gastropexy and endoscopically assisted gastropexy were compared in this experiment. Mean surgical time and length of incision were significantly shorter in group E compared to groups I and B. Score of pain 3 h after the surgery was also significantly lower in group E compared to the other groups. Mean surgical time of the endoscopically assisted technique was comparable to other available reports; however, time can decrease dramatically as the surgeon gains more experience (Dujowich and Reimer, 2008; Dujowich *et al.*, 2010).

All gastropexies were firmly adhered to the abdominal wall by two weeks after the surgeries. Two months after the surgery, the stomach was located in its normal position in all patients of the three groups. Gastropexy location can influence gastric emptying time. When the angle between the duodenum and pyloric antrum is too acute, gastric outflow obstruction might occur (Hall *et al.*, 1992; Jennings *et al.*, 1992; Tanno *et al.*, 1998). Although subclinical, temporary decrease in gastric motility has been reported after gastropexy due to

Table 1: Results of the assessed parameters among the study groups, mean \pm SD

Parameter	Group I	Group B	Group E
Surgical time (min)	39.6 \pm 2.7	49.2 \pm 3.7	24.2 \pm 3.7*
Anesthesia time (min)	95 \pm 11.7	106 \pm 12.94	93 \pm 5.7
Length of surgical incision (cm)	11.7 \pm 1.3	12 \pm 0.93	4.3 \pm 0.44*
Total gastric emptying time (min)	9 \pm 2.23	11 \pm 2.23	10 \pm 3.53
Distance to the last rib (cm)	2.22 \pm 0.23	2.54 \pm 0.32	1.9 \pm 0.12
Pain score	12.4 \pm 1.67	12.4 \pm 2.3	6.6 \pm 0.54*
Gastropexy thickness (cm)	1.18 \pm 0.19	0.84 \pm 0.11	1.26 \pm 0.35

$P < 0.05$ was considered statistically significant. * Statistically significant at $P < 0.05$. I: Incisional gastropexy, B: Belt loop gastropexy, and E: Endoscopic assisted gastropexy

the overstretching of the gastric muscles (Hall *et al.*, 1992; Wacker *et al.*, 1998). Therefore, the proper location of the gastropexy site is critical to normal stomach motility. It is believed that the gastropexy location is blind in the endoscopically assisted technique compared to open and laparoscopic techniques. However, in the present study, no problems were encountered when locating the gastropexy site in endoscopically assisted gastropexy, because visualizing the pyloric antrum through the video facilitated locating the gastropexy site in the proper position in an un-dilated stomach. As a result, no delay was noted in total gastric emptying time in either of the groups and pylorus was normal.

Our study has a number of limitations. Although GDV is reported to occur more frequently in specific dog breeds, where bloating condition differ, our experiment was a trial of mixed-breed dogs. In addition, a long-term follow up of the patients could have improved our results. In other words, since we had limited access to the animals' information after discharge, the clinical trial and long-term prospective studies of the endoscopic assisted gastropexy could not be conducted. Moreover, post-operative CT scans of the abdomen were not accessible. If available, they could have provided more detailed and precise information about any displacement of the stomach.

Prophylactic gastropexy is more cost-effective when compared to the costs of treating GDV in dogs with higher risks of developing the condition (Ward *et al.*, 2003). The recommended time to perform this procedure is when the animal is being neutered or is undergoing other abdominal surgeries (Rivier *et al.*, 2011). Nevertheless, it is difficult to encourage dog owners to perform prophylactic surgery for dogs that are not scheduled for open abdominal surgery. In such cases, minimally invasive techniques appear to be more reasonable.

There are other valuable aspects to this study. To the best of our knowledge, no study has compared minimally invasive prophylactic gastropexy techniques with the more commonly performed open procedures. Considering the advantages of endoscopic assisted prophylactic gastropexy, including cost-effectiveness, shorter duration of surgery and anesthesia and lower pain level, the result of this study can be valuable for small animal practitioners.

The reason that discourages veterinarians from recommending laparoscopic gastropexy is the expensive equipment and advanced training required to conduct it. Dujowich *et al.* (2010) reported that endoscopically assisted gastropexy is easy to perform. Therefore, the more experience the surgeon obtains, the less likely they are to face problems with this surgical technique. Also, since abdominal organs are less manipulated during the procedure in comparison to open techniques, the dogs suffer less pain and stress after surgery.

Endoscopically assisted gastropexy is a reliable method of prophylactic gastropexy. It is feasible, quick and easy to perform and avoids post-surgery discomfort

in dogs. Since the technique is easy to apply, it has a very short learning curve. Also, the appropriate location of gastropexy, adequate adhesion, and shorter length of the surgical incision, have made it superior to other compared methods. Because of its advantages, the endoscopically assisted technique is a suitable alternative to open incisional and belt loop gastropexies, especially if performed by a skilled surgeon.

Acknowledgement

The authors would like to thank Dr. Molazem for his sincere help in interpreting radiological and ultrasound data.

References

- Dujowich, M; Keller, ME and Reimer, SB (2010). Evaluation of short- and long-term complications after endoscopically assisted gastropexy in dogs. *J. Am. Vet. Med. Assoc.*, 236: 177-182.
- Dujowich, M and Reimer, SB (2008). Evaluation of an endoscopically assisted gastropexy technique in dogs. *Am. J. Vet. Res.*, 69: 537-541.
- Eggertsdottir, AV and Moe, L (1995). A retrospective study of conservative treatment of gastric dilatation-volvulus in the dog. *Act. Vet. Scand.*, 36: 175-184.
- Firth, AM and Haldane, SL (1999). Development of a scale to evaluate post-operative pain in dogs. *J. Am. Vet. Med. Assoc.*, 214: 651-659.
- Fossum, TW (2007). Surgery of the digestive system. *Small animal surgery*. (2nd Edn.), St. Louis, Mo: Mosby. PP: 346-350.
- Glickman, LT; Glickman, NW; Schellenberg, DB; Raghavn, M and Lee, TL (2000). Incidence of and breed-related risk factors for gastric dilatation-volvulus in dogs. *J. Am. Vet. Med. Assoc.*, 216: 40-45.
- Glickman, LT; Glickman, NW; Schellenberg, DB; Simpson, K and Lantz, GC (1997). Multiple risk factors for the gastric dilatation-volvulus syndrome in dogs: a practitioner/owner case-control study. *J. Am. Anim. Hosp. Assoc.*, 33: 197-204.
- Glickman, LT; Lantz, GC; Schellenberg, DB and Glickman, NW (1998). A prospective study of the survival and recurrence following the acute gastric dilatation-volvulus syndrome in 136 dogs. *J. Am. Anim. Hosp. Assoc.*, 34: 253-259.
- Hall, JA; Willer, RL; Seim, HB; Lebel, JL and Twedt, TC (1992). Gastric emptying of nondigestible radiopaque markers after circumcostal gastropexy in clinically normal dogs and dogs with gastric dilatation-volvulus. *Am. J. Vet. Res.*, 53: 1961-1965.
- Hardie, RJ; Flanders, JA; Schmidt, P; Credille, KM; Pedrick, TP and Short, CS (1996). Biomechanical and histological evaluation of a laparoscopic stapled gastropexy technique in dogs. *Vet. Surg.*, 25: 127-133.
- Jennings, PB; Mathey, WS and Ehler, WJ (1992). Intermittent gastric dilatation after gastropexy in a dog. *J. Am. Vet. Med. Assoc.*, 200: 1707-1708.
- MacCoy, DM; Sykes, GP; Hoffer, RE and Harvey, HJ (1982). A gastropexy technique for permanent fixation of the pyloric antrum. *J. Am. Anim. Hosp. Assoc.*, 18: 763-768.
- Mayhew, PD and Brown, DC (2009). Prospective evaluation

- of two intracorporeally sutured prophylactic laparoscopic gastropexy techniques compared with laparoscopic-assisted gastropexy in dogs. *Vet. Surg.*, 38: 738-746.
- Monnet, E** (2003). Gastric dilatation-volvulus syndrome in dogs. *Vet. Clin. North Am. Small Anim. Pract.*, 33: 987-1005.
- Raghavan, M; Glickman, NW; McCabe, G; Lantz, G and Glickman, LT** (2004). Diet-related risk factors for gastric dilatation-volvulus in dogs of high-risk breeds. *J. Am. Anim. Hosp. Assoc.*, 40: 192-203.
- Rasmusen, L** (2003). Stomach. In: Slatter, D (Ed.), *Textbook of small animal surgery*. (3rd Edn.), Vol. 1, Philadelphia, Pa: W. B. Saunders Co., PP: 610-614.
- Rawlings, CA; Foutz, TL; Mahaffey, MB; Howerth, EW; Bement, S and Canalis, C** (2001). A rapid and strong laparoscopic-assisted gastropexy in dogs. *Am. J. Vet. Res.*, 62: 871-875.
- Rivier, P; Furneaux, R and Viguier, E** (2011). Combined laparoscopic ovariectomy and laparoscopic-assisted gastropexy in dogs susceptible to gastric dilatation-volvulus. *Can. Vet. J.*, 52: 62-66.
- Schellenberg, D; Yi, Q; Glickman, NW and Glickman, LT** (1998). Influence of thoracic conformation and genetics on the risk of gastric dilatation-volvulus in Irish setters. *J. Am. Anim. Hosp. Assoc.*, 34: 64-66.
- Tanno, F; Weber, U; Wacker, CH; Gaschen, L; Schmid, V and Lang, J** (1998). Ultrasonographic comparison of adhesions induced by two different methods of gastropexy in the dog. *J. Small Anim. Pract.*, 39: 432-436.
- Wacker, CA; Weber, UT; Tanno, F and Lang, J** (1998). Ultrasonographic evaluation of adhesions induced by incisional gastropexy in 16 dogs. *J. Small Anim. Pract.*, 39: 379-384.
- Ward, MP; Patronek, GJ and Glickman, LT** (2003). Benefits of prophylactic gastropexy for dogs at risk of gastric dilatation-volvulus. *Prev. Vet. Med.*, 60: 319-329.
- Waschak, MJ; Payne, JT; Pope, ER; Jones, BD and Wagner-Mann, CC** (1997). Evaluation of percutaneous gastrostomy as a technique for permanent gastropexy. *Vet. Surg.*, 26: 235-241.
- Wilson, ER; Henderson, RA; Montgomery, RD; Kincaid, SD; Wright, GC and Hanson, RR** (1996). A comparison of laparoscopic and belt-loop gastropexy in dogs. *Vet. Surg.*, 25: 221-227.