

Short Paper

Commercial polyester/cotton fabric (Damour): a novel prosthetic material for hernioplasty in ruminants

Mosbah, E.* and Abouelnasr, K. S.

Department of Surgery, Anesthesiology and Radiology, Faculty of Veterinary Medicine, Mansoura University, Mansoura 35516, Egypt

*Correspondence: E. Mosbah, Department of Surgery, Anesthesiology and Radiology, Faculty of Veterinary Medicine, Mansoura University, Mansoura 35516, Egypt. E-mail: esammosbahmohamed@yahoo.com

(Received 12 Feb 2014; revised version 14 Jun 2014; accepted 13 Jul 2014)

Summary

The aim of this work was to study the possibility of using a new commercial polyester/cotton fabric to repair large sized umbilical and abdominal hernias in calves and small ruminants. Twenty-four animals (16 calves, 3 buffalo calves, 4 sheep, 1 goat) with umbilical or abdominal hernia were included in this study. The diameter of hernial ring ranged from (12-25) cm. An underlay technique was used for fixation of the prosthetic material that was placed under the visceral peritoneum after omentopexy and was secured to the recipient tissue with interrupted overlapped pattern using polypropylene monofilament suture material. After one year follow up, normal healing without complications in 19 animals was revealed (79.82%). Wound infection and delayed healing were recorded in 3 animals (12.5%) and wound dehiscence and re-herniation were observed in 2 cases (8.3%). In conclusion, our results suggested that commercial polyester/cotton fabric (Damour) represents a new cost effective alternative to commonly used meshes for hernioplasty of large sized hernias with relatively low rate of complications and recurrence in calves and small ruminants.

Key words: Hernioplasty, Polyester, Cotton, Calve, Small ruminants

Introduction

Surgical management of major abdominal wall defects remains a significant problem. Many abdominal wall defects can be repaired by primary closure; however, if the defect is large and there is a tension on the closure of the wound, the use of prosthetic materials is indicated (Park and Lakes, 1992). In food animals, hernias of sufficient size to necessitate prosthetic reconstruction were most commonly caused by umbilical hernias without previous repair in older heifers, umbilical hernias that had been repaired unsuccessfully one or more times, and incisional hernias following right paramedian abomasopexy or ventral midline celiotomy (Tulleners and Fretz, 1983). Surgical biomaterials may include substances that have the capacity to interact with living tissue and are not rejected by the body, and then are either absorbed naturally by the body and eliminated by biological processes or become a permanent part of the surrounding tissue (Kartinof, 2005). The frequently used biomaterials include monofilament and multifilament polypropylene meshes, multifilament polyester mesh (mersilene), multifilament polytetrafluoroethylene meshes (Teflon) and expanded polytetrafluoroethylene (ePTFE) (Amid, 1997). Shoukry *et al.* (1997) also investigated the use of a commercial polyester fabric for repair of abdominal hernia in different animals. Of importance, the most effective positioning of the prosthesis is also a subject of debate. Three techniques for implanting biomaterials to bridge an abdominal wall

defect that cannot be primarily closed have been described. These include the onlay, inlay and underlay techniques (Larson and Vandertoll, 1984; Rainier *et al.*, 2006). The underlay technique was used successfully with several advantages over other techniques and with relatively fewer complications and low hernia recurrence rates (Durrart *et al.*, 2001). The high cost associated with synthetic material initiated the search for safe and cheap prosthetic material that can replace the commonly used highly expensive meshes. Therefore, the aim of the present study was to try the use of a new commercial polyester/cotton fabric as an available, cheap material and of adequate strength for repair of large sized umbilical and abdominal hernias in calves, sheep and goat.

Materials and Methods

Animals

Twenty four animals, whose signalments are shown in Table 1 suffering umbilical or abdominal hernia with an average diameter of hernial ring ranged from (12-25) cm and that were diagnosed at the Mansoura Veterinary Teaching Hospital at Mansoura University and different farms at Dakahlia province, Egypt during the period from January 2009 to November 2013 were included in this study.

Surgical techniques

Animals were sedated using Xylazine HCL 2%

Table 1: Descriptive details of umbilical and abdominal hernia in different animals

Case No.	Animal species	Sex	Weight (kg)	Age, D (day), M (month)	Origin		Character of hernial ring	
					Cause	Location	Size (cm)	Shape
1	Calf	Male	85	5 M	Congenital	Umbilical	12×18	Oval
2	Calf	Female	35	6 D	Congenital	Umbilical	14×16	Indefinite
3	Calf	Female	170	8 M	Recurrent after fault operation	Umbilical	18×22	Circular
4	Calf	Male	80	5 M	Recurrent after fault operation	Umbilical	15×20	Circular
5	Calf	Female	50	45 D	Congenital	Umbilical	13×18	Oval
6	Calf	Female	60	6 M	After excision of umbilical vein abscess	Umbilical	12×15	Circular
7	Calf	Male	105	7 M	Recurrent after fault operation	Umbilical	15×22	Semicircular
8	Calf	Female	40	8 D	Congenital	Umbilical	14×20	Oval
9	Calf	Female	80	3 M	Recurrent after fault operation	Umbilical	14×19	Circular
10	Calf	Male	85	4 M	Recurrent after fault operation	Umbilical	12×15	Circular
11	Calf	Female	45	5 D	Congenital	Umbilical	15×22	Oval
12	Calf	Female	40	4 D	Congenital	Umbilical	22×25	Circular
13	Calf	Female	70	2 M	Congenital	Umbilical	12×18	Oval
14	Calf	Female	75	3 M	Congenital	Umbilical	16×19	Circular
15	Calf	Male	90	4 M	Recurrent after fault operation	Umbilical	12×18	Indefinite
16	Calf	Male	65	2 M	Congenital	Umbilical	12×17	Indefinite
17	Buffalo calf	Female	100	5 M	Recurrent after fault operation	Umbilical	14×21	Oval
18	Buffalo calf	Male	90	3 M	Traumatic	At level of the left stifle fold	16×22	Oval
19	Buffalo calf	Female	155	9 M	Recurrent after fault operation	At the left ventral abdominal wall	13×19	Oval
20	Ewe	Female	40	27 M	Traumatic	Ventral hypogastric	15×20	Indefinite
21	Ewe	Female	55	60 M	Traumatic	Behind the right costal arch	13×23	Oval
22	Ewe	Female	60	75 M	Following parturition	At level of the right stifle fold	12×20	Oval
23	Ewe	Female	60	85 M	Traumatic	Near the umbilicus	14×25	Semicircular
24	Goat	Female	30	29 M	Traumatic	At level of the right stifle fold	14×20	Semicircular

(Xylaject-ADWIA-Egypt) (0.1 mg/kg for calf, 0.05 mg/kg for ewe and 0.01 mg/kg for goat) and the site of operation was infiltrated using Lidocaine HCL 2% (Debocaine-AlDebiky-Egypt) diluted to 1% solution to provide sufficient volume for injection at 1 cm intervals along the injection site. After aseptic preparation, the affected animals were controlled in lateral or dorsal recumbency and a half circle or an elliptical skin incision was performed. The fibrous adhesions were dissected and the devitalized tissues were removed to expose the hernial ring. Following proper haemostasis, the hernial sac was incised along one side of the hernial ring margin to create a fascial flap. The fibrosed edge of the hernial ring was refreshed before implantation of the graft. Underlay technique for implantation (Fig. 1) was used where a sterilized piece of commercial polyester/cotton fabric produced by (Misr Spinning and Weaving Co., Mahalla al-Kubra-Egypt) was prepared according to the size of the hernial ring and fashioned to the shape of the defect allowing for 4-5 mm underlay then placed under the visceral peritoneum after omentopexy (part of omentum was grasped and loosely stitched to the implant). The fabric was secured to the recipient tissue with interrupted overlapped pattern using No. (1) Polypropylene monofilament suture material (Prolene Ethicon; Johnson and Johnson, Brussels, Belgium) (Fig. 2B). The implant was covered with a fascial flap derived from the hernial sac when possible and the skin was sutured with horizontal mattress suture using silk No. (1). Postoperative care included injection of penicillin G procaine (Norocillin L.A, Norbrook Lab. Ltd., Newry, Ireland) and Flunixin meglumine (Flamicure, Pharma Swede, 10th of Ramadan, Egypt by 2.2 mg/kg) for 5 days post-surgery. The skin wound was dressed routinely with povidone iodine (Betadine-topical antiseptic). The operated animals were followed either by regular visits or calling the owner during one year post surgery.

Results

Umbilical hernias were diagnosed in 17 animals (16

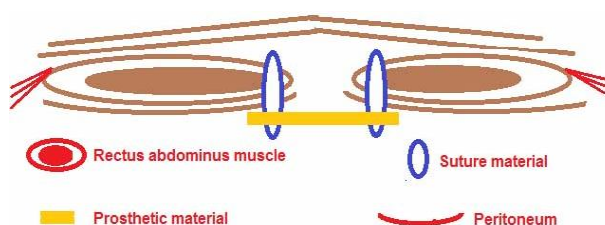


Fig. 1: Illustration of the under lay technique

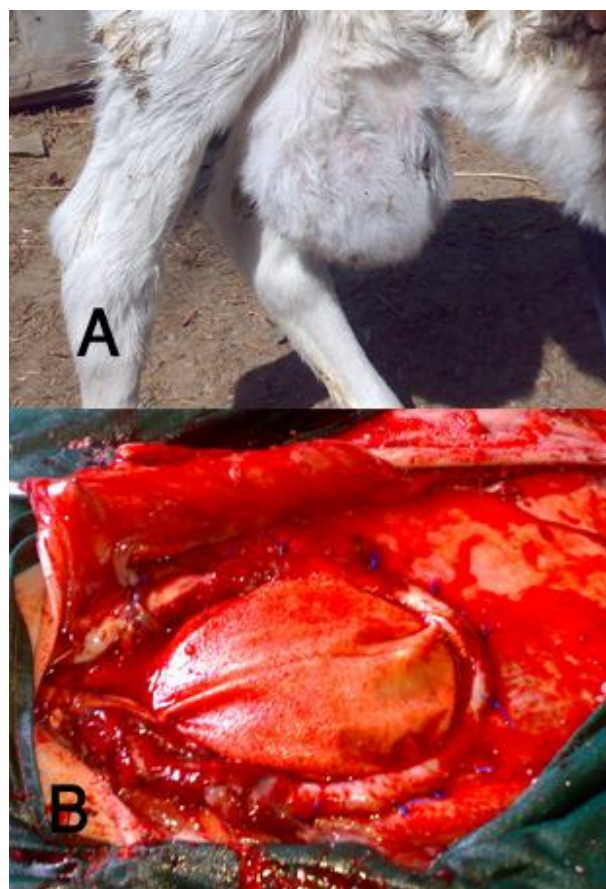


Fig. 2: Showed large umbilical hernia in a newly born calf (A) and after hernioplasty using polyester/cotton fabric (B)

Table 2: Animals grading according to wound healing post-surgery

Grading	Umbilical hernia		Abdominal hernia			Total %	
	Calf	Buffalo calf	Buffalo calf	Ewe	Goat		
Grade 1	14	-	2	3	-	19	79.2%
Grade 2	1	1	-	-	1	3	12.5%
Grade 3	1	-	-	1	-	2	8.3%

Grade 1: Normal healing without complication, Grade 2: Wound infection and delayed healing, and Grade 3: Implantation failure and hernia recurrence

calves and 1 buffalo calf) (Fig. 2A), while abdominal hernias were diagnosed in 7 animals (2 buffalo calves, 4 sheep and 1 goat) (Fig. 3A). The sex, age, weight, origin, location of abdominal hernias and characteristics of hernial rings were illustrated in Table 1.

The hernial swellings were reducible in animals presented with congenital hernias while in the acquired ones there were varying degrees of irreducibility and adhesions.

Typical signs of inflammation were noticed from the first day post-operative and the whole site of operation was painful to manual palpation in all animals. These signs were more severe in animals with abdominal recurrent or traumatic hernia. The inflammatory reaction subsided gradually within 2 weeks. Slight edematous swelling and seroma formation were developed 2 days post operation in all animals.

A slight hard mass of tissue with thickness about 1 to 2 cm and of nearly equal size to the implanted fabric was palpated at the site of operation in all animals for the first 2 weeks post operation. This mass subsided by the end of the 6th week post operation and could be hardly felt at the 8th week.

According to the gross appearance of the wound after surgery, the healing characteristics were categorized into 3 grades illustrated in Table 2. Normal healing was recorded in 19 animals (79.2%) (14 animals with umbilical hernia and 5 with abdominal hernia) in which the abdominal wall regained its integrity, skin wound was satisfactory healed and skin stitches were removed 10 days post operation (Fig. 3B).

Wound infection, stitch abscesses and presence of necrotic foci with formation of sinus tracts were recorded in 3 cases (12.5%) (two with umbilical and one with abdominal hernia). These complications responded well to topical antiseptic dressing and skin wound healing was achieved within 3 weeks.

Wound dehiscence and re-herniation were recorded in 2 cases (8.3%), one calf has developed a persistent draining sinus discharging pus; hernia was recurrent after three weeks that rendered reoperation and removal of the infected mesh. In another ewe, hernia recurrence was recorded following parturition that occurred 10 weeks post-surgery. During reoperation, implant dehiscence was found at one side, the defect was repaired with underlay technique using a new polyester/cotton fabric after removal of the old one.

All animals showed normal growth rate during the 12 months follow up and three ewes became pregnant and delivered normally without complications or hernia recurrence.

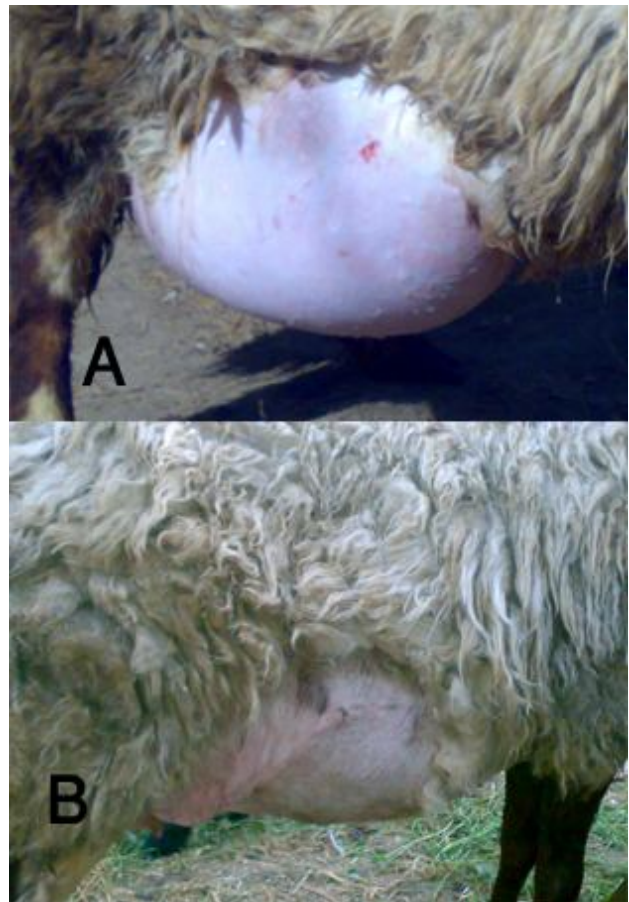


Fig. 3: Showed large ventral abdominal hernia in a ewe (A) and after removal of skin stitches 10 days postoperation (B)

Discussion

The good results achieved with the different prosthesis available and the reduction of the recurrence rate from up to 50% to less than 24% after repair of abdominal defects has placed prosthetic materials at the forefront with respect to the conventional suture repair techniques (Kingsnorth, 2000). However, in the developing countries, where veterinary surgery is considered of low public priority due to the usual comparison between animal value and the proposed cost of operation, the search for an ideal artificial biomaterial substitute to be used as a graft for large sized acquired or congenital hernias is a challenge. In this study a sterilized commercial polyester/cotton fabric was proven to be good hernioprosthesis material owing to its availability, flexibility, tissue compatibility and its unique cost effectiveness as a size of 1 m² of this

material costs less than 1 American Dollar in comparison with other highly priced prosthetic materials.

Refreshment of the fibrosed edges of the hernial rings before implantation of the prosthetic material was applied to facilitate a better mesh incorporation with the host tissue. Similar advice was given by Attinger *et al.* (2000) who reported that removal of the hernial ring induced better mesh incorporation and stimulated wound healing in comparison with suturing the mesh to undisturbed hernial ring.

The technique of implantation of the prosthetic materials is thought to play an important role in hernia recurrence (Schumpelick *et al.*, 2004). In the present study, prosthetic herniorrhaphy was carried out using the underlay technique with omentopexy that revealed satisfactory results in terms of low hernia recurrence (2 cases among 24 cases). Fixation of the implant by interrupted sutures in the underlay technique provided a multiple point non tension fixation which helped in dividing the stress evenly over the mesh and reduced crimping and bulging of the mesh (Parulker *et al.*, 1986; Ladurner *et al.*, 2001). Also, the position of the implant behind the rectus muscles where the force of abdominal pressure hold the prosthesis against the deep surface of the abdominal muscle wall is another explanation obtained by Reilingh *et al.* (2004).

The type of suture material used for fixation of the fabric also has a great role in the success of the prosthetic repair. The use of non-absorbable synthetic monofilament suture (polypropylene) has high strength and low tendency to harbor microorganisms was endorsed by Kawcak and Stashak (1995).

Omentopexy was performed to decrease the direct contact between the mesh and the abdominal viscera and the subsequent inflammatory response to the prosthesis that gives rise to intra-abdominal adhesions. Similar recommendation was given by Aydinli *et al.* (2007) for interpositioning of the omentum to act as a physical barrier between the implant and the viscera.

Covering the implanted material with a supportive flap from the hernial sac was found to strengthen the abdominal wall closure and reduce postoperative complications attributed to excessive suture tension and seroma formation. Similar advice was given by Scott (1979) in repairing of incisional hernia in horses.

Seroma formation was a major problem with the non-perforated Surgisis mesh repair (Gupta *et al.*, 2006). Also, hernia recurrence was the major complication with alloderm mesh in addition to limited size which requires sheets to be joined together for large defects (Butler *et al.*, 2005). Seroma formation was reported in all animals after implantation of the polyester/cotton fabric. Such complication was attributed by Amid (1997) to the size of dead space created between the implant and the host tissues, local circulatory disturbance resulting from the tight suture and the degree of haemostasis. It is necessary to avoid the contact of mesh with bowel to prevent late complications following prosthetic mesh repair (Basoglu *et al.*, 2004).

Generally, all prosthetic materials are associated with

post-repair clinical complications as wound infection, bowel fistula, erosion into abdominal viscera, increased recurrence rate (25%), repair failure and mesh extrusion even with polypropylene mesh that was universally accepted, where its implantation was associated with a high rate of adhesion formation to abdominal viscera especially small bowel (Bellon *et al.*, 1996; Coda *et al.*, 2003; Kingsnorth and LeBlanc, 2003).

The post-operative complications occurred in this study were within the acceptable limit. Wound infection and delayed healing were recorded in 3 animals in which the cause of hernia was recurrence after fault operation. Interestingly, the infection was cured with topical dressing without the need for mesh removal, which confirms the previous observation by Vilar *et al.* (2009) that it was not always necessary to remove the mesh in presence of infection.

Two cases of hernioplasty failure (2 out of 24, i.e., 8.3%) were recorded in this study. The cause of failure was wound infection in one calf with ratio (4.1%) that was considered an encouraging result in comparison with Houck *et al.* (1989) who previously reported that the rate of incisional hernia recurrence due to infection, ranged from 15 to 45% and explained that these procedures should be considered contaminated for surveillance and reporting purposes. The second case of hernia recurrence was recorded in a ewe following parturition which may be attributed to abdominal distension due to pregnancy and to the violent straining during parturition which lead to recurrent herniation at the same site of the previously implanted patch. Similar findings were recorded by Kader *et al.* (2005) despite the use of two folds of implanted patch.

In conclusion, the promising results obtained from the clinical use of commercial polyester/cotton fabric (Damour) in terms of body tolerance, availability and its economic effectiveness has encouraged us to potentiate its use for hernioplasty of large sized hernias in calves, sheep and goat.

References

- Amid, PK (1997). Classification of biomaterials and their related complication in abdominal wall hernia surgery. *Hernia*, 1: 15-21.
- Attinger, CE; Bulan, E and Blume, PA (2000). Surgical debridement. The key to successful wound-healing and reconstruction. *Clin. Pod. Med. Surg.*, 17: 599-630.
- Aydinli, B; Ozturk, G; Basoglu, M; Atamanalp, SS; Yeldirgan, L; Polat, K; Ozturk, M; Gundogdu, C and Oren, D (2007). Prevention of adhesions by omentoplasty: an incisional hernia model in rats. *Turk. J. of Med. Sci.*, 37: 93-97.
- Basoglu, M; Yildirgan, MI; Yilmaz, I; Balik, A; Celebi, F; Atamanalp, SS; Polat, KY and Oren, D (2004). Late complications of incisional hernias following prosthetic mesh repair. *Acta Chir. Belg.*, 104: 425-428.
- Bellon, JM; Bujan, J; Contreras, LA and Juardo, F (1996). Comparison of a new type of polytetrafluoroethylene patch (Mycro mesh) and polypropylene prosthesis (Marlex) for repair of abdominal wall defect. *J. Am. Coll. Surg.*, 183: 11-18.

- Butler, CE; Langstein, HN and Kronowitz, SJ** (2005). Pelvic, abdominal and chest wall reconstruction with AlloDerm in patients at increased risk for mesh-related complications. *Plast. Reconstr. Surg.*, 116: 1263-1275.
- Coda, A; Bendavid, R and Botto, F** (2003). Structural alteration of prosthetic meshes in humans. *Hernia*. 7: 29-34.
- Durrart, ML; Chamlou, RA; Mehdi, A and Limbson, JM** (2001). Repair of abdominal wall defect by intraperitoneal implantation of polytetra-fluoroethylene (Teflon) mesh. *Ann. De Chir.*, 42: 262-265.
- Gupta, A; Zahriya, K; Mullens, PL; Salmassi, S and Keshishian, A** (2006). Ventral herniorrhaphy: experience with two different biosynthetic mesh materials, Surgisis and Alloderm. *Hernia*. 10: 419-425.
- Houck, JP; Rypins, EB; Sarfeh, IJ; Juler, GL and Shimoda, KJ** (1989). Repair of incisional hernia. *J. Surg. Gynec. Obst.*, 169: 397-399.
- Kader, NH; Abass, BT and Al-Sadi, HI** (2005). A comparative experimental study of the use of tunica vaginalis and pericardium as allografts for hernioplasty in sheep. *Iraqi J. Vet. Sci.*, 19: 57-70.
- Kartinof, C** (2005). Surgical biomaterials and tissue regeneration technologies. *World J. Surg.*, 3: 123-128.
- Kawcak, CE and Stashak, TS** (1995). Predisposing factors, diagnosis and management of large abdominal wall defects in horses and cattle. *JAVMA*. 206: 607-611.
- Kingsnorth, A** (2000). Mesh compared with non-mesh methods of open groin hernia repair: systematic review of randomized controlled trials. *Br. J. Surg.*, 87: 854-859.
- Kingsnorth, A and Leblanc, K** (2003). *Management of abdominal hernias*. 3rd Edn., London, New York: Edward Arnold. PP: 172-188.
- Ladurner, R; Trupka, A; Schmidbauer, S and Hallfedt, K** (2001). The uses of an underlay polypropylene mesh in complicated incisional hernias: successful French surgical technique. *Minerva Chir.*, 56: 111-115.
- Larson, GM and Vandertoll, DJ** (1984). Approaches to repair of ventral hernia and full thickness losses of the abdominal wall. *Surg. Clin. North Am.*, 64: 335-349.
- Park, JB and Lakes, RS** (1992). Biomaterials, an introduction. Sec. Ed. Plenum. Press. 1: 233-244.
- Parulker, BG; Mathur, SK; Sup, AN and Vora, IM** (1986). Use of indigenous knitted nylon mesh to repair large abdominal defects--an experimental study. *JPGM*. 32: 214-218.
- Rainier, MS; Evelyn, AK; David, MJ; Ernst, BS and Lantz, GC** (2006). Tensile strength comparison of small intestinal submucosa body wall repair. *J. Surg. Res.*, 135: 9-17.
- Reilingh, VTS; Geldere, VD; Langenhorst, B; Jong, D; Wilt, GJ and Goor, VH** (2004). Repair of large midline incisional hernias with polypropylene mesh: comparison of three operative techniques. *Hernia*. 8: 56-59.
- Schumpelick, V; Kling, U; Junge, K and Stumpf, M** (2004). Incisional abdominal hernia: the open mesh repair. *Langenbecks Arch. Surg.*, 389: 1-9.
- Scott, EA** (1979). Repair of incisional hernia in the horse. *JAVMA*. 175: 1203-1207.
- Shoukry, M; El-keiey, M; Hamouda, M and Gadallah, S** (1997). Commercial polyester fabric repair of abdominal hernias and defects. *Vet. Rec.*, 7: 606-607.
- Tulleners, EP and Fretz, PB** (1983). Prosthetic repair of large abdominal wall defect in horses and food animals. *JAVMA*. 182: 258-262.
- Vilar, MJ; Doreste, F; Spinella, G and Valentini, S** (2009). Double layer mesh hernioplasty for repair of incisional hernias in 15 horses. *J. Eq. Vet. Sci.*, 29: 172-176.