

Scientific Report

First report of the *Hadjelia truncata* infestation in pigeons of Iran

Razmi, G. R.^{1*}; Kalidari, G. A.² and Maleki, M.¹

¹Department of Pathobiology, School of Veterinary Medicine, Ferdowsi University of Mashhad, Mashhad, Iran; ²Department of Clinical Sciences, School of Veterinary Medicine, Ferdowsi University of Mashhad, Mashhad, Iran

*Correspondence: G. R. Razmi, Department of Pathobiology, School of Veterinary Medicine, Ferdowsi University of Mashhad, Mashhad, Iran. E-mail: razmi@ferdowsi.um.ac.ir

(Received 6 Aug 2005; revised version 28 Dec 2005; accepted 15 Jan 2006)

Summary

Three adult pigeons (*Columbia livia*) belonging to a pigeon farm in Mashhad area were submitted to Poultry Clinic of School of Veterinary Medicine for post-mortem inspection. The farm had 150 adult pigeons and a number of them suffered from a chronic disease with body weight loss, diarrhoea and weakness. At necropsy, slight to extreme enlargement with distortion were observed in gizzards of all carcasses. There was a large number of nematodes in or beneath the lining of the affected gizzards. The worms were removed from the lining of the rostral parts of the gizzards and cleared in lactophenol. Also, tissue blocks from various parts of the gizzards were processed by conventional methods for preparation of paraffin wax sections. Based on parasitological and pathological findings the *Hadjelia truncata* infestation was identified for the first time from Iran and this species is a pathogenic agent for pigeons.

Key words: *Hadjelia truncata*, gizzard, pigeon, Iran

Introduction

Hadjelia truncata belongs to the order *Spirurida*, superfamily *Habronematoidea*, family *Hedruridae* and genus *Hadjelia* (Anderson, 2000). This worm has been found in the gizzard of a number of bird species in Europe and Asia. The intermediate host are various beetles (Anderson, 2000). So far, there have been only three reports of the pigeons infestation with this parasite from Egypt (Tadros and Iskander, 1975), Iraq (Al-Attar and Abdul-Aziz, 1985), and Cyprus (Appleby *et al.*, 1995). This is the first report of the *H. truncata* infestation in the gizzard of pigeons in Iran.

Materials and Methods

Three adult pigeons (*Columbia livia*) belonging to a pigeon farm in Mashhad area were submitted to Poultry Clinic of School

of Veterinary Medicine, Ferdowsi University of Mashhad for post-mortem inspection. The farm had 150 adult pigeons and a number of them suffered from a chronic disease with body weight loss, diarrhoea and weakness. At necropsy, slight to extreme enlargement with distortion were observed in gizzards of all carcasses. There was a large number of nematodes in or beneath the lining of the affected gizzards. The infested gizzards were removed and preserved in 10% buffered formaline for parasitological and pathological examination. The worms removed from the lining of the rostral parts of the gizzards and washed by shaking in 0.9% saline and a number of worms were cleared in lactophenol for identification and the rest of them stored in 5% formalin. Also, tissue blocks from various parts of the gizzards were processed by conventional methods for preparation of paraffin wax sections. The sections were stained with haematoxylin and eosin (Kiernan, 1990).

Results and Discussion

The morphology of the nematodes were examined by light microscope. The length of male and female were 7-9 mm and 13-17 mm, respectively. Microscopical examination of cephalic region was revealed two lateral lips, each being trilobed with cylindrical pharynx (Fig. 1). The

Fig. 1: Lateral view of the anterior end of *H. truncata*, (×400)

morphology of caudal region of male was characteristic of the spirurid-type. There were two unequal and dissimilar spicules, one 1.26 mm long and the other 0.34 mm long. The tail was coiled and 2 wide caudal alae and papillae were presented (Fig. 2). Histopathological examination showed the transversed section of the worm with necrosis and interstitial infiltration of inflammatory cells in lamina propria and muscle layer (Fig. 3).

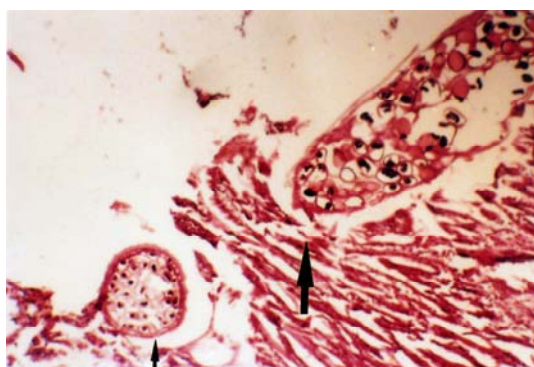


Fig. 3: Histological section of gizzard wall with transverse section of parasite (arrows) (H&E, ×100)

The morphology of cephalic and caudal region was corresponded to the description by Chabaud (1975) and Appleby *et al.* (1995) for *H. truncata*. Gross and pathological findings were similar to those reported by Appleby *et al.* (1995). Based on our study the *H. truncata* infestation was identified for the first time in Iran.

Acknowledgement

The authors would like to thank Mr Mohammadnejad for the preparation of the histological sections.

References

- Al-Attar, MA and Abdul-Aziz, TA (1985). *Hadjelia truncata* in pigeons. Vet. Rec., 117: 535.
- Anderson, RC (2000). *Nematode parasites of vertebrates their development and transmission*. 2nd. Edn., CABI Publishing. PP: 432-433.
- Appleby, EC; Gibbons, SLM and Georiou, K (1995). Distortion of the gizzard in Cyprus pigeons (*Columba livia*) associated with

Fig. 2: Lateral view of posterior end of male *H. truncata*, (×400)

- Hadjelia truncata* infestation. Vet. Rec., 136: 561-564.
- Chabaud, AG (1975). Key to the genera of the order spirurida part 2. In: Anderson, RC; Chabaud, AG and Willmott, S (Eds.), CIH keys to nematode. (1st. Edn.), United Kingdom, Common Wealth Agricultural Bureaux. No. 3. PP: 29-58.
- Kiernan, JA (1990). *Histological and histochemical methods*. 2nd. Edn., Pergamon Press PLC. PP: 96-97.
- Tadros, G and Iskander, AR (1975). *Hadjelia truncata*, a new parasite of pigeons in Egypt and its pathogenicity. J. Egyptian Vet. Med. Assoc., 35: 283-301.