

Scientific Report

Linguatula serrata nymph in a cat

Esmailzadeh, S.*; Mohammadian, B. and Rezaei, A.

Department of Pathobiology, Faculty of Veterinary Medicine, Shahid Chamran University of Ahvaz, Ahvaz, Iran

*Correspondence: S. Esmailzadeh, Department of Pathobiology, Faculty of Veterinary Medicine, Shahid Chamran University of Ahvaz, Ahvaz, Iran. E-mail: s_esmailzadeh@yahoo.com

(Received 5 Dec 2007; revised version 3 Mar 2008; accepted 16 Apr 2008)

Summary

Linguatula serrata is a tongue-shaped parasite that infects carnivores or insectivorous reptile as final host and herbivores as intermediate ones. During necropsy of a 1.5-year-old female stray cat, a few white and fine nodules were observed on the diaphragmatic lobes of the lung. In histopathological examination, the nodules contained a turned spinosum parasite with cuticular spines and in parasitological examination of digested suspension, nymph of *L. serrata* with characteristic features was seen. This is the first confirmed infestation in a cat with nymph of *L. serrata* in Iran.

Key words: Linguatulosis, Lung, Cat, Nymph, Iran

Introduction

Linguatula serrata is a pentastomid, cosmopolitan parasite. The adult stage occurs in the nasal and respiratory passages of dogs, cats, foxes and other carnivores or insectivorous reptiles, more rarely in man, horse, goat and sheep and its nymphs live in the liver, lungs and lymph nodes of herbivores (Soulsby, 1982; Haugerud, 1989; Roberts and Jonovy, 2006). It is flattened ventrally and somewhat convex dorsally and its cuticle is transversely striated. The male parasite is 1.8-2 cm long and the female is 8-13 cm long (Soulsby, 1982). The eggs are measured 70 µm by 90 µm (Roberts and Jonovy, 2006).

The eggs are expelled from the respiratory passages of the final host and when swallowed by a suitable herbivorous animal, they hatch in the alimentary canal and the larva reaches the mesenteric lymph nodes, in which it develops to the infective nymphal stage after several moulting. Final host such as dogs become infected by eating the infected viscera of animals especially sheep, goat and cattle (Soulsby, 1982). Human beings may also be infected by both

the nymphal stage, a condition called nasopharyngeal linguatulosis or Halzoun syndrome and the eggs, an asymptomatic condition called visceral linguatulosis (Khalil and Schacher, 1965; Yagi *et al.*, 1996). This short paper describes the first case of *L. serrata* (nymphal stage) in a cat in Iran.

Materials and Methods

During teaching necropsy of a 1.5-year-old female stray cat (mixed-breed) in the Veterinary Teaching Hospital of Shahid Chamran University, Ahvaz, a few white and fine nodules were observed on the lateral aspect of diaphragmatic lobes of the lung. The nodules were measured about 1 mm in diameter. Texture of the lung was rubbery in all lobes, especially diaphragmatic ones. Tissue sections were taken from the affected areas of the lung and examined in two steps. First, some of the sections were fixed in 10% neutral buffered formalin, they were prepared and then stained with haematoxylin and eosin stains. Second, the leftover samples were sliced into sections of 4-5 mm thick, then 10 g of

mixed sliced samples were digested in 20 ml of pre-heated digestion medium containing 5 g pepsin (7197, Merck) and 25 ml hydrochloric acid (317, Merck) in 1000 ml distilled water, and incubated at 37°C for 24 h. The final suspension was examined using a stereomicroscope.

Results

Histopathological examination of the nodules revealed thin fibrotic capsule below the pleural surface that contained a turned spinosum parasite with cuticular spines (Fig. 1). Local infiltration of mononuclear inflammatory cells especially lymphocytes, collapse of adjacent alveoli and acute diffuse interstitial pneumonia were also found. In examination of the suspension, a nymph of about 5 mm long, covered with spines was seen (Fig. 2). The mouth was flanked by two pairs of hooks and located on the cephalothorax. The posterior part of the parasite exhibited annulations and thorns. Based on the parasitological findings (the spines and the serrated aspect) and histopathological features, the parasite was diagnosed as nymphal stage of *L. serrata*.

Discussion

Although the parasite is cosmopolitan, it is mainly seen in tropical and subtropical areas. Infection with *L. serrata* in human cases have been reported from Africa, South America, Southeast Asia and the Middle East (Beaver *et al.*, 1984; Drabick, 1987;

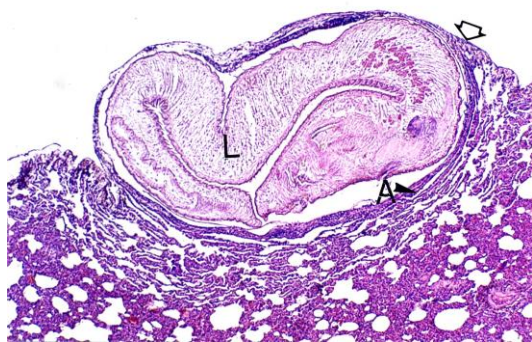

Fig. 1: Thin-walled cyst under visceral pleura (arrowhead) contained turned spinosum parasite (L). Compressive atelectasis (A) around the cyst and interstitial pneumonia are also seen, (H&E, ×46)

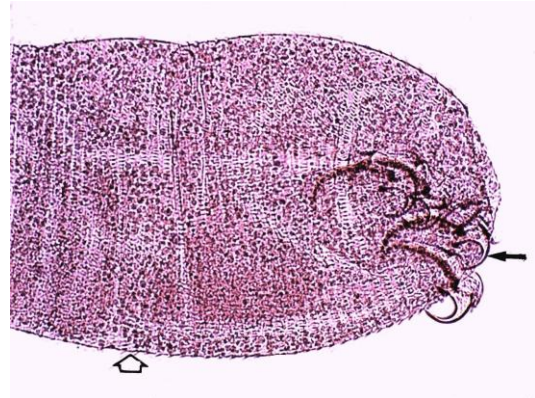


Fig. 2: Anterior and ventrolateral view of *Linguatula serrata* nymph showing four main hooks (arrow) and cuticular spines (arrowhead), (×46)

El-Hassan *et al.*, 1991; Lazo *et al.*, 1999; Siavashi *et al.*, 2002). The parasite has been reported in the dogs from different countries such as Lebanon (Khalil and Schacher, 1965), Turkey (Dincer, 1982), Sudan (Yagi *et al.*, 1996) and Iran (Meshgi and Asgarian, 2003). The nymph stage of the parasite has been reported in ruminant such as cattle (Dorchies *et al.*, 1988), camel (Tafti *et al.*, 2001), sheep (Tavassoli *et al.*, 2006) and goat (Saiyari *et al.*, 1996; Razavi *et al.*, 2004). Most infections cause few, if any, symptoms and therefore go undetected. In fact, most recorded cases were found at necropsy after death from other causes (Roberts and Jonovy, 2006). Previously, the first report of larval stage of the parasite was described in the cat in Peru (Ibanez, 1969). To the authors' knowledge, this is the second report of *L. serrata* infection in cat in the world and the first one in Iran.

Acknowledgements

The authors are thankful to Dr. N. Hoghooghi Rad, Emeritus Professor of Veterinary Parasitology, for his support in diagnosis. They also thank Miss. F. Behdarvand and Mr. M. Ageli for their technical assistance in Parasitology Laboratory, School of Veterinary Medicine, Shahid Chamran University, Ahvaz.

References

- Beaver, PC; Jung, ROC and Cup, EW (1984). Crustacea, linguatulid, millipedes, centipedes,

- scorpions, spiders, ticks and mites. In: *Clinical parasitology*. (9th Edn.), Philadelphia, Lea and Febiger. PP: 572-573.
- Dincer, S (1982). Prevalence of *L. serrata* in stray dogs and animals slaughtered at Elazig abattoir (Turkey). Ankara Üniv. Vet. Fak. Derg., 29: 324-330 (In Turkish with English abstract).
- Dorchies, P; De Lahitte, DJ; Pangui, LJ and Alzieu, JP (1988). Recherche de *Fasciola hepatica*, *Dicrocoelium lanceolatum* et *Linguatula denticulate* dans les foies de bovins saisis (a) l'abattoir de Pamiers. Revue Méd. Vét., 139: 307-309 (In French with English abstract).
- Drabick, JJ (1987). Pentastomiasis. Rev. Infect. Dis., 9: 1087-1094.
- El-Hassan, AM; Elton, IA and El-Asha, BM (1991). The Marrara syndrome: isolation of *Linguatula serrata* from a patient and viscera of goats. Trans. R. Soc. Trop. Med. Hyg., 85: 309.
- Haugerud, RE (1989). Evolution in the pentastomids. Parasitol. Today. 5: 126-132.
- Ibanez, N (1969). *Linguatula serrata*: larval form in a domestic cat. Bol. Chil. Parasitol., 24: 160-162 (In Spanish with English abstract).
- Khalil, GM and Schacher, JF (1965). *Linguatula serrata* in relation to Halzoun and the Marrara syndrome. Am. J. Trop. Med. Hyg., 15: 736-746.
- Lazo, RF; Hidalgo, E; Lazo, JE; Bermeo, A; Llaguno, M; Murillo, J and Teixeira, VPA (1999). Ocular linguatuliasis in Ecuador: case report and morphometric study of the larva of *Linguatula serrata*. Am. J. Trop. Med. Hyg., 60: 405-409.
- Meshgi, B and Asgarian, O (2003). Prevalence of *Linguatula serrata* infestation in stray dogs of Shahrekord. Iran. J. Vet. Med., 50: 466-467.
- Razavi, SM; Shekarforoush, SS and Izadi, M (2004). Prevalence of *Linguatula serrata* nymphs in goat in Shiraz, Iran. Small Rum. Res., 54: 213-217.
- Roberts, LS and Jonovy, JrJ (2006). *Foundation of parasitology*. 7th Edn., Boston, McGraw Hill Higher Education. PP: 562-564.
- Saiyari, M; Mohammadian, B and Sharma, RN (1996). *Linguatula serrata* (Forlich 1789) nymphs in lungs of goat in Iran. Trop. Anim. Health Prod., 28: 312-314.
- Siavashi, MR; Assmar, M and Vatankhah, A (2002). Nasopharyngeal pentastomiasis (Halzoun): report of 3 cases. Iran. J. Med. Sci., 27: 191-192.
- Soulsby, EJJ (1982). *Helminths, arthropods and protozoa of domestic animals*. 7th Edn., London, Bailliere Tindall. PP: 497-498.
- Tafti, AK; Maleki, M and Oryan, A (2001). Pathological study of intestines and mesenteric lymph nodes of camels (*Camelus dromedarius*) slaughtered in Iran. J. Camel Pract. Res., 8: 209-213.
- Tavassoli, M; Tajic, H; Dalir-Naghadeh, B and Hariri, F (2006). Prevalence of *Linguatula serrata* nymphs and gross changes of infected mesenteric lymph nodes in sheep in Urmia, Iran. Small Rum. Res., 72: 73-76.
- Yagi, H; El-Bahari, S; Mohamed, HA; Ahmed, ERS; Mustafa, B and Mahmoud Saad, MB (1996). The Marrara syndrome: a hypersensitivity reaction of the upper respiratory tract and buccopharyngeal mucosa to nymphs of *Linguatula serrata*. Acta Trop., 62: 127-134.