

Scientific Report

Dog-bite induced fatal meningitis in a kitten: a case report

Selk Ghaffari, M.^{1*}; Dezfoulian, O.² and Moosakhani, F.¹

¹Department of Clinical Sciences, Faculty of Veterinary Medicine, Karaj Branch, Islamic Azad University, Karaj, Iran; ²Department of Pathobiology, College of Veterinary Medicine, Lorestan University, Lorestan, Khorramabad, Iran

*Correspondence: M. Selk Ghaffari, Department of Clinical Sciences, Faculty of Veterinary Medicine, Karaj Branch, Islamic Azad University, Karaj, Iran. E-mail: selkghaffari@gmail.com

(Received 20 Aug 2007; revised version 12 Nov 2007; accepted 8 Jan 2008)

Summary

Bacterial infection of the brain is relatively rare in dogs and cats. A cat at approximately three months of age was admitted to the clinic with a history of dog bite seven days before admission. On clinical presentation, the cat was unconscious and in lateral recumbency. One hour after admission, the cat developed severe apnoea and asystole. Cardiorespiratory resuscitation was unsuccessful and the animal died. Necropsy and histopathological examination revealed a purulent meningitis. A sample of purulent exudates was submitted for microbiological examination. *Pasteurella multocida* was isolated from bacterial culture. Due to the history of dog biting, direct inoculation of *P. multocida* into the subdural space following penetrating dog-bite wounds was suggested to be the cause of meningitis and death of the kitten. This report highlights the importance of antibiotic therapy in bite wounds to reduce such fatal complications.

Key words: Meningitis, Cat, *Pasteurella multocida*

Introduction

Meningitis and encephalitis refer to inflammatory conditions of the meninges and brain parenchyma. Meningitis is characterized by inflammation of the meninges with involvement of subarachnoid space. Inflammatory diseases of central nervous system (CNS) are usually divided into infectious and non-infectious causes. Infectious causes include bacteria, fungi, protozoa, parasites, rickettsiae and viruses (Wingfield, 1997). Bacterial infection of the brain is relatively rare in dogs and cats (Munana, 2004).

The true incidence of dogs and cats bite wounds is unknown, but dog-bite wounds were responsible for 15% of canine admissions to an emergency service in one study (Holt and Griffin, 2000; Scheepens *et al.*, 2006). Cats are not as frequently bitten as dogs, and victims are often younger than the mean age of cats in the overall hospital population (Shamir *et al.*, 2000). This report describes a case of fatal meningitis in a

kitten following the dog bite.

Case history

A male, stray cat at approximately three months of age was admitted to the clinic with a history of dog bite seven days before admission. The history indicated that the treatment included the application of topical povidine-iodine on the bite wounds by the owner. Two days before admission, the cat showed two episodes of grand mal seizures; furthermore, cervical rigidity, lethargy and progressive abnormal mental status was observed by the owner. On clinical presentation, the cat was unconscious and in lateral recumbency. Physical examination revealed several bite wounds in the neck and forearms. Rectal temperature showed hypothermia (36°C). Cardiac auscultation revealed bradycardia (90 beats/min). No heart murmur or obvious arrhythmia was detected.

Complete blood count indicated neutrophilic leukocytosis with left shift.

Thoracic and abdominal radiographs showed no significant abnormality. The cat received intravenous cefazolin (25 mg/kg) and Ringer solution (10 ml/kg/h). Approximately one hour after admission, the cat developed severe apnoea and asystole. Cardiorespiratory resuscitation was unsuccessful and the animal died. At postmortem examination the meninge of the right hemisphere of cerebrum was thickened by a grayish gelatinous blanket (Fig. 1). This cloudy material was feature of the concentrated pus, which also covered the internal surface of the skull (endosteum membrane). For microbiological examination, a sample of purulent exudates was taken by sterile cotton-tipped swab and inoculated on both blood and MacConkey agars. The plates were incubated aerobically at 37°C for 48 h. Gram staining of colonial material revealed small, Gram-negative rods and coccobacilles. On the basis of colony, cellular morphology and biochemical properties, the isolate was identified as *P. multocida*. Tissue samples were fixed in 10% formalin, routinely embedded in paraffin and cut into 4 µm sections which were stained with haematoxylin and eosin. Histopathological study showed that the leptomeninge was invaded by large amount of fibrin deposits and neutrophils, which scant of mononuclear cells scattered among them (Fig. 2). Blood vessels were engorged with RBC(s), but no haemorrhage was observed in the lesion.

The surface of pia matter was intact and firmly attached to the adjacent outer layers of the brain, also no evidence of infiltration

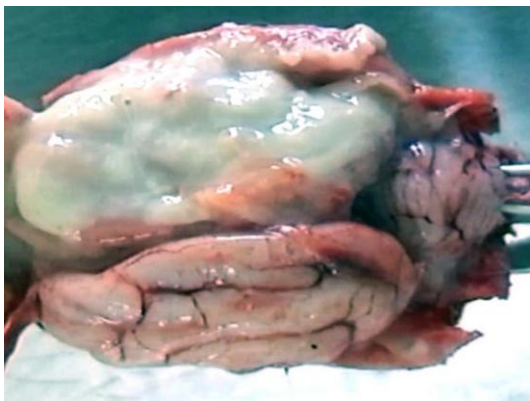

Fig. 1: A widespread purulent leptomeningitis, involve the dorsal portion of the right hemisphere

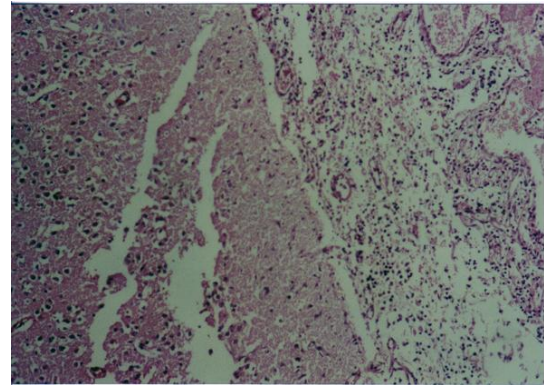


Fig. 2: Fibrinopurulent leptomeningitis: accumulation of inflammatory cells, predominantly neutrophils, and fibrinous exudates in subarachnoid spaces, (H&E, ×100)

of suppurative cells was observed in the parenchyma of the brain.

Discussion

In the presented case, the mechanism of infection was supposed to be direct inoculation of bacteria into the subdural space following penetrating dog-bite wounds. In this case, *P. multocida* was isolated from bacterial culture. *Pasteurella* organisms are clinically significant in many dog- and cat-bite wounds. These organisms normally inhabit the nasal, gingival and tonsillar regions and gastrointestinal tract of approximately 12 to 92% of dogs and 52 to 99% of cats as well as many other animals (Weiss *et al.*, 1998; Green and Goldstein, 2006). The most common consequence of *P. multocida* infection is a local cellulitis, although serious systemic diseases may occur (e.g., meningitis, empyema, pneumonia, peritonitis, osteoarticular infections, endocarditis and septicemia) (Kimura *et al.*, 2004). Several mechanisms have been described to be involved in bacterial infections of the central nervous system in cats and dogs which included haematogenous spread (septic emboli or mucous membrane colonization), contiguous infection from adjacent structures (inner ears, cribriform plate, sinuses, eyes and vertebrae), direct inoculation (trauma, bite wound and surgery) and migration of foreign bodies or aberrant parasites (Braund, 2003).

In our case, bradycardia, hypothermia,

shock, seizures and cervical rigidity were the most significant clinical findings at admission. The main clinical signs of bacterial infection of CNS may include cervical rigidity, hyperesthesia, pyrexia, vomiting, and bradycardia; seizures may also occur. Additional neurologic deficits such as paresis, paralysis, hyperreflexia, blindness, nystagmus and head tilt are common. Bacteria isolated from these cases include *Staphylococcus aureus*, *Staphylococcus epidermidis*, *Staphylococcus albus*, *P. multocida*, *Actinomyces*, and *Nocardia* (Nelson and Couto, 2003).

Pasteurella multocida meningitis has been also reported in humans following dog or cat bites. Most cases of *P. multocida* meningitis are infants under one year or adults over 60 years old. Some investigators believed that the disorder usually occurs in immunocompromised patients (Shimizu *et al.*, 1995; Hermann *et al.*, 1998; Jones and Khoosal, 1999; Armstrong *et al.*, 2000). However, a literature search did not reveal information concerning similar findings in small animals. We did not collect cerebrospinal fluid (CSF) in this case due to small size and comatose status of the animal. The analysis of CSF in the cases that are suspected to suppurative meningitis can be considered as a diagnostic test if there are predominately polymorphonuclear leukocytes in CSF (Fenner, 2000). In conclusion, dog-bite wounds may appear trivial, but if they are not managed appropriately, they can become infected and may result in adverse systemic complications as seen in our case. Antibiotic prophylaxis should be initiated for patients with high-risk bite wounds and for those who are at risk for serious wound infection complications. In the present case, inappropriate initial treatments and delay in referring the animal to the veterinary clinic was resulted in unexpected fatal meningitis.

References

- Armstrong, GR; Sen, RA and Wilkinson, J (2000). *Pasteurella multocida* meningitis in an adult: case report. *J. Clin. Pathol.*, 53: 234-235.
- Braund, KG (2003). Inflammatory diseases of the central nervous system. In: Braund, KG (Ed.), *Clinical neurology in small animals*. (1st Edn.), International Veterinary Information Service, Ithaca. PP: 1-47.
- Fenner, WE (2000). Disease of the brain. In: Ettinger, SJ and Feldman, EC (Eds.), *Textbook of veterinary internal medicine*. (5th Edn.), Philadelphia, W. B. Saunders Co., PP: 572-574.
- Green, CE and Goldstein, EJC (2006). Bite wound infections. In: Green, CE (Ed.), *Infectious diseases of the dog and cat*. (3rd Edn.), Saunders, St. Louis, Missouri. P: 499.
- Hermann, CK; Hansen, PB; Bangsborg, JM and Pers, C (1998). Bacterial infections as complications of dog bites. *Ugeskr. Laeger*. 160: 4860-4863.
- Holt, DE and Griffin, G (2000). Bite wounds in dogs and cats. *Vet. Clin. North Am. Small Anim. Pract.*, 30: 669-679.
- Jones, N and Khoosal, M (1999). Infected dog and cat bites. *N. Engl. J. Med.*, 340: 1841-1842.
- Kimura, R; Hayashi, Y; Takeuchi, T; Shimizu, M; Iwata, M; Tanahashi, J and Ito, M (2004). *Pasteurella multocida* septicemia caused by close contact with a domestic cat: report and literature review. *J. Infect. Chemother.*, 10: 250-252.
- Munana, KR (2004). Head tilt and nystagmus. In: Platt, SR and Oiby, NJ (Eds.), *BSAV manual of canine and feline neurology*. (3rd Edn.), British Small Animal Association, Gloucester. PP: 164-165.
- Nelson, RW and Couto, CG (2003). *Small animal internal medicine*. 2nd Edn., Mosby, St. Louis. P: 1014.
- Scheepens, ET; Peeters, ME; L'eplattenier, HF and Kirpensteijn, J (2006). Thoracic bite trauma in dogs: a comparison of clinical and radiological parameters with surgical results. *J. Small Anim. Pract.*, 47: 721-726.
- Shamir, MH; Leisner, S; Klement, E; Gonen, E and Johnston, DE (2002). Dog bite wounds in dogs and cats: a retrospective study of 196 cases. *J. Vet. Med. A Physiol. Pathol. Clin. Med.*, 49:107-112.
- Shimizu, T; Hasegawa, K; Mitsuhashi, Y; Kojima, S; Ishikawa, K; Hayashi, N and Sawada, T (1995). A case of *Pasteurella multocida* subsp. *multocida* septicemia due to cat bites in liver cirrhosis patient. *Kansenshogaku Zasshi*. 69: 1302-1306.
- Weiss, HB; Friedman, DI and Coben, JH (1998). The incidence of dog bites injuries treated in emergency departments. *JAMA.*, 279: 51.
- Wingfield, WE (1997). *Veterinary emergency secrets*. 1st Edn., Philadelphia, Hanley and Belfus, INC. PP: 241-242.