

Scientific Report

Effect of feeding detoxified karanj seed cake on immunity and pathology in growing lambs

Krishnamoorthy, P.^{1*}; Rao, S. B. N.²; Dineshkumar, D.³ and Rahman, H.¹

¹Pathology and Epidemiology Laboratory, Project Directorate on Animal Disease Monitoring and Surveillance (ADMAS), Indian Veterinary Research Institute (IVRI) Campus, Hebbal, Bangalore-560024, Karnataka, India; ²Division of Animal Nutrition, National Institute of Animal Nutrition and Physiology (NIANP), Adugodi, Bangalore-560030, Karnataka, India; ³MSc in Biochemistry, Laboratory of Animal Nutrition, Centro de Energia Nuclear na Agricultura (CENA), University of Sao Paulo, Piracicaba, Brazil

***Correspondence:** P. Krishnamoorthy, Pathology and Epidemiology Laboratory, Project Directorate on Animal Disease Monitoring and Surveillance (ADMAS), Indian Veterinary Research Institute (IVRI) Campus, Hebbal, Bangalore-560024, Karnataka, India. E-mail: krishvet@gmail.com

(Received 5 Jan 2013; revised version 24 Sept 2013; accepted 3 Dec 2013)

Summary

This scientific report describes the effect of feeding detoxified karanj seed cake as protein replacement of soya bean meal on immunity and pathology in growing lambs. Twenty-four male lambs, 4-6 months of age were divided into four groups of six each and fed with different levels of detoxified karanj seed cake (dKC 0%, dKC 25%, dKC 50%, dKC 75%) for 140 days. Effect on humoral and cell mediated immunity was assessed by antibody titer against *Peste des petites ruminants* (PPR) vaccination and lymphocyte proliferation assay, respectively. Significant decrease in the humoral immunity in high dose fed group and no change in stimulation index of lymphocytes in all the groups were observed. On histopathology, dKC 75 showed severe changes in intestine, testis and mesenteric lymph node. Thus, the present process of detoxification of karanj seed cake is useful for feeding growing lambs up to 50% protein replacement levels, with little adverse effect on immunity and pathology.

Key words: Detoxified karanj seed cake, Immunity, Pathology, Sheep

Introduction

Feed cost is an important factor in animal production system which influences overall profitability. The use of conventional protein source is becoming costlier day by day and non-availability of quality protein supplements is a limitation in animal production systems. In India, production of karanj (*Pongamia glabra*) for edible oil and industrial (biodiesel)/medicinal purposes is gaining importance which makes the byproduct available for animal use as feed source. It contains a furanoflavanoid, karanjin, an anti-nutritional factor that adversely affects the performance in various species like cows, goat, pigs and broilers (Samanta *et al.*, 1986; Konwar *et al.*, 1987; Srivastava *et al.*, 1990; Panda *et al.*, 2004). Hence, the present study was undertaken to understand the effect of feeding detoxified karanj cake (dKC) as a replacement for soya bean meal on immunity and pathology in Bannur crossbred lambs.

Materials and Methods

Twenty-four male Bannur cross (native of Karnataka state) lambs at 4-6 months of age were randomly divided into four groups (n=6) and fed with different detoxified karanj cake (dKC) levels of 0 (dKC 0), 25 (dKC 25), 50 (dKC 50) and 75 (dKC 75) percent soya bean replacement for 140 days. Animal experiments were

carried out as per guidelines of the Committee for the Purpose of Control and Supervision of Experiments on Animals (CPCSEA), India. Feed requirement of lambs for maintenance and growth was calculated (ICAR, 1998). Peste Des Petits Ruminants (PPR) vaccine (1 ml) containing 10³ tissue culture infective dose 50 (TCID₅₀) subcutaneous route was administered. Blood samples were collected in vacutainer tubes on the 14th day after vaccination, serum was separated by centrifuging at 1500 rpm for 10 min and stored at -20°C. Antibody titer against PPR was determined by using competitive enzyme linked immunosorbent assay kit of the Indian Veterinary Research Institute, India (Singh *et al.*, 2004) and expressed as percent of inhibition values. Blood samples were collected in heparin tubes on the 140th day from four sheep in each group. The 3 (4,5-dimethyl thiazol-2-yl) 2,5 diphenyl-tetrazolium bromide (MTT) colorimetric assay for proliferation of lymphocytes against Concanavalin A (Sigma, USA) was carried out with some modifications (Bounous *et al.*, 1992). Data obtained were analysed statistically by one way analysis of variance (ANOVA) as per Snedecor and Cochran (1980) and using SAS (2012). Sheep were sacrificed after 4 months and examined grossly, and tissues like liver, kidney, spleen, intestine, heart, mesenteric lymph node, testis and lung were collected in 10% formalin. The fixed tissues were processed, stained with haematoxylin and eosin (Bancroft and Stevens, 1996) and examined for histological changes under light

microscope.

Results

Iso-nitrogenous and Iso-caloric concentrate ingredients and chemical composition were presented in Table 1. The crude protein was 22.33 and 4% in concentrate mixture and finger millet straw, respectively. The total dry matter consumption was 95.87, 90.15, 79.12 and 71.51 kg in dKC 0, dKC 25, dKC 50 and dKC 75, respectively. Mean±SE PPR antibody titers were 25.18 ± 1.09 , 30.19 ± 1.01 , 25.51 ± 1.19 and 12.16 ± 0.38 in dKC 0, dKC 25, dKC 50 and dKC 75, respectively. Significant ($P < 0.05$) decrease in PPR antibody titer in dKC 75 group was observed. The mean±SE stimulation index was 1.08 ± 0.04 , 1.16 ± 0.09 , 1.18 ± 0.12 and 1.10 ± 0.09 in dKC 0, dKC 25, dKC 50 and dKC 75, respectively. There was no significant difference in mean stimulation index of lymphocytes between different groups. On gross examination, organs revealed no changes. On histological examination, dKC 50 fed group showed mild fusion of intestine villi, loss of epithelial cells, crypt elongation (Fig. 1A). The testis showed interstitial edema between tubules and damage to seminiferous tubular epithelial cells (Fig. 1B). Mesenteric lymph node showed mild depletion of lymphocytes in the lymphoid follicle with starry appearance (Fig. 1C). The dKC 75 fed group showed damage to intestinal villi with fusion and loss of epithelial cells with infiltration of mononuclear cells (macrophages, lymphocytes and plasma cells) around the crypts of intestine (Fig. 1D). The testis showed severe edema and damage with infiltration of inflammatory cells (Fig. 1E). The mesenteric lymph node showed severe depletion of lymphocytes and edema (Fig. 1F) when compared to dKC 0.

Discussion

The dry matter intake was reduced in dKC fed groups in dose dependent manner and concurred with a previous report (Fatahnia *et al.*, 2010). This might be due to the presence of karanjin, pongamol and glabrin, an amino acid which was unpalatable, pungent and toxic (Rao and Rao, 1941; Soren *et al.*, 2008). There was significant decrease in PPR antibody titer in dKC 75 fed lambs, concurring with a previous finding (Nagalakshmi *et al.*,

2011). This might be due to decreased feed intake and the protein required for producing antibodies was not available. Cell mediated immunity was not affected by feeding dKC in growing lambs and was in agreement with the immune competence study conducted in broilers (Panda *et al.*, 2008). However, karanj cake fed at 12% level reduced performance and immune competence in sheep (Nagalakshmi *et al.*, 2011) while the present study showed improvement in the detoxification process. In dKC 50 fed lambs showed histological changes in

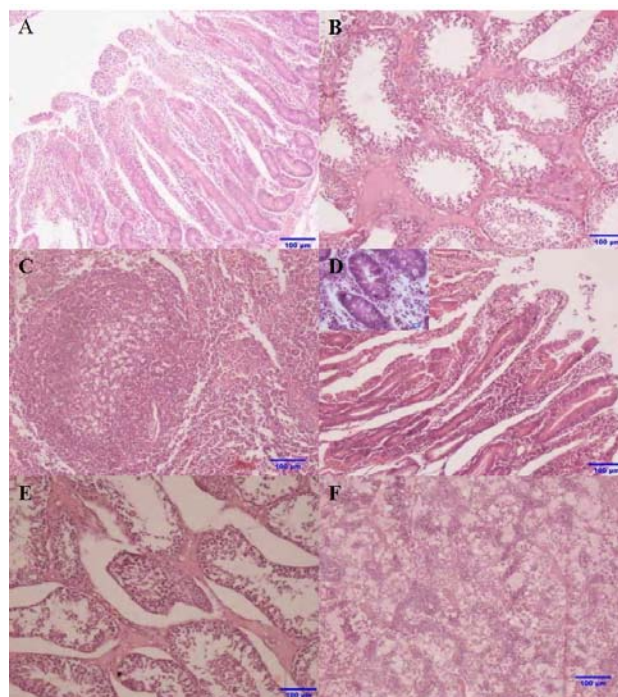


Fig. 1: (A) Intestine of dKC 50 group showed damage to intestine villi with fusion and crypt elongation (H&E, bar=100 μ m). (B) Testis of dKC 50 group showed interstitial edema and mild damage to seminiferous tubules (H&E, bar=100 μ m). (C) Mesenteric lymph node of dKC 50 showed mild depletion of lymphocytes with starry appearance in the follicle (H&E, bar=100 μ m). (D) Intestine of dKC 75 showed damage to intestinal epithelial cells with loss of villi, crypt elongation and infiltration of mononuclear cells around intestinal crypts (inset) (H&E, bar=100 μ m, inset H&E, bar=20 μ m). (E) Testis of dKC75 showed sever damage of seminiferous tubules with interstitial edema (H&E, bar=100 μ m). (F) Mesenteric lymph node showing severe loss of lymphocytes with edema fluid (H&E, bar=100 μ m)

Table 1: Feed and chemical composition of diets fed to experimental lambs

Ingredient and chemical composition (%)	dKC 0	dKC 25	dKC 50	dKC 75
Maize	31	31	33	34
Soya bean meal	30	22.5	15	7.5
Detoxified karanj seed cake	0	9	18	29
Wheat bran	36	34.5	31	26.5
Commercial mineral mixture	2	2	2	2
Salt	1	1	1	1
Total	100	100	100	100
Organic matter	91.70	92.13	93.28	93.69
Crude protein	22.75	22.57	22.30	21.72
Acid detergent fibre	8.89	8.63	9.05	8.57

intestine, testis and mesenteric lymph nodes and concurred with previous reports (Gowda *et al.*, 1996; Singh *et al.*, 2006; Nagalakshmi *et al.*, 2012). The dKC 75 intestine, lymph node and testis showed severe histological changes, indicating the presence of toxic effects and concurred with previous reports (Gowda *et al.*, 1996, Singh *et al.*, 2006; Nagalakshmi *et al.*, 2012).

In conclusion, the dKC at higher levels showed reduction in feed intake, humoral immunity and histological changes in intestine, lymph node and testis. This study showed improvement in detoxification process from the previous studies which showed toxicity at low levels of karanj seed cake fed to sheep. Further research studies were required for detoxification process of the karanj seed cake. Thus dKC can be used up to 50% level of replacement of protein source in feed of growing lambs, which ultimately reduces the feed cost and increases profit to farmers in India.

Acknowledgement

This work was financially supported by the Department of Biotechnology, Government of India.

References

- Bancroft, JD and Stevens, A** (1996). *Theory and practical of histological staining techniques*. 4th Edn., London, Churchill Livingstone. PP: 53-134.
- Bounous, DI; Campagnolid, RP and Bram, J** (1992). Comparison of MTT colorimetric assay and tritiated thymidine uptake for lymphocyte proliferation assays using chicken splenocytes. *Avian Dis.*, 36: 1022-1027.
- Fatahnia, F; Rowghani, E; Hosseini, A; Darmani Kohi, H and Zamiri, MJ** (2010). Effect of different levels of monensin in diets containing whole cottonseed on milk production and composition of lactating dairy cows. *Iranian J. Vet. Res.*, 11: 206-213.
- Gowda, SK; Katiyar, RC; Sharma, AK and Sastry, VRB** (1996). Blood biochemical profile and histopathology of vital organs in rabbits fed on processed neem (*Azadirachta indica*) kernel meal incorporated diets. *Asian Austral. J. Anim. Sci.*, 9: 471-476.
- ICAR** (1998). *Nutrient requirement of livestock and poultry*. 1st Edn., New Delhi, India, Indian Council of Agricultural Research (ICAR). P: 13.
- Konwar, BK; Banerjee, GG and Mandal, L** (1987). Effect of feeding deoiled karanj (*Pongamia glabra vent*) cake on quantity and quality of milk in crossbred cow. *Indian Vet. J.*, 64: 62-65.
- Nagalakshmi, D; Dhanalakshmi, K and Himabindu, D** (2011). Replacement of groundnut cake with sunflower and karanj seed cakes on performance, nutrient utilization, immune response and carcass characteristics in Nellore lambs. *Small Ruminant Res.*, 97: 12-20.
- Nagalakshmi, D; Himabindu, D and Anand Kumar, A** (2012). Studies on the pathology of sunflower cake and Karanj seed cake in comparison to groundnut cake in lambs. *ARN J. Sci. Tech.*, 2: 191-194.
- Panda, AK; Anand Kumar, A; Singh, SD and Sastry, VRB** (2008). Growth performance and pathological lesions in broiler chickens fed raw or processed Karanj (*Pongamia glabra*) cake as protein supplement. *Indian J. Anim. Sci.*, 78: 997-1001.
- Panda, AK; Sastry, VRB; Mandal, AB; Saha, SK and Kumar, A** (2004). Effect of dietary incorporation of raw and processed Karanj cake (*Pongamia glabra*) on nutrient retention and immune competence of broiler chicks. *Anim. Nutr. Feed Tech.*, 4: 121-143.
- Rao, NVS and Rao, JV** (1941). A note on glabrin: a new component of seeds of *Pongamia glabra*. *Proc. Indian Acad. Sci.*, 14: 123-125.
- Samanta, G; Chaterjee, DP and Banerjee, GG** (1986). Effect of feeding Karanj (*Pongamia glabra vent*) cake on feed efficiency and growth in pigs. *Indian J. Anim. Nutr.*, 3: 270-273.
- SAS** (2012). *Statistical Analysis System*. Software Version 9.3, SAS India Limited, India.
- Singh, P; Sastry, VRB; Garg, AK; Sharma, AK and Agarwal, DK** (2006). Effect of long term feeding of expeller pressed and solvent extracted Karanj (*Pongamia pinnata*) seed cake on the performance of lambs. *Anim. Feed Sci. Tech.*, 126: 157-167.
- Singh, RP; Sreenivasa, BP; Dhar, P; Shah, LC and Bandyopadhyay, SK** (2004). Development of monoclonal antibody based competitive ELISA for detection and titration of antibodies to peste des petits ruminants (PPR) virus. *Vet. Microbiol.*, 98: 3-15.
- Snedecor, GW and Cochran, WG** (1980). *Statistical methods*. 7th Edn., Ames, Iowa, USA, The Iowa State University Press. PP: 196-252.
- Soren, NM; Sastry, VRB; Saha, SK; Wankhade, UD; Lade, MH and Kumar, A** (2008). Performance of growing lambs fed processed karanj (*Pongamia glabra*) oil seed cake as partial protein supplement to soybean meal. *J. Anim. Physiol. Anim. Nutr.*, 93: 237-244.
- Srivastava, JP; Gupta, BS; Thakur, S and Verma, AK** (1990). Utilization of deoiled Karanj (*Pongamia glabra*) cake in kid grower rations. *Indian J. Anim. Nutr.*, 7: 15-20.