

Short Paper

A study on gastrointestinal helminths of camels in Mashhad abattoir, Iran

Borji, H. *; Razmi, Gh.; Movassaghi, A. R.;
Naghibi, A. Gh. and Maleki, M.

Department of Pathobiology, Faculty of Veterinary Medicine, Ferdowsi University of Mashhad, Mashhad, Iran

*Correspondence: H. Borji, Department of Pathobiology, Faculty of Veterinary Medicine, Ferdowsi University of Mashhad, Mashhad, Iran. E-mail: hborji@um.ac.ir

(Received 2 Aug 2009; revised version 20 Dec 2009; accepted 28 Dec 2009)

Summary

Abattoir survey was carried out to determine the prevalence of gastrointestinal helminths and the seasonal fluctuations in intestinal worm burdens and faecal worm egg counts of camel in Khorasan Razavi province in the northeast of Iran. A total of 306 dromedaries (*Camelus dromedarius*) in the Mashhad abattoir, in the northeast of Iran and the capital of Khorasan province were examined between October 2007 and September 2008. By coproscopy examinations, 75.1% of dromedaries were found to be harboring different types of nematod eggs. Faecal flotation revealed the presence of *Nematodirus*, *Strongyloides*, *Trishuris*, *Marshallagia*, stongyle type nematode eggs. In addition, gastrointestinal tracts of 50 camels slaughtered in the Mashhad abattoir were used for identification and count of helminths. Postmortem examinations revealed that the prevalence of helminths were *Trichostrongylus probolurus* (64%), *Trichuris globulosa* (40%), *Camelostrongylus mentulatus* (38%), *T. colubriformis* (34%), *Stilesia globipunctata* (30%), *Nematodirella dromedarii* (22%), *Haemonchus longistipes* (18%), *Nematodirus oiratianus* (16%), *Cooperia oncophora* (16%), *Trichuris barbetonensis* (10%), *Parabronema skrjabini* (10%), *Nematodirella cameli* (10%), *Marshallagia marshalli* (4%), *Teladorsagia circumcincta* (4%), *Moniezia benedeni* (3%), *Moniezia expansa* (3%) and *Trichostrongylus vitrinus* (2%). *Nematodirella dromedarii*, *Trichostrongylus probolurus*, *Trichostrongylus colubriformis*, *Cooperia oncophora*, and *Nematodirus oiratianus*, were identified from dromedary in Iran for the first time. The pathological lesions in the affected abomasums, as well as small and large intestines, were hyperaemic and thickened mucosa with haemorrhagic foci. Histopathological examination revealed inflammatory reaction in the abomasa, flattened mucosa and villous atrophy with inflammatory reactions composed of eosinophils and lymphocytes in the intestines, respectively. The prevalence observed in the present study indicates the necessity of using an anthelmintic drug for increasing the health and productivity of camels.

Key words: Gastrointestinal helminths, Prevalence, Pathology, *Camelus dromedarius*, Iran

Introduction

The camel has been considered an aid to man for thousands of years in many different respects and has a high economic value by providing meat, milk and wool as well as transportation and labor. Due to its physiological attributes, the camel is the most suitable domestic mammal for use in climatic extremes. Understanding and utilizing this special gift could lead to the development of camel farms in famine areas and a reduction in human starvation.

Pathogenic diseases, poor nutrition and traditional management systems have restricted their full utilization (Bekele, 2002).

Gastrointestinal helminths injure their hosts by a wide variety of mechanisms, mainly reduction in voluntary food intake, loss of productivity and diarrhea. However, the clinical manifestation of helminthiosis is subclinical or asymptomatic in which animals appear normal but are performing at below their full potential. The available information about dromedary in Iran are just

the investigation based on post mortem examination with limited numbers of dromedaries within a short period of time (Mirzayans and Halim, 1980; Radfar *et al.*, 2006). Moreover, few studies have been conducted on GI helminths of Camels (El Bihari, 1985; Abdul-Salam and Farah, 1988; Abdul-Mogod, 2001; Bekele, 2002). Hence, the present study was designed to provide preliminary information on the prevalence rates, seasonal abundance and type of helminthes, along with describing both gross and microscopic changes caused by these parasites in camels.

Materials and Methods

Sampling and study area

This study was conducted on 306 dromedaries of different age and sex slaughtered in the Mashhad abattoir, in the northeast of Iran during October 2007 to September 2008. The slaughtered camels were imported from Afghanistan and Pakistan. After slaughtering the dromedaries, faecal samples were collected directly from the rectum and placed in universal sampling bottles. The samples were preserved in ice during transportation to the laboratory and examined within 2 h after sampling.

Faecal examination

Faecal egg counts were determined by the Clayton Lane technique using a saturated solution of sodium chloride as the floating medium to assess the level of infestation (Anon., 1977). Nematode egg percentage was identified using standard parasitological criteria (Anon., 1977; Soulsby, 1982).

Necropsy worm counts

Following slaughter, the entire gastrointestinal tracts of 50 slaughtered dromedaries were collected and examined randomly. Different parts of the gastrointestinal tract were separated by ligature and transported to the laboratory.

Each part was cut longitudinally and the mucosa examined and scraped carefully to remove any adhering worms. The contents of each part were washed into a tray using tap water. The entire washings of the

abomasums, and the small and large intestines were completely examined to find the parasites. Identification and counting was conducted based on Yamaguti (1961), Soulsby (1982) and Anon. (1984).

Pathology

The different parts of the gastrointestinal system of the animals including abomasums, small intestine and large intestine were examined for pathological changes. The gross characteristics of the lesions were described and recorded. Selectively, tissue specimens were collected, preserved in 10% formalin solution and processed by routine histopathological techniques and stained with haematoxylin and eosin and examined histologically.

Statistical analysis

For statistical evaluation of the results, SPSS 15 (SPSS for windows Ver. 15) was used. One-way ANOVA test was used to determine the effects of season on fecal egg count and LSD method was applied to analyse seasonal differences. The Chi-square test was used for comparison of infection rate in different seasons (Mead and Curnow, 1983).

Results

Out of the 306 camels examined during the study period, 230 cases (75.1%) were positive for different types of nematode eggs in their faeces (Table 1). The nematode eggs recovered from the camels belonged to *Nematodirus*, *strongyloides*, *Trishuris*, *Marshallagia*, stongyle type nematodes. The number, type and prevalence of nematode genera recovered from the gastrointestinal tracts of the 50 camels are given in Table 2 and Fig. 1.

Mean EPG in summer was significantly higher than spring and autumn ($P < 0.0004$, $P < 0.013$), but there was no significant difference with winter ($P > 0.05$). However, no significant difference was found between the proportion of infected dromedaries in different seasons ($P > 0.05$).

During the course of study, macroscopic lesions were first seen in abomasums of dromedaries caused by *Haemonchus*

Table 1: Seasonal prevalence and nematode eggs recovered from dromedary in the abattoir of Mashhad in Khorasan province

Season	Sample size	Infected animals and infection rate	EPG max and min	EPG mean \pm SEM
Spring	89	72 (81.7%)	0-900	41.58 \pm 12.61
Summer	32	27 (84.37%)	0-1500	155.53 \pm 55.08
Fall	138	97 (70.28%)	0-1400	62.74 \pm 14.86
Winter	47	34 (72.34%)	0-1100	85.29 \pm 32.97
Total	306	230 (75.1%)	0-1500	69.75 \pm 10.91

Table 2: Prevalence of adult helminths parasites recovered from camels slaughtered at Mashhad abattoir in Khorasan province of Iran (n = 50)

Organ	Adult helminths	Prevalence (%95 CI)
Abomasum	<i>Camelostrongylus mentulatus</i>	38 (23-49)
	<i>Haemonchus longistipes</i>	18 (7.4-28.6)
	<i>Parabronema skrjabini</i>	10 (1.7-18.3)
	<i>Marshallagia marshalli</i>	6 (2.7-9.3)
	<i>Teladorsagia circumcincta</i>	4 (0-9.4)
Small intestine	<i>Trichostrongylus probolurus</i>	64 (50.7-77.3)
	<i>Trichostrongylus colubriformis</i>	34 (20.9-47.1)
	<i>Nematodirella dromedarii</i>	22 (10.6-33.4)
	<i>Nematodirella cameli</i>	10 (1.7-18.3)
	<i>Nematodirus oiratianus</i>	16 (5.8-26.2)
	<i>Cooperia oncophora</i>	16 (5.8-26.2)
	<i>Trichostrongylus vitrinus</i>	2 (0-5.8)
	<i>Cestodes</i>	
	<i>Stilesia globipunctata</i>	30 (17.3-42.7)
	<i>Moniezia expansa</i>	4 (0-9.4)
	<i>Moniezia benedeni</i>	4 (0-9.4)
Large intestine	<i>Trichuris globulosa</i>	40 (26.5-53.5)
	<i>Trichuris barbetonensis</i>	10 (1.7-18.3)

longistipes including thickened walls and edematous folds associated with haemorrhagic foci (Fig. 2). Histologically, there were abundant mucus secreting gastric cells, inflammatory reactions mainly of lymphocytes and eosinophils and hyperemia in the abomasal mucosa of infected animals when compared with non-infected animals.

Trichostrongylus infected small intestines showed mucosal edema with small petechial foci. Histologically there were flattening of the mucosa and villous atrophy, with inflammatory reactions in the lamina propria and less so in the submucosa, where multifocal infiltrates composed of the majority of eosinophils, scarce macrophages, and lymphocytes were observed (Fig. 3). Parasites were often found in superficial channels parallel with the luminal surface.

There were heavy infections of *Trichuris* spp. in large intestines which caused

thickened mucosa with haemorrhagic foci. Histologically, there was flattened epithelium with a few dilated glands, and hyperemia with moderate increase in inflammatory cells composed of eosinophils and lymphocytes (Fig. 4).

Discussion

Few studies have been conducted on the prevalence and pathological lesions of gastrointestinal helminths of dromedary (*Camelus dromedarius*) in Iran. In the present work, we have carried out a 1 year abattoir survey aimed at determining the prevalence and seasonal incidence of gastrointestinal (GI) helminths of camel in the abattoir of Mashhad. From October 2007 to September 2008, faecal samples were collected from slaughtered camels. From 306 dromedaries examined, 75.1% were infected by nematodes. This finding is in

agreement with that of Bekele (2002) in Ethiopian dromedaries, but lower than camels in Jordan (Sharrif *et al.*, 1997). The coprological examination also showed that strongyle egg type was the most prevalent,

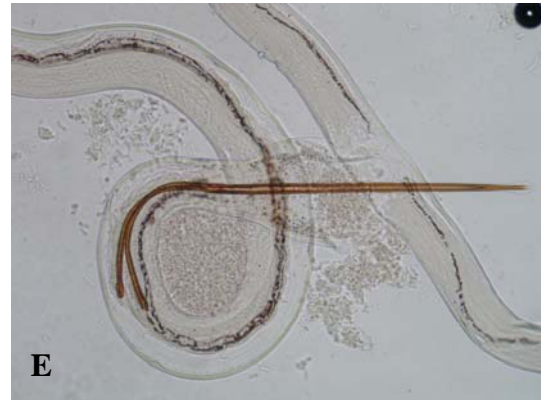
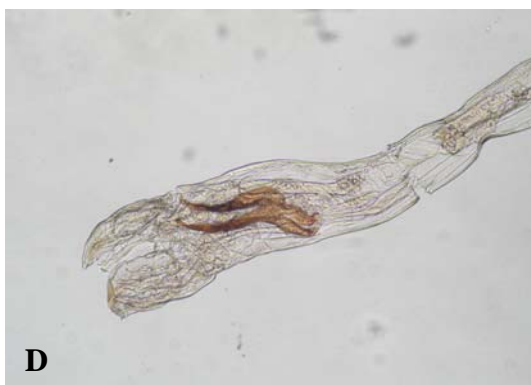
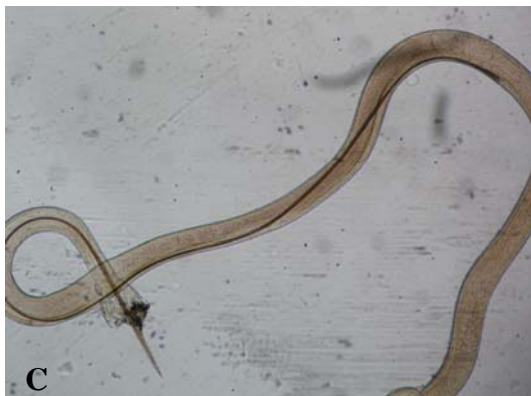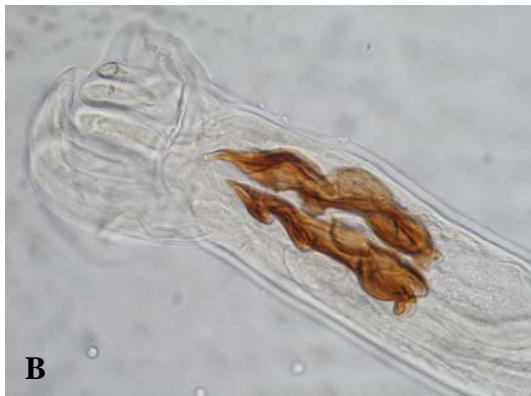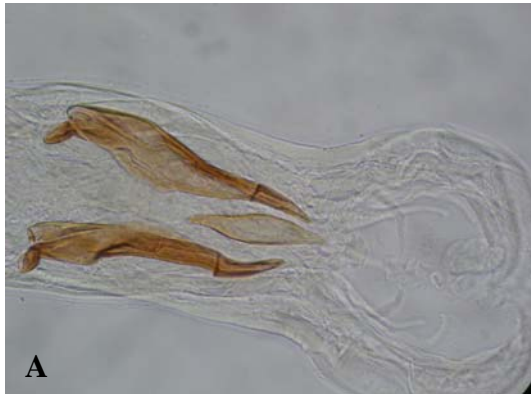Fig. 1: Identified helminthes from dromedary in Iran (for the first time). A: *Trichostrongylus culobriiformis*, B: *Trichostrongylus probolurus*, C: *Nematodirella dromedarii*, D: *Cooperia oncophora*, and E: *Nematodirus oiratianus*

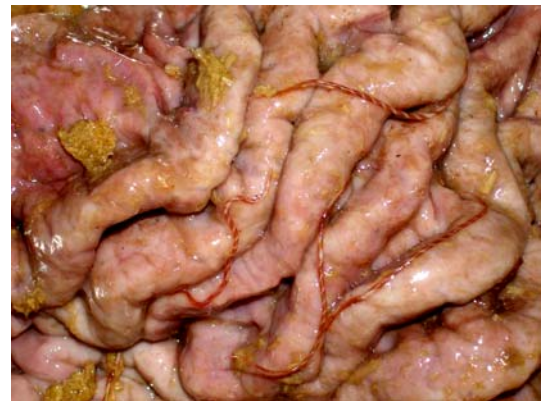

Fig. 2: *Haemonchus longistipes* with barber pole appearance in hyperaemic and edematous abomasum

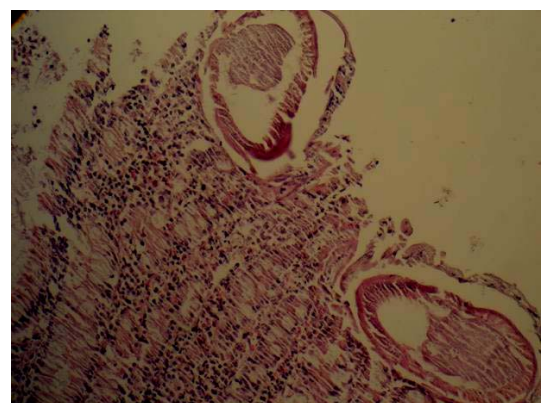


Fig. 3: Section of small intestine showing villous atrophy, inflammatory cells (eosinophils, macrophages, and lymphocytes) and sections of parasites, (H&E, $\times 320$)

which was consistent with Egyptian dromedaries (Abdul-Mogod, 2001).

Investigation of the adult parasites in the

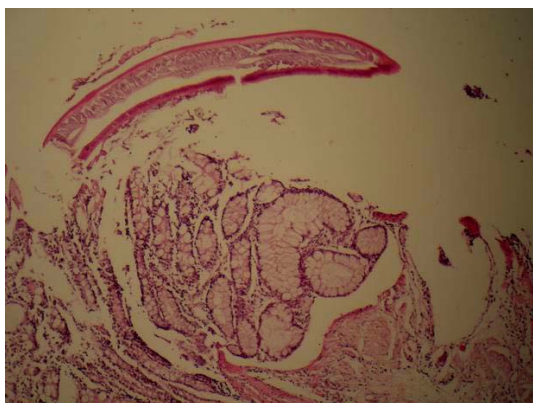


Fig. 4: Epithelial desquamation and goblet cell hyperplasia with infiltration of inflammatory cells. There is also a section of *Trichuris* in the luminal surface of the large intestine, (H&E, ×160)

gastrointestinal organs of 50 dromedaries revealed that, *Camelostrongylus mentulatus* had a high prevalence rate in the abomasums, whereas *Haemonchus longistipes*, *Marshallagia marshalli* and *Parabronema skrjabini*, *Teladorsagia circumcincta* were few. *Trichostrongylus probolurus* had a high prevalence rate in the small intestine, but *Nematodirella dromedarii*, *Nematodirella cameli*, *Trichostrongylus colubriformis*, *Trichuris globulosa*, *Cooperia oncophora*, *Nematodirus oiratianus*, and *Trichostrongylus vitrinus* were identified in few cases. Moreover, cestodes such as *Stilesia globipunctata* had a high prevalence rate and *Moniezia benedeni*, *Moniezia expansa*, were few. Some nematode genera recovered at necropsy during the present study have been recorded previously from *Camelus dromedarius* in some parts of Iran (Mirzayans and Halim, 1980; Radfar *et al.*, 2006). In previous studies, helminths of *Camelostrongylus mentulatus*, *Parabronema skrjabini*, *Haemonchus contortus*, *Haemonchus longistipes*, *Teladorsagia circumcincta*, *Marshallagia marshalli*, *Physocephalus sexalatus*, *Ascarops strongylina*, *Nematodirella longissimespiculata*, *Nematodirella cameli*, *Trichuris globulosa*, *Stillesia globipunctata*, and *Moniezia benedeni* were reported. Some nematode species like *Physocephalus sexalatus* and *Ascarops strongylina* recovered from abomasums in previous reports were not encountered in the present

study. A possible explanation for this difference is that *Physocephalus sexalatus* and *Ascarops strongylina* are parasites of pigs and are considered to be accidental parasites of camel. Some genera of observed helminthes in this study were also reported from other regions (El Bihari and Kawasmeh, 1980; El Bihari, 1985; Abdul-Salam and Farah, 1988; Sharrif *et al.*, 1997; Bekele, 2002). In the present study, *Nematodirella dromedarii*, *Trichostrongylus probolurus*, *Trichostrongylus colubriformis*, *Cooperia oncophora* and *Nematodirus oiratianus* were reported from Iranian dromedaries for the first time.

There is paucity of literature as helminthes infections of camels are generally regarded as less of a problem than those in other ruminants. However, gastrointestinal nematodes are known to undermine the overall health and productivity of camels. *Haemonchus longistipes* is the most pathogenic strongyle nematode of camels that may be associated with clinical disease and can be fatal. *Trichostrongylus* spp may contribute to the debilitating effects (Soulsby, 1982). The damage caused by these nematodes included abundant mucus secreting gastric cells, flattening of the mucosa, villous atrophy, haemorrhages and cellular infiltration, mainly of eosinophile. These lesions could reduce the productivity of the infected dromedary through disturbances of intestinal absorption (McGavin and Zackary, 2007).

In conclusion, the results of this study showed that strategic deworming of camel using broad-spectrum anthelmintics is necessary to increase the productivity of camels. Moreover, further epidemiological studies should be conducted in different seasons and regions of the country to provide more information about the seasonal dynamics of the gastrointestinal helminths of dromedary in Iran.

Acknowledgements

The authors are grateful to Dr. Azizzadeh for data analysis. We thank Mr. H. Eshrati for his technical assistance during data collection and Mr. M. Mohammad Nejad for taking pictures. This work was

supported by Ferdowsi University of Mashhad and grant No. 709.

References

- Abdul-Mogod, SZ (2001). Studies on helminth parasites of gastrointestinal tract of camels. MSc Thesis, Cairo University, Egypt.
- Abdul-Salam, JM and Farah, MA (1988). Seasonal fluctuations of gastrointestinal helminths of camels in Kuwait. *Vet. Parasitol.*, 28: 93-102.
- Anon. (1977). *Manual of veterinary parasitological laboratory techniques*. Technical Bulletin No. 18. London, Ministry of Agriculture, Fisheries and Food. P: 129.
- Anon. (1984). *Manual of veterinary investigation, laboratory techniques*. Vol. 2. HMSO, London, Ministry of Agriculture, Fisheries and Food. PP: 141-142, 162-176.
- Bekele, T (2002). Epidemiological studies on gastrointestinal helminths of dromedary (*Camelus dromedarius*) in semi-arid lands of eastern Ethiopia. *Vet. Parasitol.*, 105: 139-152.
- El Bihari, S (1985). Helminths of the camel: a review. *Br. Vet. J.*, 141: 315-326.
- El Bihari, S and Kawasmeh, ZA (1980). Occurrence and seasonal variation of some gastrointestinal helminths of the dromedary, *Camelus dromedarius*, in Saudi Arabia. *Proceedings of the Saudi biological society*. 4: 297-304.
- McGavin, MD and Zachary, JE (2007). *Pathologic basis of veterinary disease*. 4th Edn., St. Louis, Missouri, Mosby-Elsevier. PP: 388-389.
- Mead, R and Curnow, RN (1983). *Statistical methods in agriculture and experimental biology*. Chapter 1. London, Chapman and Hall.
- Mirzayans, A and Halim, R (1980). Parasitic infection of *Camelus dromedarius* from Iran. *Bull. Soc. Pathol. Exot. Filiales*. 73: 442-445.
- Radfar, MH; Ebrahimi Maimand, A and Sharify, A (2006). A report on parasitic infections in camel (*Camelus dromedarius*) of Kerman slaughterhouse. *J. Fac. of Vet. Med., University of Tehran*. 61: 165-168 (Article in Persian).
- Sharrif, L; Al-qudah, KM and Al-Ani, FK (1997). Prevalence of gastrointestinal helminths in one-humped camel (*Camelus dromedarius*) in Jordan. *J. Dromed. Pract. Res.*, 41: 67-69.
- Soulsby, E.J.L (1982). *Helminths arthropods and protozoa of domesticated animals*. 7th Edn., London, Bailliere Tindall. PP: 231-250.
- Yamaguti, S (1961). *Systema helminthum*. In: *Nematodes of mammals*. Vol. 3, Part 5, London, Interscience Publishers Ltd., PP: 410-460.