

Short Paper

A novel farm technology to quantify dairy cow cervix morphology: oestrus versus non-oestrus models

Nikkhah, A.^{1*} and Karimzadeh, S. M.²

¹Department of Animal Sciences, Faculty of Agricultural Sciences, University of Zanjan, Zanjan, Iran; ²MSc Student in Animal Nutrition, Department of Animal Sciences, Faculty of Agricultural Sciences, University of Zanjan, Zanjan, Iran

*Correspondence: A. Nikkhah, Department of Animal Sciences, Faculty of Agricultural Sciences, University of Zanjan, Zanjan, Iran. E-mail: nikkhah@znu.ac.ir

(Received 28 Jun 2011; revised version 1 Sept 2012; accepted 16 Dec 2012)

Summary

The objective was to quantify and compare cow cervical morphology on oestrus vs. non-oestrus days using a new farm technology. The cervical tissues were videotaped using a cervixscope involving new camera equipment in four Holstein cows on multiple oestrus and non-oestrus days to score tissue morphology as altered by oestrus. The non-oestrous days were in diestrus phases. The videotaped records were processed in a computer installed with an image processing software. Cervix central positioning, movements, mucosal secretions, and clarity in the captured images were scored visually, each on a 5-point basis. Cervical regions were significantly more discrete, more mucosal, more central, and more stable on standing oestrus days than on non-oestrus days. During standing oestrus, the cervix was lucidly visible and rigidly positioned in the central end of vagina, whereas non-oestrus cervixes were unstable and hardly separable from surrounding tissues. Findings demonstrate the on-farm feasibility of the novel inexpensive cervixscope as a farm management tool for quantifying cervix morphology.

Key words: Cervix, Cow, Oestrus, Morphology, Reproduction

Introduction

Concurrent improvements in cow production and reproduction have been a challenge (Studer, 1998; Moore and Thatcher, 2006). In many farms, the favorable calving interval is considered to be about 12-13 months (Strandberg and Oltenacu, 1989; Norman *et al.*, 2009), which may not necessarily be optimal. Optimum fertility may be targeted more feasibly using artificial insemination (AI) for on-time breeding and improved conception rates (Senger, 1994; Lima *et al.*, 2010). However, effective AI requires skilled technical proficiency and accurate oestrus detection, which are both challenging tasks (Redden *et al.*, 1993; Senger, 1994; Lima *et al.*, 2010).

A common challenge towards successful oestrus detection is the occurrence of short or variable-in-length oestrous cycles. Such

irregular cycles do not permit a timely monitoring of cow behavior and cyclic reproductive events. Every missing of oestrus signs postpones cow pregnancy by a minimum of about 21 days, thus elongating days-open and imposing major costs (Moore and Thatcher, 2006). Visual observation and tail painting (Xu *et al.*, 1998), physical activity recordings with pedometers (Lovendahl and Chagunda, 2010), perineal odors detection by electronic noses (Lane and Wathes, 1998), and milk progesterone (Moore and Spahr, 1991) have been utilized to timely detect oestrus. However, these approaches are rather expensive, laborious, or overly technical. In addition, utilizing only a single method will not guarantee optimal conception rates and reproduction (Nikkhah, 2011). Therefore, a complementary uncomplicated, feasible, low-price, and accurate technique will be an on-

farm advantage. The objective was to demonstrate the on-farm feasibility of a new technology to monitor changes in cow cervical morphology during standing-oestrus vs. non-oestrus days of the oestrous cycle. The technology utilized a new reproductive tract camera system for recording cervical and vaginal images (Nikkhah *et al.*, 2011).

Materials and Methods

Farm and cow management

The study was conducted at the Dairy Facilities of the University of Zanjan's Research Farm (Zanjan, Iran) in autumn of 2009. The dairy farm had a total of 190 Holstein cattle including 50 milking cows. Cows were milked 3 times daily at 0500, 1300, and 2100 h. Alfalfa hay and a barley grain-based concentrate were delivered 3 and 4 times daily, respectively. Four multiparous and primiparous Holstein cows (50 ± 14 days in milk, 30.3 ± 3.5 kg milk yield, 668 ± 59 kg BW) were monitored for standing-oestrus expression in multiple oestrous cycles in a split-plot design with cow as the main plot/effect ($n=4$). The standing-oestrus occurred when a cow was prepared to be mounted by others.

Technology description and cervix morphology quantification

The experimental cows were monitored for a minimum of one month pre- and post-experiment to allow accurate oestrus detection. Oestrus was ensured with the observance of "the standing-to-be-mounted" sign that would occur approximately every 21-d. The non-oestrus monitoring days were in diestrus phases of the oestrous cycle. On separate standing-oestrus and non-oestrus days, the cervix was digitally videotaped by the same trained individual using an apparatus designed for monitoring cervical regions (Fig. 1). The apparatus was disinfected and cleaned after each insertion both within and between cows. The apparatus had a round shape with 45 cm length and 2.7 cm diameter with internal electrical settings and an external polyvinyl cover. The apparatus was equipped with lights on the front side and with electrical wires on its terminal (Fig. 1). It was

connected to a computer installed with recording software capable of capturing images (Fig. 2). The apparatus was inserted vaginally only at the time of monitoring. The images captured were visually and blindly scored by the same trained individual for a) distinctness, b) motility, c) positioning, and d) secretions of the cervix (Figs. 3a, b). The morphology was scored on a standard 1 to 5 point basis. The scorer was trained to acquire adequate skills and repeatable scores on images before scoring. The score of 5 represented fully a) distinct, b) static, c) central-stable, and d) mucosal (egg-white like mucus) cervixes. The score of 2, 3, and 4, respectively were slightly, moderately, and mostly a) distinct, b) static, c) central-stable, and d) mucosal cervixes. The score of 1 represented fully a) unseparate, b) unstable-moving, c) angular (non-central), and d) dry (non-mucosal) cervixes.

Statistical analysis

Data were analysed using both parametric and non-parametric approaches




Fig. 1: The cervixscope apparatus with 45 cm length and 2.7 cm diameter

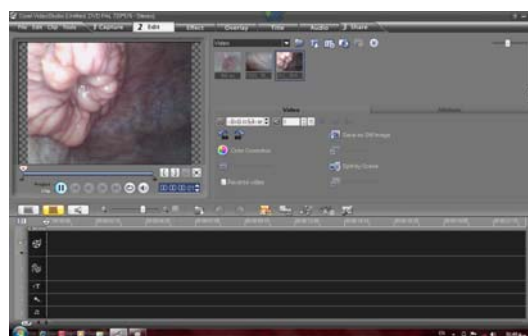

Fig. 2: Cervical tissues image capturing and processing using the software installed in the computer on-farm, connected to the apparatus shown in Fig. 1

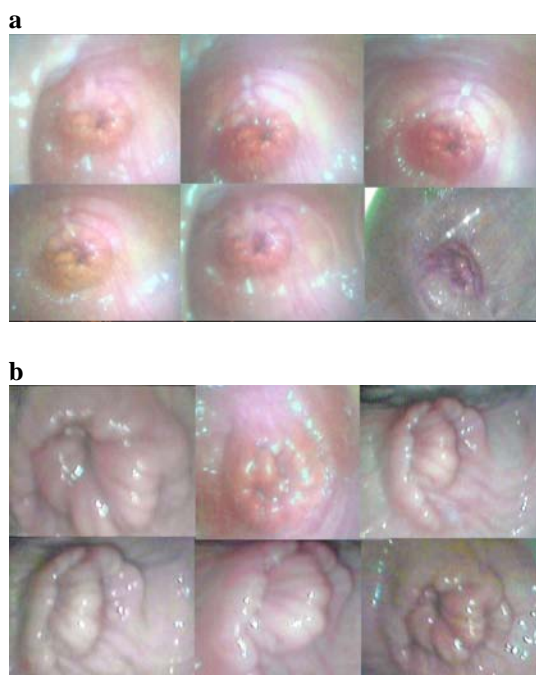


Fig. 3: Cervical regions on standing-oestrus (a) and non-oestrus (b) days. Cervix was significantly ($P<0.01$) more discrete, more mucosal, more central, and more stable on standing oestrus days than on non-oestrus days. During standing oestrus, the cervix was lucidly visible and rigidly positioned in the central end of vagina, whereas non-oestrus cervices were unstable and not quite separable from surrounding tissues

of SAS programs (SAS, 2003). Due to similar outcomes, the results were presented for the parametric method to provide accurate standard variations and ease data interpretation. Cow was the main plot within which standing-oestrus and non-oestrus cervix morphologies were compared. The split-plot statistical model included fixed effect of recording day (oestrus vs. non-oestrus) and random effects of cow within

days plus residuals. The normality of distribution and homogeneity of error variances were ensured using Kolmogorov-Smirnov, Shapiro-Wilk, and Anderson-Darling tests (SAS, 2003). The p-values <0.05 were declared as bio-significant.

Results

The cervix area was significantly ($P<0.01$) more split from its surrounding regions, more mucosal (egg-white like mucus), more central, and more stable on standing-oestrus days than on non-oestrus days (Table 1, Figs. 3a, b). During standing-oestrus, cervices were more visible, and rigidly positioned in the central end of vagina. However, on non-oestrus days, cervices were unstable and hardly separable from the surrounding tissues. The recorded tissues demonstrated the distinct cervix morphological properties during standing-oestrus vs. diestrus days of the oestrous cycle.

Discussion

This study demonstrates quantitative application of a novel, on-farm technology involving a cervixscope and an image processing system for monitoring dairy cow cervix morphology. Most recently, Nikkhah *et al.* (2011) using the same technology and methodology established a significant increasing order for standing-oestrus $>$ proestrus $>$ diestrus $>$ metestrus of a cervix distinctness, central positioning, stability, and mucosal secretions. The results promise aid in oestrus detection, particularly in cows with physiologically hidden oestrus

Table 1: Quantitative cervical morphology parameters on standing-oestrus and non-oestrus days using the cervix-monitoring technique¹

Parameter	Standing-oestrus day	Non-oestrus day	SEM	P-value $<$
Cervix clarity	4.5	2.3	0.30	0.01
Cervix motility	3.2	1.4	0.42	0.01
Cervix positioning	4.1	1.9	0.44	0.01
Cervix secretions	4.2	1.6	0.31	0.01

¹Cervix a) clarity, b) motility, c) central positioning, and d) mucosal secretions were scored each on a 5-point scale basis. The score of 5 represented fully a) distinct, b) static, c) central-stable, and d) mucosal (egg-white like mucus) cervices. The score of 2, 3, and 4, respectively were slightly, moderately, and mostly a) distinct, b) static, c) central-stable, and d) mucosal cervices. The score of 1 represented fully a) unseparate, b) unstable-moving, c) angular (non-central), and d) dry (non-mucosal) cervices

expressions or in cows under specific treatments, requiring further experimentation.

Standing-oestrus occurs when a cow is behaviorally prepared to be mounted by others that may or may not be in oestrus. Usually, cows are artificially inseminated at 12-15 h after observing the standing-oestrus. The standing-oestrus is expressed following a surge in estrogen secretion that is reflected in the morphological alterations of the reproductive tract tissues (Senger, 1994; Nikkhah, 2011). Thus, delays in on-time detection of oestrus signs most probably change the lactation curve shape. As a result, considerable economical losses may occur (De Vries, 2006; Norman *et al.*, 2009). The technology developed herein can potentially minimize such losses by helping to more accurately detect oestrus signs (Olynk and Wolf, 2008; Nikkhah, 2011). Moreover, a number of repeat-breeder cows exist that host repeated errors in oestrus detection (Senger, 1994; Kafi *et al.*, 2011). The differential cervix morphology between oestrus and non-oestrus days suggest that the technology may be utilized together with human oestrus detectors for a more timely AI and improved conception rate. Furthermore, as frequently happens, human oestrus detectors, even if well-experienced, are likely to make errors in oestrus detection, especially when multiple cows appear to be in oestrus. In such circumstances, the present method can be helpful in ensuring true oestrus diagnosis for on-time AI or breeding. For its uncomplicated structure and methodology, farm employees with brief training can proficiently utilize the technology without major costs.

A cost-effective on-farm technology was developed and applied to monitor, collect and quantify cow cervix observational morphology data. Cervices were considerably more discrete, more central, more mucosal, and more stable on standing-oestrus days than on non-oestrus days. It is suggested to utilize the technology along with human oestrus detectors for more efficient artificial insemination, especially in reproductively abnormal cows.

Acknowledgements

The Ministry of Science, Research and Technology, and University of Zanjan are acknowledged for supporting A. Nikkhah's programs of optimizing global science education.

References

- De Vries, A (2006). Economic value of pregnancy in dairy cattle. *J. Dairy Sci.*, 89: 3876-3885.
- Kafi, M; Raayat Jahromi, AR and Meimandi Parizi, A (2011). Ultrasonographic diagnosis of the retained semen straw in the uterus of a repeat breeder cow. *Iranian J. Vet. Res.*, 12: 73-76.
- Lane, AJP and Wathes, DC (1998). An electronic nose to detect changes in perineal odors associated with estrus in the cow. *J. Dairy Sci.*, 81: 2145-2150.
- Lima, FS; De Vries, A; Risco, CA; Santos, JEP and Thatcher, WW (2010). Economic comparison of natural service and timed artificial insemination breeding programs in dairy cattle. *J. Dairy Sci.*, 93: 4404-4413.
- Lovendahl, P and Chagunda, MGG (2010). On the use of physical activity monitoring for estrus detection in dairy cows. *J. Dairy Sci.*, 93: 249-259.
- Moore, AS and Spahr, SL (1991). Activity monitoring and an enzyme immunoassay for milk progesterone to aid in the detection of estrus. *J. Dairy Sci.*, 74: 3857-3862.
- Moore, K and Thatcher, WW (2006). Major advances associated with reproduction in dairy cattle. *J. Dairy Sci.*, 89: 1254-1266.
- Nikkhah, A (2011). A novel biofarm technology to monitor and quantify oestrus cervix morphology in dairy cows. *Adv. Biosci. Biotechnol.*, 2: 424-428.
- Nikkhah, A; Sirjani, MA and Assadzadeh, AA (2011). Estrus quantification of early lactation cow cervix physiology: an economical farm innovation. *J. Anim. Sci.*, (E-Suppl. 1), 89: 590.
- Norman, HD; Wright, JR; Hubbard, SM; Miller, RH and Hutchison, JL (2009). Reproductive status of Holstein and Jersey cows in the United States. *J. Dairy Sci.*, 92: 3517-3528.
- Olynk, NJ and Wolf, CA (2008). Economic analysis of reproductive management strategies on US commercial dairy farms. *J. Dairy Sci.*, 91: 4082-4091.
- Redden, KD; Kennedy, AD; Ingalls, JR and Gilson, TL (1993). Detection of estrus by radiotelemetric monitoring of vaginal and ear

- skin temperature and pedometer measurements of activity. *J. Dairy Sci.*, 76: 713-721.
- SAS (2003). *SAS User's Guide*. Version 9.1 Edn., SAS Institute Inc., Cary, NC, USA.
- Senger, PL (1994). The estrus detection problem: new concepts, technologies and possibilities. *J. Dairy Sci.*, 77: 2745-2753.
- Strandberg, E and Oltenacu, PA (1989). Economic consequences of different calving intervals. *Acta Agric. Scand.*, 39: 407-420.
- Studer, E (1998). A veterinary perspective of on-farm evaluation of nutrition and reproduction. *J. Dairy Sci.*, 81: 872-876.
- Xu, ZZ; McKnight, DJ; Vishwanath, R; Pitt, CJ and Burton, LJ (1998). Estrus detection using radiotelemetry or visual observation and tail painting for dairy cows on pasture. *J. Dairy Sci.*, 81: 2890-2896.