

Short Paper

An experimental study on broiler chicken co-infected with the specimens containing avian influenza (H9 subtype) and infectious bronchitis (4/91 strain) viruses

Seifi, S.¹; Asasi, K.^{2*} and Mohammadi, A.³

¹Graduated from School of Veterinary Medicine, Shiraz University, Shiraz, Iran; ²Department of Clinical Sciences, School of Veterinary Medicine, Shiraz University, Shiraz, Iran; ³Department of Pathobiology, School of Veterinary Medicine, Shiraz University, Shiraz, Iran

*Correspondence: K. Asasi, Department of Clinical Sciences, School of Veterinary Medicine, Shiraz University, Shiraz, Iran. E-mail: asasi@shirazu.ac.ir

(Received 4 Apr 2011; revised version 29 Oct 2011; accepted 30 Nov 2011)

Summary

This experimental study was carried out to induce a co-infection of H9 AIV and IBV with inoculums prepared from tracheal scrubbed epithelium tissues in natural co-infected birds to rule out the effect of field undesired environmental conditions and also other infectious causative agents. Eighty 1-day-old broilers were randomly divided into four equal groups. At 21 days of age, three test groups were inoculated intranasally with prepared inoculums containing IBV and H9 AIV alone and a co-infected group. The fourth group remained uninfected as a control group. The results showed that experimental co-infection of AIV and IBV increased the severity of clinical signs, mortality rate and gross lesions. The HI titer against AIV infection in the co-infected group was significantly higher than the HI titer of other groups, which may indicate that IBV could promote the propagation of H9N2 AIV or stimulate the immune response.

Key words: Avian influenza virus, Infectious bronchitis virus, Co-infection

Introduction

Avian influenza is a contagious disease caused by type A influenza viruses. In spite of the mild nature of H9N2 low pathogenic avian influenza virus, frequent disease outbreaks with high mortality due to the virus have been observed in different parts of the world including Iran (Vasfi Marandi and Bozorgmehrfard, 1999; Nili and Asasi, 2002, 2003; Swayne and Halvorson, 2003). In an earlier study, we closely monitored thirty broiler chicken flocks experiencing severe respiratory symptoms in Fars province, Iran. We recorded a comprehensive history of the flocks including vaccination programs, clinical signs, gross lesions, mortality and viral detection of H9 AIV and IBV. Sixteen flocks out of 30 were positive for H9 AIV genome and four flocks which were co-infected with H9 AIV and IBV (4/91 strain)

experienced severe disease conditions with 20-30% mortality (Seifi *et al.*, 2010). This experimental study was carried out to induce a co-infection of H9 AIV and IBV with inoculums prepared from the natural co-infection to reproduce an infection with exclusion of the effect of undesired environmental factors including; over-crowding, ventilation failure, and excess ammonia, which normally exacerbate the mortality rate, and other infectious agents.

Materials and Methods

Virus

The tracheal samples were randomly taken from 10 chickens of thirty flocks that were in acute phase of respiratory disease in late 2009. Then RT-PCR was performed to detect the H9 protein gene of avian influenza A (Lee *et al.*, 2001). The nested RT-PCR was also performed to detect 4/91 serotype

of IBV in the samples (Table 1) (Adzhar *et al.*, 1997). The vaccine strain IB 4/91 Nobilis (Intervet) and avian influenza virus, A/Chicken/Iran/SH110/99(H9N2), were used in RT-PCR as positive controls, respectively. According to RT-PCR results, tracheal samples of 3 broiler flocks were selected for preparing the inoculums. One of these flocks (with 20% mortality) was positive for AIV (H9 subtype), another flock (with 20% mortality) was positive for IBV (4/91 serotype) and the last flock (with 30% mortality) was co-infected with AIV (H9 subtype) and IBV (4/91 serotype). The inoculums were cultured on solid bacterial culture media for controlling bacteria including *Mycoplasma gallisepticum* and fungal negativity.

Experimental design

Eighty 1-day-old broiler chicks were divided randomly into four groups and each group into two equal subgroups. Prior to challenge all birds were tested by hemagglutination inhibition (HI) test for AI and ELISA test (IDEXX kit, Laboratories, Inc., USA) for IB to show the chicks to be negative to antibodies of avian influenza (H9 subtype) and IB viruses. The birds were inoculated on the 21st day of age with 0.2 ml prepared inoculums intranasally. In the negative control group, sterile PBS was used for inoculation. No vaccine was used in the experiment. Birds were bled on days 0 (pre-inoculation), 10 and 20 PI and the sera were tested for antibodies to H9 subtype of AIV using HI test and antibodies to the IBV using ELISA test (IDEXX kit). The sera were also tested, by HI test, for Newcastle disease virus. At 41-day-old, all survival birds were slaughtered for necropsy after blood sampling.

Statistical analysis

The data of HI and ELISA titers were analysed using one-way ANOVA. Differences among means of the groups were analysed by the Tukey test using SPSS for windows version 13.

Results

RT-PCR findings

As shown in Figs. 1 and 2, amplification

of expected DNA bands from the positive control confirmed that the reaction was performed correctly.

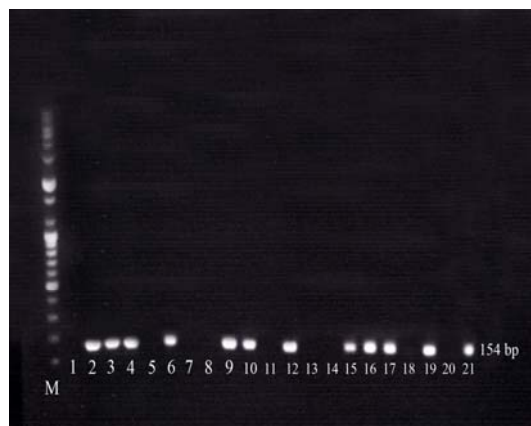


Fig. 1: IBV nested RT-PCR products (154 bp) in 2% agarose. M: DNA marker (100 bp), L21: positive control, L1: blank, L2-4, L6, L9-10, L12, L15-17 and L19: positive samples, L5, L7-8, L11, L13-14, L18 and L20: negative samples

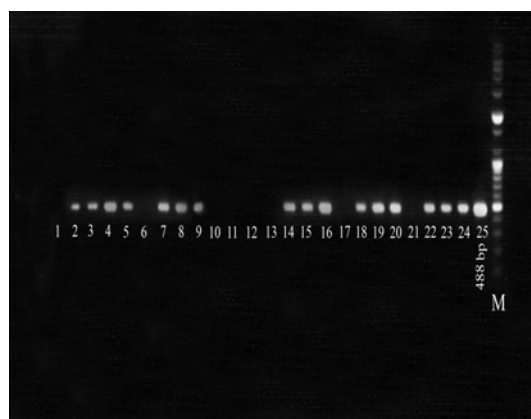

Fig. 2: AIV PCR 488 bp products (H9 protein gene) in 1% agarose. M: DNA marker (100 bp), L25: positive control, L1: blank, L2-5, L7-9, L14-16, L18-20 and L22-24: positive samples, L6, L10-13, L17, and L21: negative samples

Clinical findings

Negative control group

No clinical signs were seen in the control group.

AIV (H9 subtype) and IBV (4/91 serotype) co-infected group

From day two PI, birds co-infected with AIV and IBV started to show clinical signs such as depression, ruffled feathers, respiratory distress (coughing, sneezing and

Table 1: The sequences and positions of the oligonucleotide primers used in RT-PCR

Oligonucleotide	Sequence	Gene	Position in the sequence
Infectious bronchitis			
XCE2-	CTCTATAAACACCCTTACA	S1	1168 to 1193
XCE1+	CACTGGTAATTTTTCAGATGG	S1	728 to 749
XCE3-	CAGATTGCTTACAACCACC	S1	1093 to 1111
BCE1+	AGTAGTTTTGTGTATAAACCA	S1	958 to 978
Avian influenza			
H9 Forward primer	CTYCACACAGARCACAATGG	H9	151 to 171
H9 Reverse primer	GTCACACTTGTGTGTTGTRTC	H9	618 to 638

dyspnea), facial edema, conjunctivitis, lacrimation and nasal discharge which continued to day eight PI. Whitish watery diarrhea was observed in the majority of the chicks and this was noticeable between the 3rd and 7th day PI. There was 20% (4/20) mortality in this group.

AIV (H9 subtype) group

Clinical signs such as depression, ruffled feather, coughing and sneezing, and nasal and ocular discharge appeared on day 3 PI. The most remarkable clinical signs were observed on day 6 PI. One bird (5%) died on day 6 PI. The clinical signs disappeared on day 12 PI.

IBV (4/91 serotype) group

Some chickens of this group showed mild tracheal rales, coughing and gasping on day 2 PI. Whitish watery diarrhea was also observed in the chicks. One bird (5%) died on day 4 PI.

Gross lesion findings

The AIV + IBV co-infected group showed the most lesions. The noticeable lesions were tracheal congestion, lung hyperemia, air sacculitis and swollen kidney. Tubular cast formation in the tracheal bifurcation were observed in all dead birds, however, in the AIV + IBV co-infected group these casts extended to the lower bronchi (Fig. 3). Hemorrhage in pancreas and intestine was observed in dead birds in the AIV + IBV co-infected group and also in the AIV infected group (Fig. 4). In this study, no marked gross changes were observed in dead birds of the IBV infected group except mild petechial hemorrhage and congestion of the tracheal mucosa.

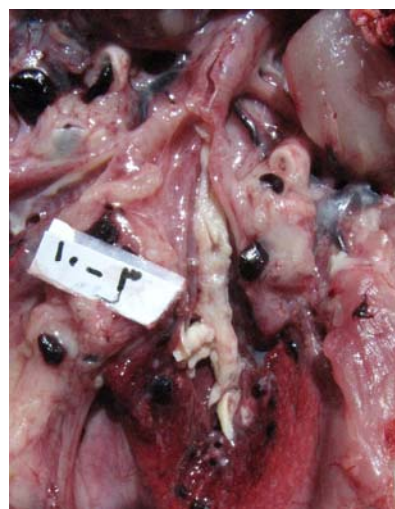

Fig. 3: Tubular cast formation in the bronchial lumen in an AIV and IBV co-infected chicken

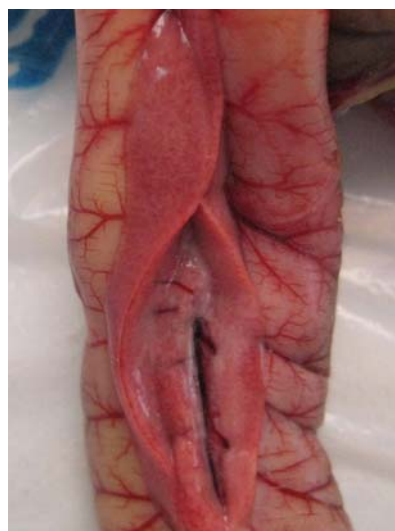

Fig. 4: Hemorrhage in pancreas in a chick inoculated by AIV and IBV

Serological findings

All of the pre-inoculation serum samples obtained from chickens in the test and control groups were negative to AI (HI)

Table 2: Mean±SD values of avian influenza H9 serum antibody titer (HI) and infectious bronchitis ELISA titers in the control and tests groups

Groups	Days PI					
	0		10		20	
	AI	IB	AI	IB	AI	IB
AIV+IBV	2.5 ± 0.5	794 ± 414	4.5 ± 0.5 ^a	2186 ± 956 ^a	9.4 ± 0.7 ^a	3208 ± 1138 ^a
AIV	2.5 ± 0.5	794 ± 414	3.3 ± 0.5 ^b	695 ± 153 ^b	7.7 ± 0.5 ^b	531 ± 138 ^b
IBV	2.5 ± 0.5	794 ± 414	1.9 ± 0.5 ^c	2809 ± 707 ^c	0 ^c	3747 ± 843 ^a
Control	2.5 ± 0.5	794 ± 414	1.5 ± 0.4 ^c	726 ± 92 ^a	0 ^c	517 ± 94 ^b

^{a, b, c} In each columns, means with different superscripts significantly different (P<0.05)

and IB (ELISA). Seroconversion was observed in the test groups on day 10 and 20 PI (Table 2). In the control groups, the sera remained negative at the end of the experiment. All samples were negative in ND-HI test during the experiment.

Discussion

The clinical signs and gross lesions in AIV (H9 subtype) infected chicks were less severe than the lesions reported previously in naturally infected chickens with H9N2 (Nili and Asasi, 2002). In this study, 5% mortality occurred in the experimental group which was infected by H9N2 AIV. Nili and Asasi (2002, 2003) reported that experimental infection of broilers with AIV H9N2 caused severe necrotizing tracheitis and 19% mortality, but it was not shown that the inoculums were free from other pathogens. In this study, the inoculums used for experimental challenge were negative for bacterial and fungal contamination as well as Newcastle disease virus and *Mycoplasma gallisepticum*.

The chicks in the group infected by IBV 4/91 showed 5% mortality. It has been shown that mortality in IBV infection is much lower (<1%), and recovery is faster in outbreaks due to mild strain or those in which bacterial involvement is limited (Cavanagh and Gelb, 2008). The results of the present study also agree with Mahdavi *et al.* (2007) who studied the histopathology and gross lesions induced by serotype 793/B IBV (isolate IR/773/2001) in SPF chicken. Despite the regular vaccination of Iranian broiler chicken with IBV, mostly used Massachusetts strains, IB still causes significant economic losses on the broiler chicken industry in the country. Cross-

protection between different serotypes of IBV is variable; hence, the vaccination failure may be due to low homology (26%) between 4/91 (793/B) strain and mass-type vaccine such as H120 strain (Cavanagh, 2003).

In the present study, clinical respiratory signs such as sneezing, coughing and dyspnea and postmortem lesions including tracheal congestion, lung hyperemia and cast formation in tracheal bifurcation were most severe in the AIV and IBV co-infected group. It seems that asphyxiation was responsible for mortality in dead birds. It has been demonstrated that infectious bronchitis live vaccine, H120 strain, also exacerbates the manifestation of experimental H9N2 AIV infection in broiler chicken (Haghighat Jahromi *et al.*, 2008; Tavakkoli *et al.*, 2011). An epidemiological study of risk factors for generation of bronchial cast in broiler chicken concluded that IB vaccine can be one of the candidate risk factors for enhancing the virulence of low pathogenic H9N2 virus in broiler chicken flocks (Karimi-Madab *et al.*, 2010). Post-translational proteolytic activation of the precursor of HA molecule (HA0) into HA1 and HA2 subunits by host proteases is essential for infectivity and for the spread of the virus. Thus, virus activation by the host proteases plays a vital role in the spread of infection, tissue tropism and pathogenicity of LPAIV (Swayne and Halvorson, 2008). It has been reported that a trypsin-like serin protease domain is encoded by coronavirus IBV (Ng and Liu, 2000). Infectious bronchitis virus co-infection may have provided the protease enzymes and enhanced H9N2 pathogenicity in this experiment.

Avian influenza HI titer in the group co-

infected with AIV and IBV was significantly more than the group infected with AIV alone ($P < 0.05$). This finding may show that IBV could enhance the propagation of AIV, immunostimulation and consequently an increase in AIV HI titer. It has been demonstrated that stimulation of host cells to produce or secrete more protease and the destruction of endogenous cell protease inhibitors may increase trypsin-like protease activity and enhanced influenza virus pathogenicity (Mancini *et al.*, 2005). Our field observation indicates that flocks that are positive to H9N2 have shown increase in mortality in recent years that could be due to increased pathogenicity of the virus or due to other undetected field infections. This study demonstrated that IBV infection increased the pathogenicity of H9N2 AIV in broiler chickens.

Acknowledgements

This research was financially supported by a grant of Shiraz University Research Council. The authors thank Dr. Z. Boroomand and Mr. H. Gerami for their cooperation.

References

- Adzhar, A; Gough, RE; Haydon, D; Shaw, K; Britton, P and Cavanagh, D (1997). Molecular analysis of the 793/B serotype of infectious bronchitis virus in Great Britain. *Avian Pathol.*, 26: 625-640.
- Cavanagh, D (2003). Severe acute respiratory syndrome vaccine development: experiences of vaccination against avian infectious bronchitis coronavirus. *Avian Pathol.*, 32: 567-582.
- Cavanagh, D and Gelb, JJr (2008). Infectious bronchitis. In: Saif, YM; Fadly, AM; Glisson, JR; McDougald, LR; Nolan, LK and Swayne, DE (Eds.), *Diseases of poultry*. (12th Edn.), UK, Blackwell Publishing. PP: 117-135.
- Haghighat Jahromi, M; Asasi, K; Nili, H; Dadras, H and Shooshtari, H (2008). Co-infection of avian influenza virus (H9N2 subtype) with infectious bronchitis live vaccine. *Arch. Virol.*, 153: 651-655.
- Karimi-Madab, M; Ansari-Lari, M; Asasi, K and Nili, H (2010). Risk factors for detection of bronchial casts, most frequently seen in endemic H9N2 avian influenza infection, in poultry flocks in Iran. *Prev. Vet. Med.*, 95: 275-280.
- Lee, MS; Chang, PC; Shien, JH; Cheng, MC and Shieh, HK (2001). Identification and subtyping of avian influenza viruses by reverse transcription-PCR. *J. Virol. Meth.*, 97: 13-22.
- Mahdavi, S; Tavasoly, A; Pourbakhsh, SA and Momayez, R (2007). Experimental histopathologic study of the lesions induced by serotype 793/B (4/91) infectious bronchitis virus. *Arch. Inst. Razi*. 62: 15-22.
- Mancini, DAP; Mendonca, RMZ; Dias, ALF; Mendonca, RZ and Pinto, JR (2005). Co-infection between influenza virus and flagellated bacteria. *Rev. Med. Trop. Sao Paulo*. 47: 275-280.
- Ng, LFP and Liu, DX (2000). Further characterization of the coronavirus infectious bronchitis virus C-like proteinase and determination of a new cleavage site. *Virology*. 272: 27-39.
- Nili, H and Asasi, K (2002). Natural cases and an experimental study of H9N2 avian influenza in commercial broiler chicken in Iran. *Avian Pathol.*, 31: 247-252.
- Nili, H and Asasi, K (2003). Avian influenza (H9N2) outbreak in Iran. *Avian Dis.*, 47: 828-831.
- Siefi, S; Asasi, K and Mohammadi, A (2010). Natural co-infection caused by avian influenza H9 subtype and infectious bronchitis viruses in broiler chicken farms. *Veterinarski Arhiv.*, 80: 269-281.
- Swayne, DE and Halvorson, DA (2003). Influenza. In: Saif, YM; Barnes, HJ; Glisson, JR; Fadly, AM; McDougald, LR and Swayne, DE (Eds.), *Diseases of poultry*. (11th Edn.), USA, Iowa State Press. PP: 135-160.
- Swayne, DE and Halvorson, DA (2008). Influenza. In: Saif, YM; Fadly, AM; Glisson, JR; McDougald, LR; Nolan, LK and Swayne, DE (Eds.), *Diseases of poultry*. (12th Edn.), Ames, IA, Iowa State University Press. PP: 153-184.
- Tavakkoli, H; Asasi, K and Mohammadi, A (2011). Effectiveness of two H9N2 low pathogenic avian influenza conventional inactivated oil emulsion vaccine on H9N2 viral replication and shedding in broiler chickens. *Iranian J. Vet. Res.*, 12: 214-221.
- Vasfi Marandi, M and Bozorgmehrfard, MH (1999). An outbreak of non-highly pathogenic avian influenza in chicken in Iran. *Proceedings of the 61st meeting of the World Veterinary Association (CD-ROM)*. France.